



Zingiber officinale and *Piper nigrum* Consumption as Aphrodisiacs on Viscerals and Testis of Male Wistar Rats

Wilson Ogbonna Ajanwachuku¹, Peter Uwadiogwu Achukwu², Nosa Terry Omorodion^{2*}, Godfrey Innocent Iyare¹ and F E Otabor²

¹Department of Medical Laboratory Sciences, University of Nigeria, Nigeria

²Department of Health Services, University of Benin, Nigeria

Abstract

The use of these substances otherwise known as aphrodisiacs with capacities to arouse or increase sexual drive or libido and the increasing incidence of male sexual dysfunction is necessitating more and rapid search into plants with aphrodisiac potentials. Unfortunately, effort in resolving issues about infertility via the consumption of several plant products without recourse to the effects of such substance abuse on the cytoarchitectural and function of vital organs in the body like testis, liver, kidneys and the brain.

The aim of this study is to determine the effect of the consumption of aqueous extract of black pepper and ginger as aphrodisiacs on the liver, kidneys and testis of male wistar rats.

In all, Thirty-six adult Wistar rats were used for this study. They were divided into four equal groups of nine rats each. Group A served as the control and the rats were given distilled water. Group B was fed with blackpepper extract, Group C was fed with ginger extract and D rats were fed with aqueous extract of both blackpepper and ginger. The substance administration was given daily for 42 days (6 weeks) and the weights of both the test animal and control monitored every 2 week. After the administration, the rats were put under light chloroform anaesthesia and the kidney, liver and testis harvested for histological processing.

The histological observations indicated that black pepper, ginger and the combination of both substance at 2 weeks, four weeks and 6 weeks resulted in varying degree of damages to the liver, kidney and testis of the experimental animals. In view of the above observations, it is clear in this study that the dose administered and at every duration used, there are considerable histological damages to these organs. It could therefore be deduced that the repeated consumption of blackpepper and ginger by the experimental animals lead to severe toxicological implication on the kidneys, liver and testis tissue but the extent of damages varies with duration. Based on the histological observation presented in this study, it is recommended that Specific research should be carried out to ascertain its actual dose safe for human consumption. The use of blackpepper and ginger as aphrodisiac and for culinary use should be regulated as prolonged consumption may be harmful to vital body organs.

Keywords: *Zingiber officinale*; *Piper nigrum*; Wistar rat

Introduction

It has been estimated that up to 90% of the population in developing countries rely on the use of medicinal plants to help meet their primary healthcare needs [1]. Currently traditional medicine is the only healthcare resource accessible to a third of all Nigerians [2] and in the treatment of several healthcare conditions including mental disorder, fractures, insomnia and infertility. According to [3,4], infertility is the inability of a couple to have a pregnancy, after regular sexual intercourse (3 to 4 times per week) without contraceptive method, during one year. In males, reduced fertility can be as a result of congenital and acquired urogenital abnormalities and immunological factors [5].

On the other hand, impotency, premature ejaculation and generally male infertility in the past two decades have been the focus of most research works [6]. A large proportion of infertile men fail to impregnate their female counterpart because of lack of sperm (azoospermia) or too little sperm (oligospermia), abnormal sperm morphology (teratozoospermia) and abnormalities in sperm motility (asthenozoospermia) [7]. In many countries, the stigma of infertility often leads to marital disharmony, divorce or ostracism [8] and over the last 50years, sperm counts have been declining

OPEN ACCESS

*Correspondence:

Nosa Terry Omorodion, Department of Health Services, University of Benin, Benin city, Edo State, Nigeria;
E-mail: terry.omorodion@uniben.edu

Received Date: 23 Apr 2018

Accepted Date: 18 May 2018

Published Date: 27 May 2018

Citation:

Ajanwachuku WO, Achukwu PU, Omorodion NT, Iyare GI, Otabor FE. *Zingiber officinale* and *Piper nigrum* Consumption as Aphrodisiacs on Viscerals and Testis of Male Wistar Rats. *Ann Digest Liver Dis.* 2018; 1(2): 1008.

Copyright © 2018 Nosa Terry Omorodion. This is an open access article distributed under the Creative Commons Attribution License, which permits unrestricted use, distribution, and reproduction in any medium, provided the original work is properly cited.

Table 1: Physical observation of experimental rats used for acute toxicity test of *Zingiber officinale*.

	Dosage(mg/kg)	Observation	Remark	Mortality
Phase I				
Group 1	100	weakness	negative	0/4
Group 2	300	fur/skin color change	negative	0/4
Group 3	500	diarrhea	positive	1/4
Phase II				
Group 1	200	weakness	negative	0/4
Group 2	400	fur/skin color change	positive	1/4
Group 3	600	diarrhea	positive	1/4

with a consequent increase in male infertility [9].

Generally, reproductive healthcare has become the second most prevalent health care problem on African continent [10] and of interest, is the use of herbal remedies in the management of infertility. Such remedies that are readily available in Nigeria ranges from those that promote sperm production and motility, to formulations for increasing testosterone levels enhancing normal functioning of the male reproductive organs, and strengthening erection/sex drive [11]. However, large amounts of these herbs may lead to toxic overload that may involve complications. Some of a serious nature and should be used with caution [12]; hence the growing concerns.

The aim of this study is to assess the histological effect of *Zingiber officinale* and *Piper nigrum* consumption as aphrodisiacs on the liver and kidney.

Materials and Methods

Research design

Thirty-six (36) adult Wistar rats aged 2-4 months were used for this study. They were procure from the animal house of Anthonio Research Centre, Ekpoma and after acclimatization were divided into four equal groups of nine rats each. Group A served as the control and the rats were given distilled water. Group B was fed with *Piper nigrum* aqueous extract, Group C was fed with *Zingiber officinale* aqueous extract and D rats were fed with aqueous extract of both *Piper nigrum* and *Zingiber officinale*. Adequate amount of fresh fruits of *Piper nigrum* and dried tuber *Zingiber officinale* was procure from the Royal Market, Ekpoma in Edo State and authenticated by a botanist in the Department of Botany Ambrose Alli University, Ekpoma, Edo State.

The substance administration was given daily for 42 days (6 weeks) and the weights of both the test animal and control monitored every 2 week starting from. After the administration, the rats were euthanized under light chloroform anaesthesia and the kidney, liver and testis harvested. They were observed macroscopically and processed for light microscopy. Analysis of Variance (ANOVA) was used to analyze the results of the weight and differences were considered significant at $P < 0.05$ level of confidence. All data were expressed as Mean \pm Standard error of mean (SEM). The results were presented in tables and comparisons made statistically.

Geographical description of the study area

This study was carried out in the experimental site of Anthonio research centre located at no 40 Ujoelen extension, Ekpoma and the University of Benin Teaching Hospital, Benin City, both in Edo state. Edo state lies between longitude 06° 04'E and 06° 43'E and latitude 05° 44'N and 07° 34'N with a land mass of 17, 450 sq.km located in

Table 2: Notable physical observations of rats administered *Piper nigrum*/*Zingiber officinale*.

Observations	Control Group A	Test groups		
		B (Pn)	C (Zo)	D (Pn/Zo)
fur colour	-	+	+	+
Behavioural changes	-	-	-	-
skin surfaces	-	-	-	-
Diarrhoea	-	-	-	-

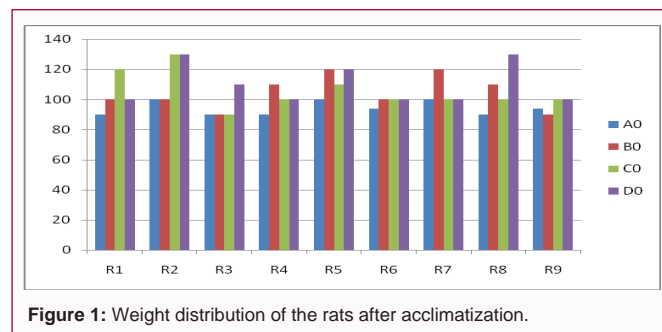


Figure 1: Weight distribution of the rats after acclimatization.

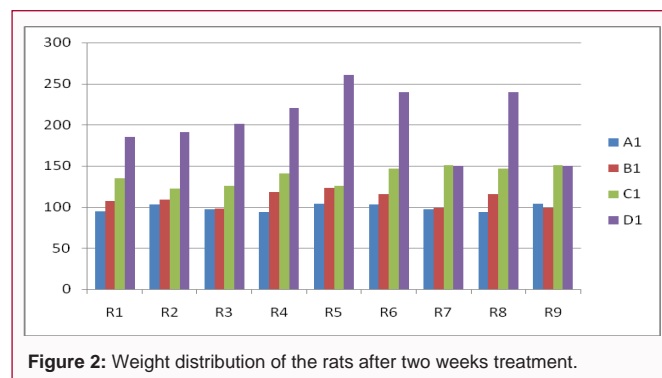


Figure 2: Weight distribution of the rats after two weeks treatment.

the South South geopolitical zone of Nigeria with a population of 3.1 million people.

Ginger: Fresh ginger rhizomes were bought from Ekpoma Royal market. They were washed using distilled water, dried in an oven and grinded using laboratory blender. 200 mg of the grinded *Zingiber officinale* rhizomes was dissolved in 10 ml of distilled water and administered to the animals. 0.72 ml (which contains 5.6 mg/100 g) was administered to rats in group C and D. T.

Blackpepper: Eighty grams (80 g) of Sun dried fruit were obtained ground and soaked in 1L of DH₂O for 24 hour with mixture shaken at interval of 8 hours at room temperature. This was filtered severally using cotton wool to remove large particles, the resultant solution coloured light brown was poured into a container and refrigerated. 0.62 ml of extract (which added up to 50 mg/100 g respectively were given daily to animals in group B and D respectively using nasogastric tubes. This was done according to [13].

Acute Toxicity (Ld₅₀) Test of Black pepper (*Piper nigrum*) and Ginger (*Zingiber officinale*)

The method of [14] was used for the acute toxicity test of the *Piper nigrum* and *Zingiber officinale*. Twenty-four adult wistar rats were utilized in each of these studies. These tests were done in two stages. In stage one, the animals were grouped into three (3) groups of six

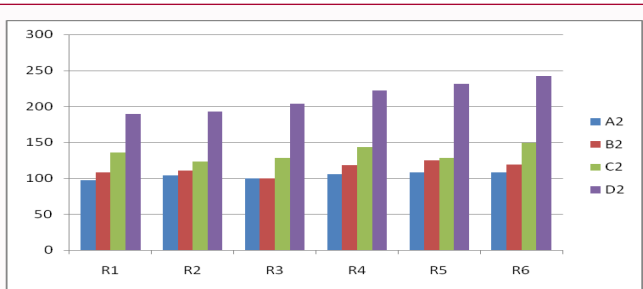


Figure 3: Weight distribution of the rats after four weeks treatment.

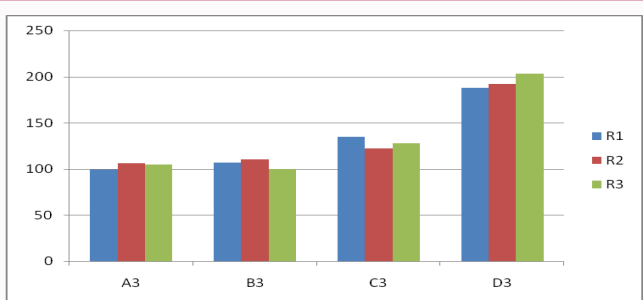


Figure 4: Distribution of the rats after six weeks treatment.

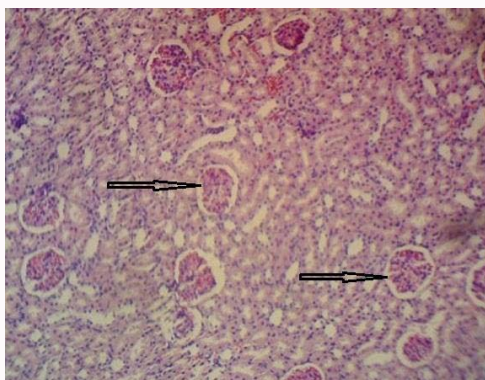


Plate 1: Photomicrograph of control kidney tissue section (H&E: X400) showing normal cytoarchitectural features with intact glomeruli.

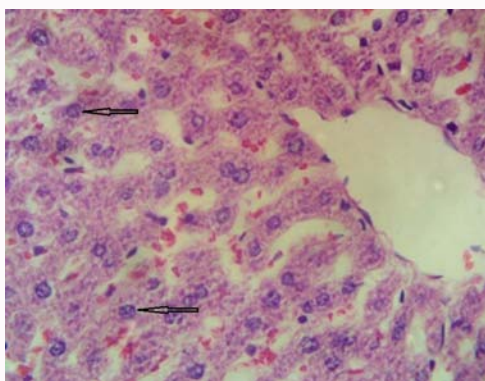


Plate 2: Photomicrograph of control liver tissue section (H&E: X400) showing normal cytoarchitectural features with intact central vein.

(6) rats each and were given *Piper nigrum* in single doses of 10 mg/kg, 100 mg/kg and 1000 mg/kg body weight of extract respectively orally and *Zingiber officinale* was given in single doses of 100 mg/kg, 300 mg/kg and 500 mg/kg body weight of extract respectively orally.

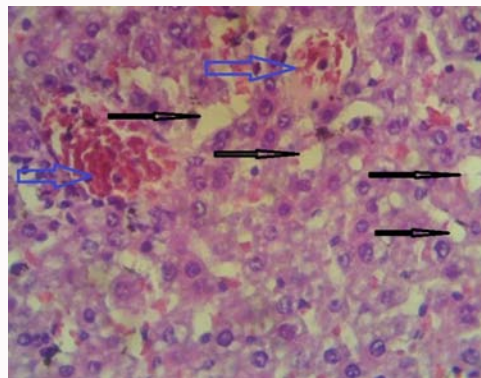


Plate 3: Photomicrograph of liver tissue section (H&E: X400) of rats fed with black pepper for 2 weeks showing vacuolation (black arrow) and vascular congestion (blue arrow).

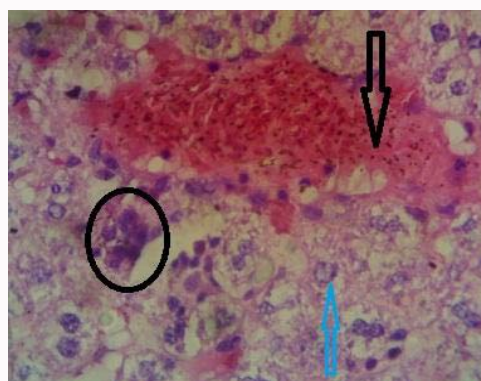


Plate 4: Photomicrograph of liver tissue section (H&E: X400) of rats fed with black pepper for 6 weeks showing severe vascular congestion (black arrow), nuclear vacuolation (blue arrow) and basophilic cells (circle).

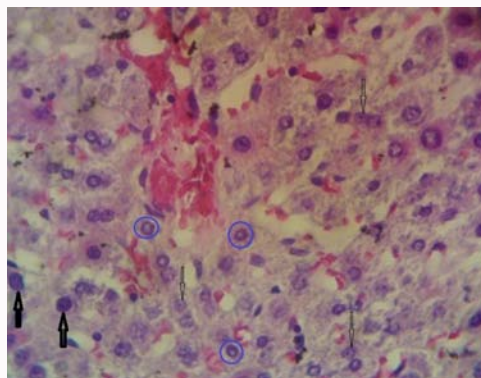


Plate 5: Photomicrograph of liver tissue section (H&E: X400) of rats fed with ginger for 2 weeks showing nuclear vacuolation.

In the second stage, *Piper nigrum* was administered in single doses of 1600mg/kg, 2900 mg/kg and 5000 mg/kg body weight of the extract were administered to the animals which had been grouped as in stage one. Also, *Zingiber officinale* was given in single doses of 200 mg/kg, 400 mg/kg and 600 mg/kg body weight of extract respectively. The administration of *Piper nigrum* and *Zingiber officinale* the extract was done orally.

Experimental Animals/Housing Condition

Thirty-six (36) Adult Wistar rats of comparable sizes and weights ranging from 90 g to 130 g (aged 2 months) were procured from

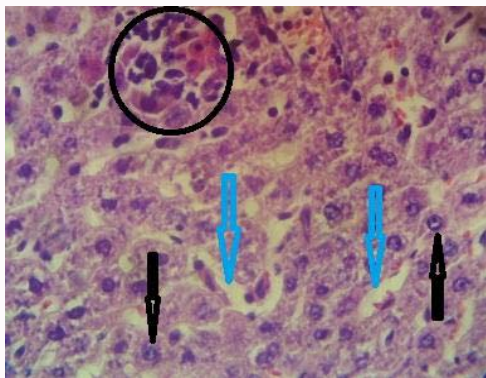


Plate 6: Photomicrograph of liver tissue section (H&E: X400) of rats fed with ginger for 4 weeks showing vacuolation (blue arrow), cellular infiltration and nuclear vacuolation (black arrow).

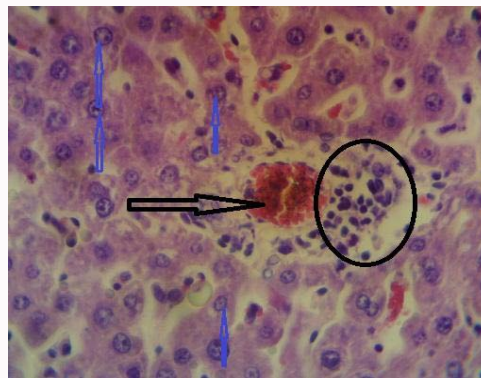


Plate 9: Photomicrograph of liver tissue section (H&E: X400) of rats fed with black pepper and ginger for 4 weeks showing pyknosis (blue arrow), haemorrhagic congestion (black arrow) and cellular infiltration (circle).

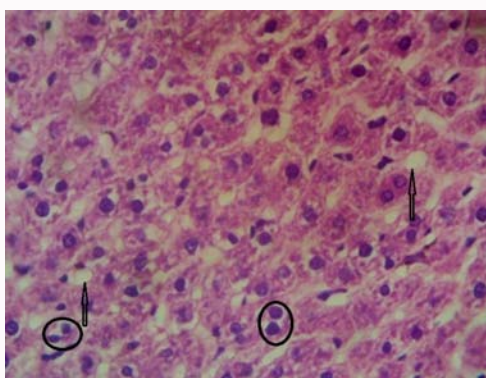


Plate 7: Photomicrograph of liver tissue section (H&E: X400) of rats fed with ginger for 6 weeks showing vacuolation (black arrow) and basophilic cells (circle).

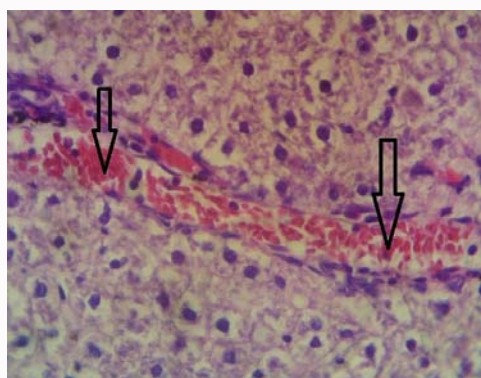


Plate 10: Photomicrograph of liver tissue section (H&E: X400) of rats fed with black pepper and ginger for 6 weeks showing arterial congestion (black arrow).

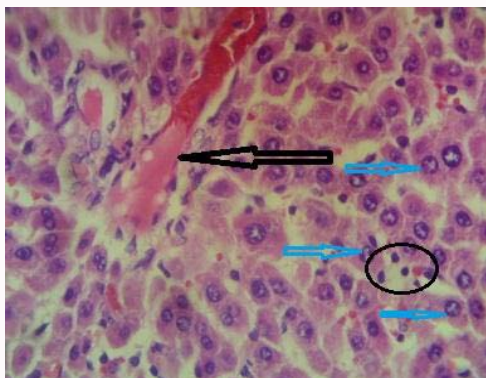


Plate 8: Photomicrograph of liver tissue section (H&E: X400) of rats fed with black pepper and ginger for 2 weeks showing nuclear vacuolation (blue arrow), haemorrhagic congestion (black arrow) and cellular infiltration (circle).

the animal farm, Anthonio services Nigeria, Ekpoma, Edo State and transferred to the experimental Laboratory Anthonio Research Center at No. 40 Ujoelen Extension, Ekpoma, where they were allowed two (2) weeks of acclimatization. They were kept in wire mesh cages with tripod that separates the animal from its faeces to prevent contamination. During this period of acclimatization, the rats were fed with growers' mash and water provided ad libitum. The animals were maintained and utilized in accordance with the standard guide for the care and use of Laboratory animals.

Study Duration

The preliminary studies, animal acclimatization, ingredients procurement (*Piper nigrum* and *Zingiber officinale* preparation and production), acute toxicity test, actual animal experiment and evaluation of results, lasted for a period of five months. However, the actual administration of *Piper nigrum* and *Zingiber officinale* to the test animals lasted for 7 weeks.

Sample Collection and Analysis

Weights of experimental animals were measured before and after acclimatization and similar weight measurements were done at the end of each week and the average weight recorded accordingly. The kidney, liver and testes of each rat were harvested at the end of 2, 4 and 6 weeks under chloroform anaesthesia and fixed in 10% formalin for histological processing. The growth performance and feed utilization of the rats were determined at the end of the experiment as described by [15].

Histological Processing

The tissues were processed using automatic tissue processor according to the processing schedule used in University of Benin Teaching Hospital (UBTH), Edo State, Nigeria. The fixed plastic cassette tissues in 10% formalin were automatically processed by passing them through different grades of alcohol as follows:

After the last timing, the tissues were removed from their plastic

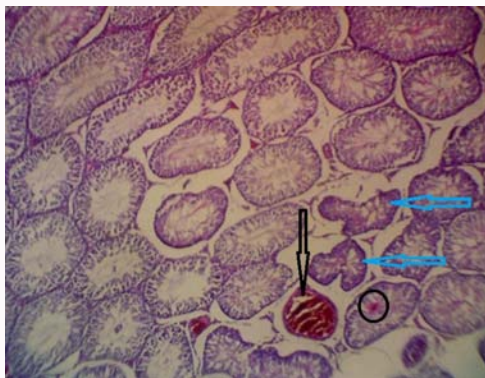

Plate 11: Photomicrograph of testis tissue section (H&E: X400) of rats fed with black pepper for 6 weeks showing haemorrhagic congestion (black arrow) and seminiferous tubule shrinkage (blue arrow).

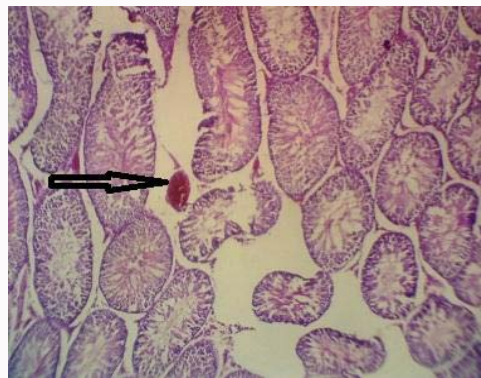


Plate 14: Photomicrograph of testis tissue section (H&E: X400) of rats fed with ginger for 6 weeks showing haemorrhagic congestion (black arrow).

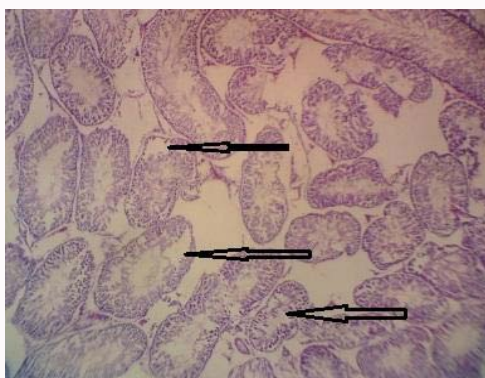


Plate 12: Photomicrograph of testis tissue section (H&E: X400) of rats fed with ginger for 2 weeks showing sperm cell degeneration (black arrow).

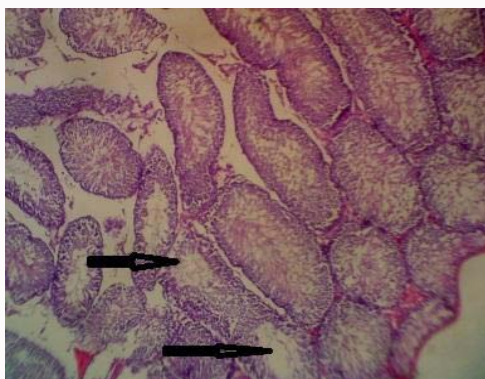


Plate 13: Photomicrograph of testis tissue section (H&E: X400) of rats fed with ginger for 6 weeks showing sperm cell degeneration (black arrow).

cassettes and placed at the centre of the metallic tissue mould and then filled with molten paraffin wax. They were also left to solidify after which they were now placed in the refrigerator at 5°C for 15 minutes. After the blocks were cool in the refrigerator for the time stated above (15 minutes), the blocks were then removed from the metallic case using a knife and after which the paraffin wax at the side of the blocks were removed.

The blocks were then trimmed and cut serially at 5µ using a rotary microtome. The sections were floated in water bath at 55°C and picked up by the use of a clean frosted end slides. The frosted end slides were now placed on the hot plate for 40 minutes for adequate

attachment of the sections on the slides after which the sections were de-waxed, hydrated, air dried and stored in a slide box ready for staining process.

Staining Procedure

Haematoxylin and Eosin attaining technique was used.

Data analysis

The obtained data were then subjected to statistical analysis using SPSS (version 17). The test groups' values were compared with the values of the control group using ANOVA (Scheffe) at 95% level of confidence.

Result

Result of acute toxicity test of Black pepper (*Piper nigrum*) and ginger (*Zingiber officinale*).

Physical observation of experimental rats used for acute toxicity test of *Piper nigrum*. Physical observation of the experimental rats used for the LD₅₀ showed that there was no weakness, no diarrhea, no changes in skin surfaces, no changes in fur colour and no death in the test animals administered with single doses of aqueous extract of *Piper nigrum* in phase I and II. This suggests that there was no apparent sign of toxicity in the test animal at a single dose of up to 5000 mg/kg.

Physical observation of experimental rats used for acute toxicity test of *Zingiber officinale*.

Physical observation of the experimental rats used for the LD₅₀ showed that there was no weakness all doses administered with *Zingiber officinale* and there was no skin or fur color changes in rats administered 300 mg/kg aqueous extract of *Zingiber officinale*. However, there was fur and skin color change in rats administered 400 mg/kg (phase II), there was notable watery stool (diarrhea) in rats administered 500 mg/kg (phase I) and 600mg/kg (phase II). Death of experimental animals were recorded in Group 3 (phase I) administered 500 mg/kg, Group 2 (phase II) administered 400 mg/kg and Group 3(phase II) administered 600 mg/kg. Deaths recorded in this group were 1 out of 4.

Sampled Weight Distribution

Weight changes were observed in the course of the experiment. The variations in weight were monitored after acclimatization and after 2 weeks, 4 weeks and 6 weeks treatment with the substance of study. The changes in weight are shown in Table 1,2.

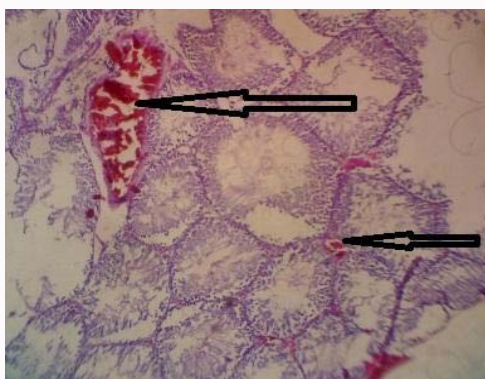


Plate 15: Photomicrograph of testis tissue section (H&E: X400) of rats fed with black pepper and ginger for 2 weeks showing haemorrhagic congestion (black arrow).

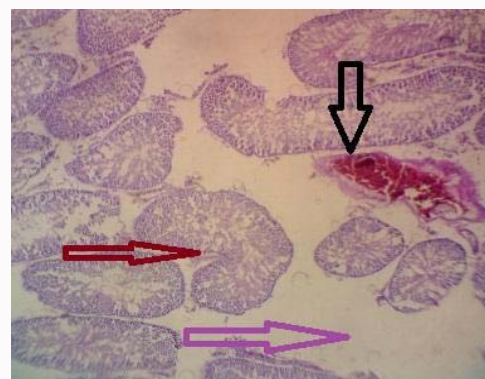

Plate 17: Photomicrograph of testis tissue section (H&E: X400) of rats fed with black pepper and ginger for 6 weeks showing haemorrhagic congestion (black arrow), seminiferous tubule distortion (red arrow) and seminiferous tubule degeneration (purple arrow).

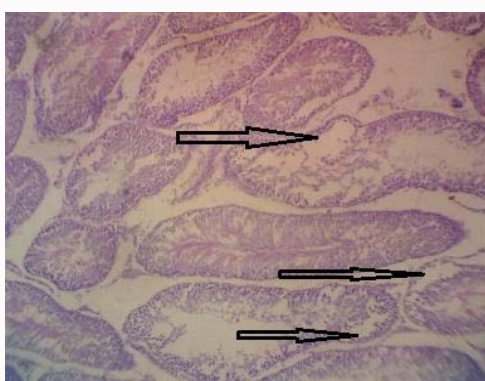


Plate 16: Photomicrograph of testis tissue section (H&E: X400) of rats fed with black pepper and ginger for 4 weeks showing sperm cell degeneration (black arrow).

Histological Observations

The histological observations indicated that black pepper administration for a duration of two (2) weeks resulted in glomerular degeneration and mild vacuolar congestion as seen in the kidney cytoarchitecture in the treated group fed with 0.62 ml (which added up to 25 mg/100 g) of blackpepper. These changes are at variance with that of the control group A. The micrograph of the kidney sections in control group A, showed normal histological cytoarchitecture with well define glomeruli. However, at 4 weeks of black pepper administration, cellular infiltration and severe lobulated and distorted glomeruli were observed in rat fed 0.62 ml. At 6 weeks of blackpepper administration, there were severe glomerular shrinkages.

In group 3 fed with ginger, significant changes such as glomerular shrinkages and vascular congestion were observed in kidney sections after 2 weeks of ginger extract administration. At 4 weeks of administration, significant changes such as severe vacuolation, glomerular degeneration and vascular congestion were observed in kidney sections. Severe significant changes such as glomerular shrinkages, Mild haemorrhagic congestion and moderately lobulated glomeruli were seen in kidney sections of rats fed with ginger after 6 weeks of administration.

Group 4 administered with combine aqueous extract of blackpepper and ginger reveals significant histopatological changes such as vacuolation and lobulated glomeruli after 2 weeks. At the duration of 4 weeks, there were severe significant histological

changes such as lobulated glomeruli, cellular infiltration, glomerular shrinkages and vascular congestion. Significant changes such as glomerular shrinkage, vascular congestion and lobulated glomeruli were observed after 6 weeks of combine administration of blackpepper and ginger.

The histochemistry of the liver sections showed that the control liver section present normal cytoarchitecture with intact central vein and well defined hepatocytes. However, in group 2 administered with blackpepper there were mild changes such as mild vacuolation and vascular congestion. Signicant histological changes were such as haemorrhagic congestion and vacuolation were observed in liver sections after 4 weeks of blackpepper administration. Moreover, at the end of 6 weeks, liver section presented nuclear vacuolation, haemorrhagic congestion and basophilic cells.

In group 3 fed with ginger, severe nuclear vacuolations were seen in the liver sections after 2 weeks of ginger extract administration. At the end of 4 weeks of ginger administration, nuclear vacuolation was observed. Hepatic tissue vacuolation and cellular infiltration was also observed. Vascular congestion, pyknosis, vacuolation and basophilic cells were observed in liver sections after 6 weeks of ginger extract administration.

In group 4 administered with the combination of aqueous extracts of black pepper and ginger, there were significant changes such as nuclear vacuolation, haemorrhagic congestion and basophilic cells were observed at 2 weeks of administration. After 4 weeks of administration, there were induced piknosis and the presence of basophilic cells. A Signicant histopathological change such as arterial congestion was noticed at the end of 6 weeks of administration of ginger.

The histological findings of in the testis tissue sections showed that the control testis present normal cytoarchitecture with intact seminiferous tubules and well defined interstitial spaces. In group 2 administer with blackpepper, significant pathological change such as sperm cell degeneration was observed after 2 weeks of administration. Haemorrhagic congestion and sperm cell degeneration was observed in testis of rats administered with blackpepper after 4 weeks. At the end of six weeks significant changes such as haemorrhagic congestion and seminiferous tubule shrinkage were observed in the testis after 6 weeks.

In group 3 fed with ginger, the histological findings revealed

that there was sperm cell degeneration after 2 weeks. At the end of 4 weeks, haemorrhagic congestion and sperm cell degeneration was observed in tissue sections. Moreover, sperm cell degeneration was observed at the end of 6 weeks. Haemorrhagic congestion was also observed at the end of 6 weeks.

In group 4 administered with aqueous extract of blackpepper and ginger, haemorrhagic congestion was observed after 2 weeks of administration. At the end of 4 weeks, there was sperm cell degeneration. Haemorrhagic congestion and seminiferous tubule degeneration were observed at the end of 6 weeks of administration. All these observations are shown in the Figure 1-3 and Plate 1-17.

Discussion

The acute toxicity test of *Piper nigrum* aqueous extract showed that the plant was not toxic to the rats up to 5000 mg/kg body weight of the extract, an indication that *Piper nigrum* could be safe for human consumption. The report in this study is in accordance with that of [16,17]. Taubes, [18] also reported that *Piper nigrum* was devoid of toxicity up to 2000 mg/kg in experimental mice. The acute toxicity test of Ginger (*Z. officinale*) showed apparent sign of toxicity in doses of 400 mg/kg, 500mg/kg and 600 mg/kg. These are indications that consumption of relatively high dose of the tuber extract could be toxic to human. Death recorded in the acute toxicity test showed that the LD₅₀ of *Zingiber officinale* extract may be around 600 mg/kg in experimental mice [19]. Conducted a toxicity on *Zingiber officinale* were it was reported that the LD₅₀ is 6.45 mg/kg.

The pathologic changes observed in this study could be attributed to the chemicals substances contain in the extract. In fact, it has been documented that black pepper (*Piper nigrum*) contains several amine alkaloids, sterols and lignans. Lignans are phenolic compounds found mainly in plants and are believed to protect humans from tumors and viruses. They however also produce side effect such as irritation, scarring and tissue necrosis thus may be responsible for the observed lobulated glomeruli, vascular congestion, cellular infiltration, glomerular shrinkages, nuclear vacuolation, tissue vacuolation, sperm cell degeneration, seminiferous tubule degeneration and interstitial haemorrhage as seen in sections of kidney, liver and testis respectively.

The main pharmacological actions of ginger and compounds isolated from plant extract include immunomodulatory, anti-tumorigenic, anti-inflammatory, anti-apoptotic, anti-hyperglycemic, antilipidemic and anti-emetic actions. Ginger is a strong anti-oxidant substance and may either mitigate or prevent generation of free radicals. It is considered a safe herbal medicine with only few and insignificant adverse/side effects which could become significant when used in high dose or longer period of time [20].

Although, the focus of this study was not on the effect on weight but on the histological changes, weight variations were monitored considering its significance and thus, reemphasizes the opinion that increased concentration of active compounds in plants extracts are not always beneficial and can even promote adverse biological effects [21].

Conclusion

In conclusion, it could be inferred from the result that black pepper and ginger administration can causes cytoarchitectural distortions as evident in the kidneys, liver and testes sections. In view of the above observations, it is clear in this study that the dose administered and

at every duration used, there are considerable histological damages to these organs. It could therefore be deduced that the repeated consumption of blackpepper and ginger by the experimental animals lead to severe toxicological implication on the kidneys, liver and testis tissue but the extent of damages varies with duration.

Recommendation

Based on the histological observation presented in this study, it is recommended that;

1. Specific research should be carried out to ascertain its actual dose safe for human consumption.
2. The use of black pepper and ginger as aphrodisiac and for culinary use should be regulated as prolonged consumption may be harmful to vital body organs.

References

1. WHO (2002).Traditional medicine growing needs and potentials, WHO Policy Perspective on Medicine. 2002;2:1-6.
2. Ogunbodede, A.J. Mental illness and traditional therapy in Nigeria, Ibm Journal Of Social. 1997.
3. Salgado, J.T.R, Hernandez, M. and Ayala, A. Frequency of altered male factor in infertility clinic, Gyneacology and Obstetrics. 2003;71:233-7.
4. Ojobo, S.(2007). Management of Infertility amongst Nigerian Couples, The way forward. Women's Health and Action Research Centre.Community Education Lecture Series WHARC, Benin City, Nigeria, 26.
5. WHO. WHO Manual for the standardised investigation and diagnosis of the infertile male Published by Cambridge University Press. 2000;102.
6. Kulkani S.K, Reddy, D.S. Pharmacotherapy of Male Erectile Dysfunction with Sildenafil, Indian Journal of Pharmacology. 1998;30(6):367-8.
7. Feng, H.L. Molecular biology of male infertility. Archive of Andrology. 2003;49(3):19-27.
8. WHO (1993).Binnial Report, Prevention of Infertility from 1992–1993 Edt, J. Khanna, Office of Publication, WHO, Geneva,32 – 33,161-166.
9. Carlsen, E., Giwercman, A.J., Keiding, N. and Skakkebaek, N.E. (1993) Decline in semen quality from 1930 to 1991, UgeskrLaeger, 155,2230-2235.
10. Chinnoch, P. (1996): Reproductive Health. African Health.18:3-19.
11. Afolayan , M. T. Yakubu, J. R. Appidi and M. Mostafa. Toxicological implications of aqueous extract of Clematis brachiataThunb. leaves in male Wistar rats African Journal of Pharmacy and Pharmacology. 2009;3(11):531-538.
12. Faleyimu OI, Oso AO. Medicinal utilization of herbs for the treatment of erectile dysfunction in Lere local government area of Kaduna State, Nigeria. Asian J Nat App Sci. 2012;1(2):15–25.
13. Ebeye O.A, Emore E, Enaibe B.U, Igbigbi P.S. Hispathological Effect of Piper guineense Extract on Wistar Rats. Journal of Biological Sciences. 2007;7(8):1484-1487.
14. Lorke, D. Determination of Acute Toxicity. Archive of Toxicology. 53:275-279.
15. Dada, A.A, Ikuero, M. Effects of ethanolic extracts of Garcinia kola seeds on growth and haematology of Catfish (*Clariasgariepinus*) brood stock. African Journal Agriculture Research. 2009;4(4):344-47.
16. Aqil, F., Ahmed I, Mehmood, Z. Antioxidant and free radical scavenging properties of twelve traditionally used Indian medicinal plants. Turkish Journals of Biology. 2006;30:177-183.
17. Szkudelski, T. The mechanisms of alloxan and streptozotocin action in β -cell of the rat pancreas .Physiology Research. 2001;50(6): 537-546.

18. Taubes, G. Diabetes: Paradoxical effects of highly controlled blood sugar. *Science*. 2008;322 (5900): 365-367.
19. Iman, A.E, Ibrahim, A.A . A study of cardiovascular toxic effect of Zingiber officinale in adult male albino rats and its mechanism of action. *Mansura Journal of forensic Medicine and Clinical Toxicology*. 2009;17 (2):109-136.
20. Ali, B.H., Blunden, G., Tanira, M.O., Nemmar, A. Some phytochemical, pharmacological and toxicological properties of ginger (*Zingiber officinale* Roscoe): a review of recent research. *Food Chem Toxicol*. 2008;46(2):409-420.
21. Patel, K., Srinivasan, K. Studies on the influence of dietary spices on food transit time in experimental rats. *Nutritional Research*. 2001;21:1309-1314.