



Very Rare Cause of Colonic Melanosis Apart from Taking Anthraquinone Laxatives

Boulajaad S^{1*}, Michouar M¹, Ait Errami¹, Oubaha S², Samlani Z¹ and Krati K¹

¹Department of Hepato-Gastro-Enterology, CHU Mohammed VI Marrakech, Morocco

²Department of Medicine, University Cadi Marrakech, Morocco

Abstract

Colonic melanosis is a pigmentation disorder of the colonic mucosa, shown by colonoscopy. Confirmation is provided by the anatomo-pathological study of colonic biopsies. This is a rare pathology which most often results from excessive and prolonged use of anthraquinone laxatives during constipation and which resolves within a few months after stopping the laxatives. But other rare etiologies are found such as the use of diacerein antiarthrosics which is the subject of our observation.

In this regard, we present the case of a 58-year-old woman presenting with chronic abdominal pain revealing colonic melanosis following prolonged use of antiarthrosis medication: diacerein, with no notion of chronic use of laxatives.

Keywords: Melanosis; Colon; Laxatives; Anthraquinone; Diacerein

Introduction

Colonic melanosis or colonic necrosis is a rare, benign pathology characterized by brown and black pigmentation of the colonic mucosa, due to the accumulation of macrophages loaded with a brownish pigment corresponding to lipofuscins.

The main cause is the excessive and prolonged use of anthraquinone stimulant laxatives, however other rarer causes have been described, in particular the use of antiarthrosis drugs of the diacerein type.

Colonic melanosis is mainly diagnosed by colonoscopy objectifying a brownish colonic mucosa with pigment deposits, and confirmed by histological examination which shows the presence of clusters of pigmented cells, located in the middle or deep part of the chorion of the colonic mucosa.

The evolution is most often benign with regression of the lesions after discontinuation of the treatment in question.

Case Presentation

We report the observation of a 58-year-old patient with bilateral knee osteoarthritis under Diacerein Art¹, migraine under analgesic treatment (Ibuprofen Nurodol¹, Paracetamol-Codeine Migralgine¹ and Amitriptyne Laroxyl¹), hyperthyroidism under carbimazole Dimazol¹ and polycystic kidney disease. The patient presented with chronic abdominal pain that was not relieved by the usual analgesics.

The physical examination was without abnormality. An abdominal CT scan was performed without showing any abnormality. Laboratory workup with CBC, CRP, fecal calprotectin, kidney function, and workup for deficiency syndrome did not reveal any notable abnormalities.

A colonoscopy carried out by progressing to the low cecal fundus, revealed a dark pigmentation of the mucous membrane of the colon "leopard skin", mainly at the level of the right and transverse colon with the presence of several superficial ulcers, with a left colonic mucosa of normal appearance suggesting colonic melanosis (Figure 1, 2).

The anatomo-pathological study of colonic biopsies confirmed the presence of a fibrous chorion, the site of a diffuse inflammatory infiltrate, made up of lymphocytes, plasma cells, polynuclear neutrophils and histiocytes loaded with brownish pigments (Figure 3).

OPEN ACCESS

*Correspondence:

Boulajaad S, Department of Hepato-Gastro-Enterology, CHU Mohammed VI Marrakech, Morocco,
E-mail: boulajaad.sara@gmail.com

Received Date: 21 Jun 2021

Accepted Date: 06 Jul 2021

Published Date: 09 Jul 2021

Citation:

Boulajaad S, Michouar M, Errami A, Oubaha S, Samlani Z, Krati K. Very Rare Cause of Colonic Melanosis Apart from Taking Anthraquinone Laxatives. *Ann Curr Gastroenterol Rep.* 2021; 1(1): 1004.

Copyright © 2021 Boulajaad S. This is an open access article distributed under the Creative Commons Attribution License, which permits unrestricted use, distribution, and reproduction in any medium, provided the original work is properly cited.

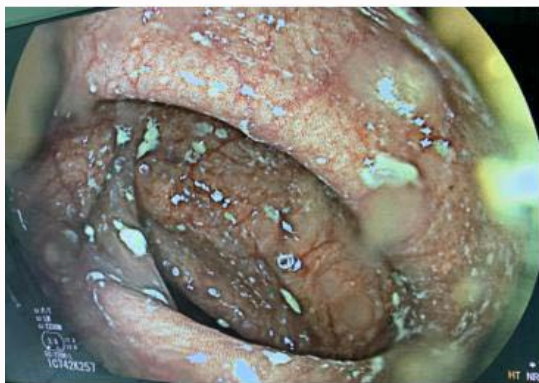

Figure 1: Dark brown appearance of colonic mucosa on colonoscopy.

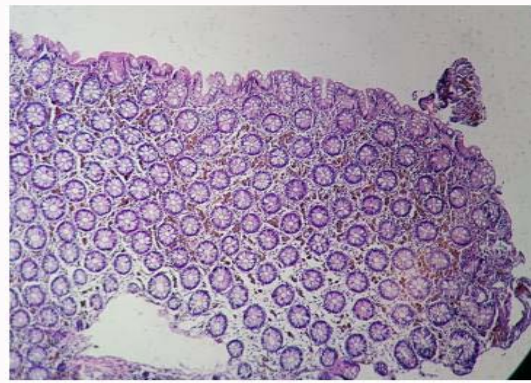


Figure 3: Clusters of pigmented cells in the chorion (HES x40).

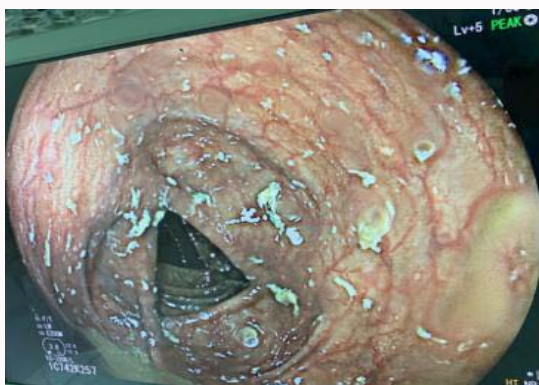

Figure 2: Pigmented appearance of the mucosa of the transverse colon on colonoscopy.

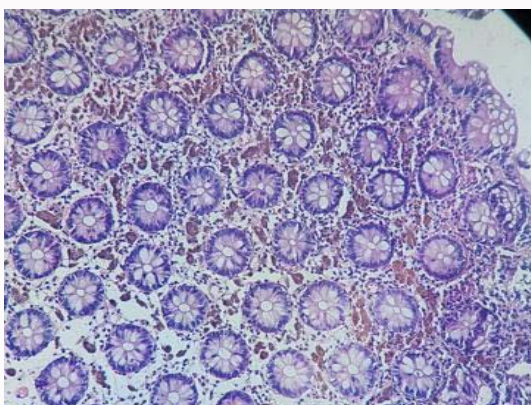


Figure 4: Brownish pigments in the mucous membrane chorion.

The treatment consisted of stopping the diacerein and replacing it with treatment based on NSAIDs and the establishment of hygienic-dietetic measures.

Discussion

Colonic melanosis is a rare, benign, reversible condition with no malignant potential [1], characterized by dark brown pigmentation of the colonic wall, the main cause of which is excessive and prolonged consumption of herbal laxatives containing anthraquinone such as *Senna*, *Buckthorn*, *Ispaghul*, and *Rhubarb* in order to treat classic symptoms of constipation may be responsible for the high incidence of colonic melanosis [2]. These plants pass through the gastrointestinal tract without being absorbed until they reach the colon, where they are transformed into their active forms [2-4].

The resulting active compounds damage cells in the lining of the colon and lead to apoptosis of the cells, the latter appear as dark pigmented bodies which can be phagocytosed by cells called macrophages in the lipofuscin-producing lamina propria, which gives a dark color to the lining of the colon. When enough cells have been damaged, the characteristic pigmentation of the colonic wall develops [5]. Melanosis lesions are described in many segments of the digestive tract, such as the esophagus, duodenum, ileum, colon, gallbladder, and appendix [1].

However, melanosis coli can be observed in patients without a history of anthraquinone use. A study of 38 patients showed that colon epithelial apoptosis was increased in melanosis coli, but the majority of cases were not associated with laxative use, suggesting that

melanosis is a marker of increased apoptosis with numerous possible causes, of which the use of anthraquinone laxatives is only one [3].

Cruveilhier was the first to describe this pigmentation in 1829, and Virchow was the first to name colonic melanosis in 1847 [6,7]. Its incidence is naturally higher in the elderly population [8] and increases in subjects who have irritable bowel syndrome or chronic constipation following the use of plants containing anthraquinones [9].

In a study carried out in patients investigated for chronic constipation associated with diffuse abdominal pain, nine cases of colonic melanosis out of a total of 2,602 colonoscopies, in a frequency of 0.3%, with a predominance of women [5]. The diagnosis of colonic melanosis requires a colonoscopy with segmental biopsies which must be done on the pigmented areas and the non-pigmented areas so as not to overlook other colonic pathologies. Histologically, the epithelial cells are unremarkable. The mucosa and submucosa are usually edematous and contain pigment-laden macrophages and plasma cells and mast cells.

Although there is currently no specific drug treatment for colonic melanosis, stopping laxatives and any other responsible medication should be started upon diagnosis. Moreover, regular monitoring by colonoscopy is necessary in order to watch for the regression or not of colonic lesions after cessation of exposure to the causative agent, as was the case for our patient.

Conclusion

As demonstrated in our study, colonic melanosis can be observed

in patients without a history of anthraquinone use and outside the context of chronic constipation. Other causes, such as taking anti-inflammatory drugs such as diacerein, may be involved.

References

1. Chaudhary BN, Sharma H, Nadeem M, Niayeshet MH. Ischemic colitis or melanosis coli: A case report. *World J Emerg Surg.* 2007;2(25).
2. Nusko G, Schneider B, Schneider I, Wittekind C, Hahn EG. Anthranoid laxative use is not a risk factor for colorectal neoplasia: Results of a prospective case control study. *Gut.* 2000;46(5):651-5.
3. Saraçoğlu A, Ergun B. Composition of some herbal slimming tea preparations marketed in Turkey and their possible adverse effects. *Turkiye Klinikleri J Med Sci.* 2006;26(4):355-63.
4. Tsobanidou Ch. Melanosis coli in two patients with colorectal neoplasia. *J Buon.* 2005;10(1):131-3.
5. Ngatcha G, Kabbaj N, Salihoun M, Ouahou S, Amrani L. La mélanose colique. *Hegel.* 2013;3(2).
6. Cruveilhier J. Cancer avec melanose. In: *Anatomie pathologique du corps humain.* Paris: Baillier; 1829. p. 19-6.
7. Özel L, Toros AB, Ersöz F, Özkara S, Güneş P. Melanosis coli, a consequence of laxative abuse? *Istanbul Med J.* 2010;11(4):171-74.
8. Kostela E, Kulju T, Collan Y. Melanosis coli, prevalence, distribution and histological features in 200 consecutive autopsies at Kuopio University Central Hospital. *Dis Colon Rectum.* 1989;32(3):235-9.
9. Sosa JL, Cortes V, Zeppa R. Melanosis coli: A case report in a trauma patient and review of the literature. *Am Surg.* 1991;57(6):378-80.
10. Eroğlu M, Coşkun AK, Günel A. Melanosis coli: Case report. *J Clin Anal Med.* 2012;3(2):234-6.
11. Ahasan HN, Mai K, Mahbub S, Alam B, Miah T, Gupta RD, et al. Melanosis coli - an atypical presentation. *J Medicine.* 2010;11(2):183.