



## Verrucous Carcinoma of Tongue: Four Reported Cases in Tertiary Hospital of Jharkhand

Madhumita Srivastava\*, Sanjoy Chowdhury, Gaurav Vishal, Aaditya Markandey Sunil and Prakash Pandey

Department of Oral and Maxillofacial Surgery, Bokaro General Hospital, India

### Abstract

Oral Verrucous carcinoma is a subtle variant of oral squamous cell carcinoma with some peculiar features. It is locally invasive and inching growth and rarely metastasises. Verrucous carcinoma rarely affects the tongue. Herein we report four cases of the same which were diagnosed and treated successfully at our tertiary care hospital.

**Keywords:** Verrucous carcinoma; Tongue; Partial glossectomy; MRI

### Introduction

Oral cancer is a worldwide public health problem, and according to the International Agency for Research on Cancer (IARC) in 2018, 1,454,892 new cases of head and neck cancer worldwide have been estimated [1]. Verrucous carcinoma is a known scarce variant of squamous cell carcinoma with some particular characteristics and has incidence of 2% to 16% of all oral cancers [2]. Also known as Ackerman's tumor as it was first construed by Ackerman [3]. The most prevailing sites of involvement include the buccal mucosa, followed by the mandibular alveolar crest, gingiva, and tongue. Presence of same on tongue is also not much disclosed in literatures. It headway slowly, locally and is invasive in nature and unlikely to metastasize [4,5]. Here we present four cases of verrucous carcinoma of tongue diagnosed and treated successfully in a tertiary care hospital of Jharkhand.

### Case Reports

#### Case 1

A 62 year old female with a history of ulcer on left side of tongue for a period of 1 month visited the hospital (Figure 1). Upon physical examination, we noticed that the left lateral border, and anterior two third of left ventral surface was completely covered with red and white lesions. Posterior third aspect had more pronounced lesion red as compared to anterior two third. The right half was unaffected. On further examination, we noticed a long-standing grossly decayed tooth 36 and 37 was missing. Cervical lymph nodes were not palpable. Patient gave a history of chronic tooth bite and had no other ill habits. A provisional diagnosis of speckled leukoplakia was made and incisional biopsy was done. The biopsy report suggested a case of Verrucous Carcinoma (VC) of tongue. A Magnetic Resonance Imaging (MRI) of the tongue and neck was done, which showed no lymph node involvement. Staging done was T1N0M0. Partial glossectomy left side of tongue was performed with electrocautery (Figure 2) and the resulting wound bed was repaired with collagen membrane (Figure 3). Figure 4 and 5 depicts wound bed post operative first day and second day.

### OPEN ACCESS

#### \*Correspondence:

Madhumita Srivastava, Department of Oral and Maxillofacial Surgery, Bokaro General Hospital, Jharkhand, India, Tel: 8986873108;

E-mail: dr.madhumitasri.20@gmail.com

**Received Date:** 11 Dec 2019

**Accepted Date:** 23 Jan 2020

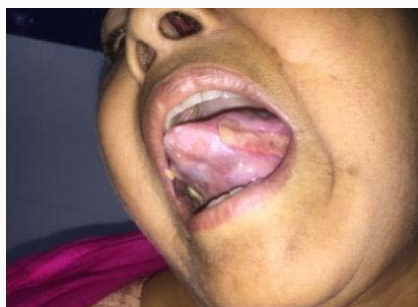
**Published Date:** 27 Jan 2020

#### Citation:

Srivastava M, Chowdhury S, Vishal G, Markandey Sunil A, Pandey P. Verrucous Carcinoma of Tongue: Four Reported Cases in Tertiary Hospital of Jharkhand. *Surg Oncol Clin Pract J.* 2020; 3(1): 1012.

#### Copyright © 2020 Madhumita

Srivastava. This is an open access article distributed under the Creative Commons Attribution License, which permits unrestricted use, distribution, and reproduction in any medium, provided the original work is properly cited.



**Figure 1:** Depicting lesion remaining after biopsy.

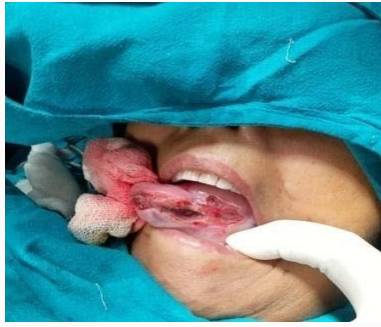

Figure 2: Wound bed after partial glossectomy.

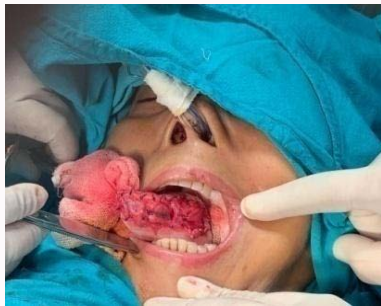

Figure 3: Closure with collagen.

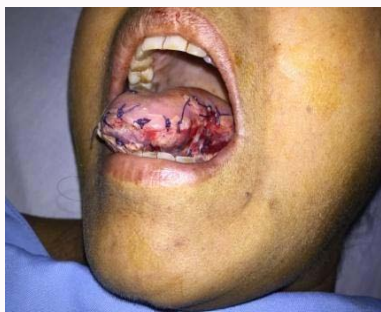

Figure 4: Post operative first day.

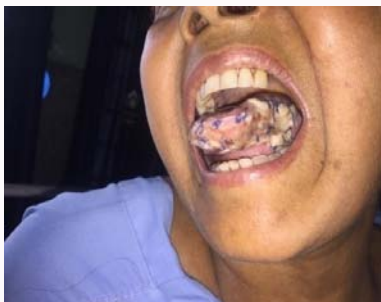

Figure 5: Post operative second day.

The final excised tissue was sent for histopathological examination (Figure 6) which again confirmed the diagnosis of VC. The patient is under regular follow-up (post operative 20 days (Figure 7) and six months (Figure 8)) with no recurrence of lesion and is advised for replacement of missing teeth.

**Case 2**

A 40 year-old gentleman presented with a 2-year history

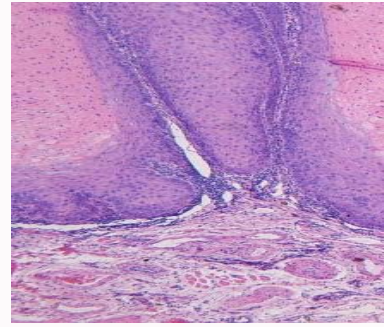


Figure 6: Squamous epithelium had papillary proliferation and severe thickening. Occasional swelled nuclei and mitoses were seen, basement membrane was intact.

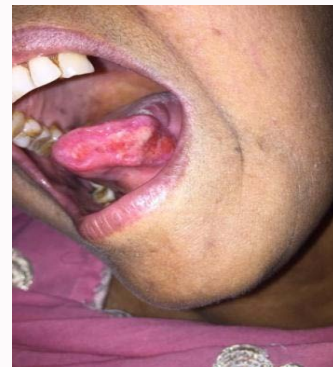

Figure 7: Tongue after 20 days.

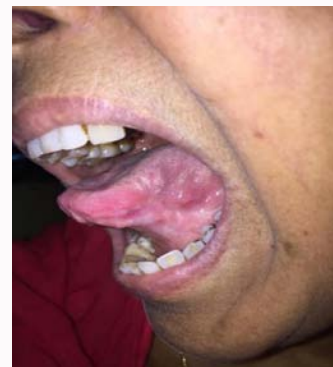


Figure 8: Tongue after 6 months.

growth on the right side of the tongue with occasional pain over the growth. He was a habitual tobacco chewer and smoker for the past 20 years, and an alcoholic too. On examination, an exophytic mass with redish white surface and multiple papillary projections was seen, involving the left lateral border of anterior half of the tongue (Figure 9). The tongue was freely mobile, mildly indurated and tender to palpation. There was no enlargement of the cervical lymph nodes. Histopathological examination confirmed the provisional diagnosis of verrucous carcinoma. The patient underwent right partial glossectomy with wound repair with collagen and there was no recurrence at 1year of follow-up.

**Case 3**

A 61-year-old man complained of the swelling and slight pain of the tongue for about three years. He was an ex-smoker and had

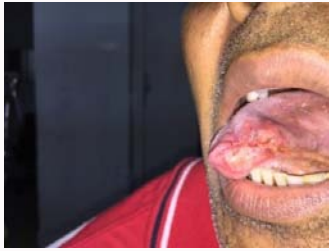

Figure 9: Case 2 with verrucous lesion.

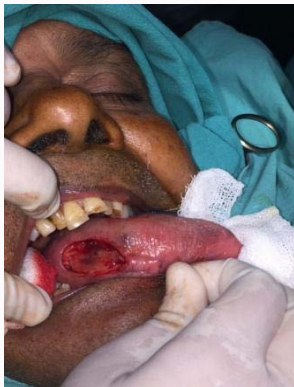

Figure 10: Case 3 Intraoperative picture of partial glossectomy showing wound bed.

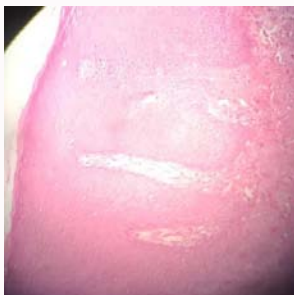

Figure 11: Papillary projection and thickening of squamous epithelial layer, with partially disappeared basement membrane.

of chewing tobacco since 30 years. Also patients 46 & 47 teeth were missing and 45 was a root stump, so patient also had history of traumatic bite. Cervical lymph nodes were not palpable. There was a papillomatous lesion on the right lateral tongue with no indurations. Incisional biopsy specimen reported as hyperkeratosis, acanthosis. Cervical lymph node metastasis was not detected by Contrast Enhanced Computed Tomography (CECT). Preoperative TNM classification was T1N0M0. Partial glossectomy was carried out with close margin (Figure 10). On histology papillary proliferation and severe thickening of squamous epithelium was observed and invasion into the basement membrane was not detected but it was partially disappeared (Figure 11). Pathologically, it was diagnosed as VC. Patient made a satisfactory recovery. There was neither local recurrence nor distant metastasis observed for about two years.

#### Case 4

A 55 year old woman complained of the swelling and pain of the tongue for about two years. She was a smoker and tobacco chewer and also her dental hygiene was poor. There was a papillomatous lesion on

the right lateral tongue with no indurations. Her clinical pictures are not available. The punch biopsy was performed and report of VC was obtained. Same lie other three patients partial glossectomy was done and wound bed was repaired with collagen. She made an uneventful recovery. There was neither local recurrence nor distant metastasis observed for three years.

### Discussion

Oral cavity is one of the predilection sites for Verrucous Carcinoma (VC). It is locally calamitous and slow flourishing in nature. Although buccal mucosa and lower gingiva are the prevalent site for this lesion, cases are also been proclaimed in the nasal cavity, larynx and esophagus. VC of the tongue is clinically scarce [4]. We report four cases of the same in two male and two females, as in literature mostly elderly male patients are reported.

Mostly patients suffering from this pathology have smoking or betel nut chewing habit history. In cases presented here three patients had tobacco history, but one patient had no history of tobacco use, shed only had chronic traumatic teeth bite history.

The gold standard for diagnosing head and neck malignancies is biopsy and subsequent histological examination. Pathologically VC is not onerous to diagnose and in 20% of cases lesions may harbor foci of invasive cancer; therefore it is essential to include reasonable depth of tissue while performing biopsy, else there are odds of having false result. A wedge incision or punch biopsy is often recommended in these situations [6,7]. One of our cases showed only acanthosis and hyperkeratotic tissue on incisional biopsy. So if one need correct report sufficient volume of tissue is necessary.

Regional lymph node metastases are rarely seen and distant metastases have not been reported in VC so neck dissection is not necessary. Neck dissection has to be done or not depends upon clinically palpable nodes, invasive carcinoma at presentation, or tumor size. For imaging tongue MRI is primary imaging modality but CECT scan is also preferred [8].

Surgery is the mainstay of treatment for oral cancers and the goal should be complete removal of the primary lesion area and pertinent clearance of regional lymph nodes, while conserving the virtue of uninvolved structures. Surgical plan involves wide excision of the tumor in all three dimensions with adequate margins. Adequacy of margins for resection of oral primary tumor is; Negative margin >5 mm, close margin 1 mm to 5 mm and positive margin <1 mm/tumor cut through. This should account for histopathological shrinkage (approximately 25%) [9-11]. For VC complete resection of the tumor with 1 close clinical margin is the best treatment of choice. In our all four cases no neck dissection was performed and only partial glossectomy with close margin was done with electrocautery. It is difficult, to keep safety margins sufficiently in head and neck region. Using electrocautery lead to cutting edges which were heat-degenerated, this might add to the improvement of the local control of the carcinomas [12]. Also it is easy to operate with less bleeding and no muscle constrictions. Also no reconstruction was done, as if <30% substance loss is there in tongue primary closure or closure of wound bed with dressing material is sufficient [13-15].

The role of radiotherapy alone in verrucous carcinoma is controversial since it may change the nature of the tumor to a poorly differentiated squamous cell carcinoma. Irradiation could be opted as the second choice for treatment when sufficient operation cannot be

done. VC has better prognosis than that of other kinds of squamous cell carcinomas. In our present cases, tumors were not so invasive and curable resection with sufficient safety margin could be performed.

## Conclusion

VC is a unique variant of squamous cell carcinoma although has less predilection for tongue but its occurrence to this site cannot be overlooked. Routine neck dissection can be avoided, as it metastasizes rarely. Partial glossectomy with electrocautery involving wide margins and reconstruction with collagen yields a good outcome.

## References

1. World Health Organization (WHO), International Agency for Research on Cancer (IARC). A Digital Manual for the Early Diagnosis of Oral Neoplasia. France: IARC.
2. Franklyn J, Janakiraman R, Tirkey AJ, Thankachan C, Muthusami J. Oral Verrucous Carcinoma: Ten Year Experience from a Tertiary Care Hospital in India. *Indian J Med Paediatric Oncol.* 2017;38(4):452-5.
3. Ackerman LV. Verrucous carcinoma of oral cavity. *Surgery.* 1948;23(4):670-8.
4. Kawakami M, Yoshimura K, Hayashi I, Ito K, Hyo S. Verrucous Carcinoma of the Tongue: Report of two cases. *Bulletin of the Osaka Medical College.* 2004;50(1,2):19-22.
5. Schilling C, Stoeckli SJ, Haerle SK, Broglie MA, Huber GF, Sorensen JA, et al. Sentinel European Node Trial (SENT): 3-year results of sentinel node biopsy in oral cancer. *Eur J Cancer.* 2015;51(18):2777-84.
6. Shah J. *Head and Neck Surgery and Oncology.* 3<sup>rd</sup> ed. St. Louis, MO: Mosby; 2003.
7. Imai H, Yoshihara T. Verrucous Carcinoma of the Tongue; Report of a Case. *Otolaryngol Head Neck Surg.* 1995;67:1165-9.
8. Shah JP. Surgical approaches to the oral cavity primary and neck. *Int J Radiat Oncol Biol Phys.* 2007;69(2 Suppl):S15-8.
9. Mohiyuddin SMA, Padiyar BV, Suresh TN, Mohammadi K, Sagayaraj A, Merchant S. Clinicopathological study of surgical margins in squamous cell carcinoma of buccal mucosa. *World J Orhinolaryngol Head Neck Surg.* 2016;2(1):17-21.
10. Kang CJ, Chang JT, Chen TM, Chen IH, Liao CT. Surgical treatment of oral verrucous carcinoma. *Chang Gung Med J.* 2003;26(11):807-12.
11. Sadasivan A, Thankappan K, Rajapurkar M, Shetty S, Sreehari S, Iyer S. Verrucous lesions of the oral cavity treated with surgery: Analysis of clinicopathologic features and outcome. *Contemp Clin Dent.* 2012;3(1):60-3.
12. Walvekar RR, Chaukar DA, Deshpande MS, Pai PS, Chaturvedi P, Kakade A, et al. Verrucous carcinoma of the oral cavity: A clinical and pathological study of 101 cases. *Oral Oncol.* 2009;45(1):47-51.
13. Urken ML, Buchbinder D, Weinberg H, Vickery C, Sheiner A, Parker R, et al. Functional evaluation following microvascular oromandibular reconstruction of the oral cancer patient: A comparative study of reconstructed and nonreconstructed patients. *Laryngoscope.* 1991;101(9):935-50.
14. Bernier J, Domenge C, Ozsahin M, Matuszewska K, Lefèbvre JL, Greiner RH, et al. Postoperative irradiation with or without concomitant chemotherapy for locally advanced head and neck cancer. *J Med.* 2004;350:1945-52.
15. Cooper JS, Pajak TF, Forastiere AA, Jacobs J, Campbell BH, Saxman SB, et al. Postoperative concurrent radiotherapy and chemotherapy for high-risk squamous-cell carcinoma of the head and neck. *N Eng J Med.* 2004;350(19):1937-1944.