



Vascular Density Changes after Treatment with a Bipolar Radiofrequency System Incorporating a Novel Applicator with the Thinnest Array of Microneedles

Anh Ly T*, Amro H and Markowitz O

Department of Ophthalmology, OptiSkin Medical, NY, USA

Abstract

Background and Objectives: There are multiple devices in the market for Radiofrequency (RF) microneedling, and prior studies have evaluated changes in vasculature and formation of microchannels with these technologies. This prospective study utilizes both Optical Coherence Tomography (OCT), and a new technology, Line-Field Optical Coherence Tomography (LC-OCT), to evaluate changes in vascularity and microchannel formation following RF-microneedling treatments.

Study Design/Materials and Method: In a prospective study, healthy adults presenting with wrinkles (n=8), melasma (n=2), and/or acne scars (n=1) received up to three RF microneedling facial treatments, with a novel applicator utilizing ultra-thin microneedles inserted at up to three depths with a single insertion, at 6-week intervals with varying follow-up visits. These patients were scanned and analyzed before and after treatment using dermoscopy, OCT, and/or LC-OCT imaging. In this study, we also included LC-OCT imaging in a subgroup of two patients to further evaluate vascular changes.

Results: Eleven subjects (1 Male/10 Female), aged 55 ± 17 years (range 25-79) with Fitzpatrick Skin Types II-V had at minimum one RF microneedling treatment during a three-month study period. A total of 50 RF microneedling treatments were performed. No dots on enface OCT at 100 μm were seen post RF-microneedling, but they were observed on dermoscopy images, which also visualizes skin at 60 μm to 100 μm in depth, immediately post-treatment, 24 h after and 1 week after RF-microneedling treatment. All patients had minimal downtime and no adverse side effects with treatment.

We observed an overall decrease in vascularity with OCT after treatment with the 3-in-1 ultrathin microneedle applicator. Vascular density was defined as the percentage of a region occupied by blood vessels in the OCT En-face images. Vascular density was measured at depths ranging from 0.05 mm to 0.5 mm. Greatest reduction in vascularity was seen at the depth of 0.5 mm. The average vascular density, at this depth, reduced from 26.3% at baseline visit to 15.1% at the follow-up visit. The statistically significant mean difference between vascular density prior to the first treatment and the latest follow-up measurement was -0.112 (-11.2%) ($p=0.0043$; 95% CI: -0.179, -0.044, using a paired t-test).

We found an overall decrease in vasculature with LC-OCT consistent with the OCT findings. With LC-OCT's increased cellular resolution, we were also able to visualize the vessels and quantify their diameter and overall appearance.

Conclusion: OCT analysis showed (i) patients treated with this new bipolar RF system with 3-in-1 ultrathin microneedles applicator had an overall decrease in vascular density and (ii) like previous studies, no dots on enface OCT at 100 μm were seen post RF microneedling but were observed on dermoscopy images. We propose the use of both OCT and LC-OCT for vascular changes with RF microneedling treatments in future studies to not only follow overall trends but also to visualize and quantify the actual vessels in 3-D. We also propose further studies on microchannel formation at increased depths and utilizing better cellular resolution technology, such as reflectance confocal microscopy or LC-OCT (at 100 μm), to further study microchannel structural properties and persistence.

OPEN ACCESS

*Correspondence:

Thu Anh Ly, Department of Ophthalmology, OptiSkin Medical, 1150 Fifth Avenue, Suite 1A, New York, 10128, USA, Tel: (212) 828-3120

Received Date: 18 Aug 2023

Accepted Date: 06 Sep 2023

Published Date: 11 Sep 2023

Citation:

Anh Ly T, Amro H, Markowitz O. Vascular Density Changes after Treatment with a Bipolar Radiofrequency System Incorporating a Novel Applicator with the Thinnest Array of Microneedles. *Ann Clin Med Res.* 2023; 4(1): 1069.

Copyright © 2023 Anh Ly T. This is an open access article distributed under the Creative Commons Attribution License, which permits unrestricted use, distribution, and reproduction in any medium, provided the original work is properly cited.

Introduction

Dermatologic patients are expressing increasing interest in minimally invasive aesthetic procedures to address a wide range of common concerns from skin laxity to acne scarring and photoaging.

Several techniques, including the use of Radiofrequency (RF) devices, are currently utilized for skin rejuvenation, and tightening. These devices emit RF currents to produce heat that coagulates adipose, fibrous, and vascular tissues, triggering wound healing processes and stimulating collagen remodeling [1]. Fractional RF microneedling devices use an array of bipolar RF micro-electrode-needles to deliver RF energy directly into the multiple skin layers; dermal and subdermal, superficial and deep tissue layers, causing thermally affected coagulation zones with unaffected areas in between, while maintaining the epidermis relatively intact. Therefore, treatment has relatively reduced downtime compared with historically more invasive procedural approaches [2].

The growing demand for various RF procedures, as well as technological advancements, led to the development of a new bipolar RF platform, the Profound Matrix™ system with 3 distinct RF modalities in a single device. The Sublime™ applicator delivers combined RF and Infrared (IR) energies for bulk tissue heating, while the Sublative™ RF applicator delivers fractional RF energy to the skin *via* an array of multi-electrode pins for a resurfacing treatment. The Matrix Pro™ is a new and innovative fractional short-pulse RF microneedling applicator that operates with the thinnest 7x7 array of semi-insulated micro-electrode chamfered needles, with a diameter of only 0.16 mm (34 gauge). It is also the only RF microneedling applicator currently in the market that can treat up to three tissue depths within one insertion application. Multi-layer tissue heating delivered in a single pass reduces the epidermal damage and treatment time associated with multiple insertions and pulse stacking. The Profound Matrix system also has a unique, built-in, impedance control module to ensure accurate energy delivery and provide real-time impedance feedback during treatment.

Optical Coherence Tomography (OCT) is a non-invasive skin imaging technique that allows visualization of microstructures beneath the skin surface, in the epidermis and upper dermis, and provides clinically relevant data about vascular architecture and the blood flow of the skin [3,4].

This prospective IRB-approved study utilized both Optical Coherence Tomography (OCT), and a new technology, line-field Optical Coherence Tomography (LC-OCT), to evaluate changes in vascularity following RF microneedling treatment with the Matrix Pro applicator [5].

Materials and Methods

Healthy adults received up to three RF microneedling facial treatments, with the Matrix Pro applicator at 6-week intervals with varying follow-up visits. The patients were scanned and analyzed, before and after each treatment, using polarized dermoscopy and OCT imaging. Polarized dermoscopy imaging was used to visualize the footprint of the Matrix Pro cartridge microneedles at subsurface levels of up to 100 μm in depth and to monitor tissue recovery after treatment, while OCT was used to evaluate changes in vascularity following treatment. OCT analyses included quantitative assessment of the skin vascular density (of the active vasculature) as a function of depth below the skin surface. Vascular density was defined as the

percentage of a region occupied by blood vessels in the OCT En-face images. The vascular density was measured at depths ranging from 0.05 mm to 0.5 mm. A blood flow density scale, ranging from 0.0 (no vessels) to 1.0 (100% of the tissue is vessels), was used for the assessment. LC-OCT imaging was performed in a subgroup of patients to obtain more detailed information.

Results

In this pilot study, we evaluated a total of 11 subjects (1 male/10

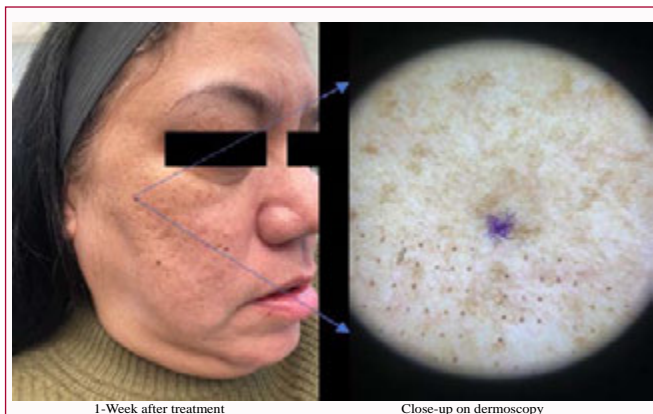


Figure 1: A female patient 1 week after treatment with Matrix Pro™. The polarized dermoscopy image on the right shows a close-up of a treated area of the face with the Matrix Pro cartridge microneedle array footprint remaining at 100 μm in depth.

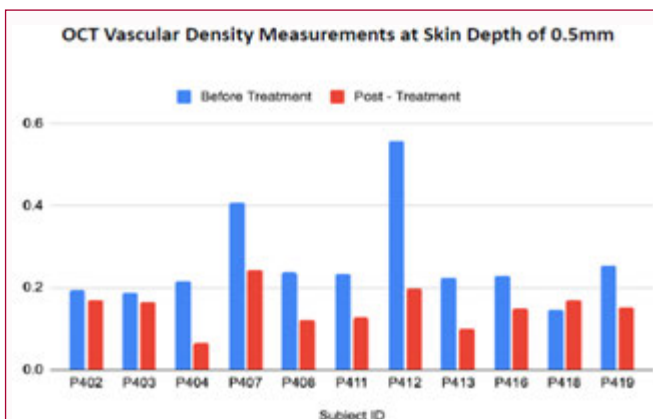


Figure 2: Vascular density reduction after treatment with Matrix Pro™.

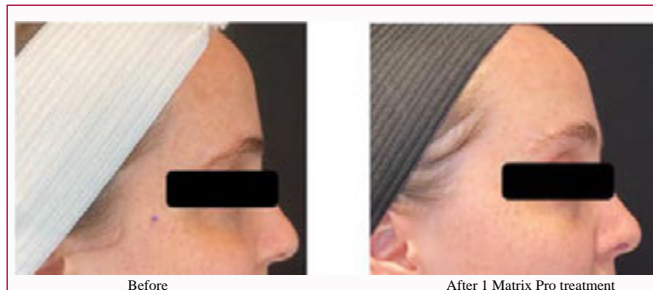

Figure 3: A 32-year-old Fitzpatrick skin type IV female presenting with irregular skin tone (pigmentation, melasma). There was visible improvement in skin tone after 1 Matrix Pro treatment to the full face (excluding jawline and submentum), using primarily single insertion to the deeper skin layer depths, with RF energy ranging from 0.5 J to 2.0 J, and a 2nd insertion to the middle depth for nasolabial folds and perioral area with RF energy of 1.0 J. Vascular density on OCT was also reduced following treatment (P416 in Figure 2 graph).

females) with mean age of 55 ± 17 years (range 25-79) and Fitzpatrick Skin Types II-V presenting with various skin conditions, such as wrinkles (n=8), melasma (n=2), and/or acne scars (n=1), who received at least one RF microneedling treatment during a three-month study period. A total of 50 RF microneedling treatments were performed. All patients experienced minimal downtime following treatments, and no adverse side effects were observed.

A pattern of dots from the Matrix Pro cartridge microneedles was observed on polarized dermoscopy images at 60 μm to 100 μm in depth, immediately post-treatment, 24 h after, and 1 week after RF microneedling treatment (Figure 1).

OCT measurements of the skin vasculature showed an overall decrease in skin vascularity after RF microneedling treatment. The greatest reduction in vascular density from baseline to the last follow-up measurement was at a depth of 0.5 mm from the skin surface. As can be seen in Figure 2, most patients (10/11, 90.9%) presented with lower vascular density after treatment. The average vascular density, at this depth, was reduced from baseline (26.3%) to the follow-up visit (15.1%) by 11.2%, showing a statistically significant decrease in vascular density ($p=0.0043$; 95% CI: -0.179, -0.044, paired t-test). LC-OCT analysis of subjects also supported our OCT findings of an overall decrease in vasculature. The LC-OCT's increased cellular resolution allowed us to quantify vessel diameter. An example of clinical photography findings is shown in Figure 3.

Conclusion

In this pilot study, OCT analysis showed that patients treated with this new bipolar RF system with the Matrix Pro applicator had an overall decrease in vascular density within the treated skin. LC-OCT imaging with its increased cellular resolution supported OCT findings. Although dermoscopy imaging showed that the healing process may continue at 1-week post-treatment, this was not reflected in increased patient downtime.

References

1. Elsaie ML. Cutaneous remodeling and photorejuvenation using radiofrequency devices. *Indian J Dermatol.* 2009;54(3):201-5.
2. Weiner SF. Radiofrequency Microneedling: Overview of technology, advantages, differences in devices, studies, and indications. *Facial Plast Surg Clin North Am.* 2019;27(3):291-303.
3. Schuh S, Holmes J, Ulrich M, Themstrup L, Jemec GBE, De Carvalho N, et al. Imaging blood vessel morphology in skin: Dynamic optical coherence tomography as a novel potential diagnostic tool in dermatology. *Dermatol Ther (Heidelb).* 2017;7(2):187-202.
4. Kislevitz M, Akgul Y, Wamsley C, Hoopman J, Kenkel J. Use of optical coherence tomography (OCT) in aesthetic skin assessment- A short review. *Lasers Surg Med.* 2020;52(8):699-704.
5. Markowitz O. Vascular density changes after treatment with a bipolar radiofrequency system incorporating a novel applicator with 3-in-1 depth ultra-thin microneedle. *Lasers Surg Med.* 2023;55 Suppl 35:S84-85.