



Uterine Septoplasty and Adhesiolysis: Difficult Hysteroscopic Surgery and Intrauterine Carboxymethyl Cellulose + Polyethylene Oxide Dual Polymer Gel Resulted in Good Clinical Outcomes: Three Case Reports

da Cunha Vieira M^{1,2}, Kondo W³, Menakaya U⁴ and diZerega G^{5,6*}

¹Department of Gynecology, Hospital das Clinicas HCFMUSP & University of Sao Paulo, Brazil

²Division of Gynecology, BP - A Beneficencia Portuguesa de Sao Paulo, Brazil

³Sugisawa Hospital, Avenida Iguacu, Brazil

⁴Obstetrician, Gynecologist, Sonologist and Laparoscopic Surgeon, JUNIC Specialist Imaging and Women's Center, Australia

⁵Department of Obstetrics and Gynecology, Keck School of Medicine, University of Southern California, USA

⁶FzioMed, San Luis Obispo, California, USA

Abstract

Difficult hysteroscopic procedures, such as septoplasty and lysis of severe adhesions, can often lead to the formation of adhesions and result in poor clinical outcomes, including menstrual disorders, infertility, and gestational loss. The hysteroscopic surgical procedures, performed in the three case reports presented in this article, including septoplasty and lysis/removal of severe adhesions, resulted in no adhesion formation in the uterine cavity and achieved good clinical outcomes. In a retrospective study, 31% of patients developed intrauterine adhesions following septoplasty. Those with a history of prior endometrial curettage or miscarriage followed by curettage had a 44% to 46% rate of intrauterine adhesions. To prevent the reformation of adhesions following adhesiolysis or septoplasty, many gynecologists are inserting space occupying materials, such as balloons, IUDs, and gels into the uterine cavity post hysteroscopic procedures.

These treatments have been beneficial for patients following hysteroscopic resection of adhesions, septum, myomas or retained products of conception.

In this article, we report on the successful outcomes of three patients, treated by three different gynecologists, at different centers, each undergoing challenging hysteroscopic surgery to remove extensive disease, including a uterine septum and severe adhesions. Following these procedures, a synthetic dual polymer gel (CMC+PEO) was inserted into their uterine cavities. The results extended previous observations, showing no adhesions, normalization of menstruation, and successful pregnancies that went to term.

In conclusion, insertion of a synthetic gel into the intrauterine cavity, as demonstrated in these three case reports, resulted in good clinical outcomes, following difficult hysteroscopic surgery. Although intrauterine gels are currently available for use, randomized, multicenter, clinical trials with clinically focused primary outcomes are needed to further characterize the benefits of this simple approach to adhesion prevention.

Introduction

Surgical hysteroscopy is commonly performed to evaluate the interior of the uterus for removal of an IUD, adhesiolysis, polypectomy, septoplasty, and myomectomy, with good clinical results in terms of menstrual regularity and reproductive function. Often, hysteroscopic guided biopsies of the endometrial cavity are performed to acquire specific tissue for diagnosis of suspicious lesions. In contrast, more challenging hysteroscopic procedures, such as septoplasty and lysis of severe adhesions, often result in the formation of severe adhesions and poor clinical outcomes.

Intrauterine adhesions are a common pathologic condition that arises from the disruption

OPEN ACCESS

*Correspondence:

Gere diZerega, Department of Obstetrics and Gynecology (ret.), Keck School of Medicine, University of Southern California, California, USA,

Received Date: 08 Aug 2024

Accepted Date: 22 Aug 2024

Published Date: 27 Aug 2024

Citation:

da Cunha Vieira M, Kondo W, Menakaya U, diZerega G. Uterine Septoplasty and Adhesiolysis: Difficult Hysteroscopic Surgery and Intrauterine Carboxymethyl Cellulose + Polyethylene Oxide Dual Polymer Gel Resulted in Good Clinical Outcomes: Three Case Reports. *J Clin Obstet Gynecol Infertil.* 2024; 8(1): 1067.

Copyright © 2024 diZerega G. This is an open access article distributed under the Creative Commons Attribution License, which permits unrestricted use, distribution, and reproduction in any medium, provided the original work is properly cited.

of the endometrial-myometrial junction. These adhesions consist of fibrotic tissue that usually forms following surgical trauma or infections. Although they can be asymptomatic, adhesions can cause amenorrhea or hypomenorrhea, as well as infertility and gestational losses. Any hysteroscopic surgery may create adhesions; however, the leading causes are uterine curettage of retained products of conception and hysteroscopic surgical procedures [1-6]. Blockage by adhesions of the tubal ostia or intrauterine implantation sites often results in infertility.

The hysteroscopic surgical procedures performed in the three case reports presented here, specifically septoplasty and lysis/removal of severe adhesions, are often followed by adhesion formation and reformation, menstrual abnormalities, pregnancy wastage and/or infertility [7-11]. In a retrospective study, 31% of patients who underwent septoplasty were found to have intrauterine adhesions as detected by transvaginal ultrasound or hysteroscopy. Furthermore, those with a history of prior endometrial curettage or miscarriage followed by curettage had a 44% to 46% rate of intrauterine adhesions [8].

Case Series

Case 1. Cornual pregnancy, uterine septum, intrauterine adhesions, amenorrhea

The patient is a 34-year-old who was diagnosed with a 6-week pregnancy in the left cornua of a septate uterus diagnosed *via* ultrasound (Figure 1). At eight weeks, the patient experienced a spontaneous abortion followed by an uncomplicated intrauterine aspiration. Following the procedure, a three-dimensional transvaginal ultrasound confirmed the diagnosis of a uterine septum measuring 1.5 cm in depth and 4.2 cm in inter-ostial distance (Figure 2). Within two months following the uterine aspiration, the patient developed amenorrhea, raising the suspicion of intrauterine adhesions.

Given the patient’s clinical situation and desire for future reproduction, a surgical hysteroscopy was performed to remove intrauterine adhesions and to perform a septoplasty. To prevent the formation of new adhesions, 10 ml of a synthetic dual polymer CMC+PEO gel was inserted into the uterine cavity at the end of the procedure.

Operative approach: The procedure was performed in the operating room using the Bettocchi hysteroscope with saline solution as the uterine distension medium at a pressure of 60 mmHg. Initially, cervical canal adhesions were observed and disassembled using a 5-Fr grasping instrument. After encountering difficulty accessing the intrauterine cervical os, a normal volume intrauterine cavity was revealed, along with the presence of a partial fundal septum measuring approximately 2 cm. Adhesions were present in the left cornua, the previous site of gestational sac implantation. These adhesions were lysed under direct visualization using 5-Fr scissors.

After the lysis of adhesions, the hysteroscope was removed. Cervical dilation was performed up to a Hegar dilator size 9, and a 27-Fr resectoscope equipped with a Collins bipolar loop was inserted through the cervical canal. Using the Collins loop, in the cutting mode, septoplasty was performed with resection of the septum through its medial portion. This was achieved with smooth and precise movements of the cutting loop, guided from the apex toward the base of the septum. Completion of septoplasty was confirmed upon visualization of both tubal ostia and the entire intrauterine cavity, along with the presence of small myometrial vessels. To

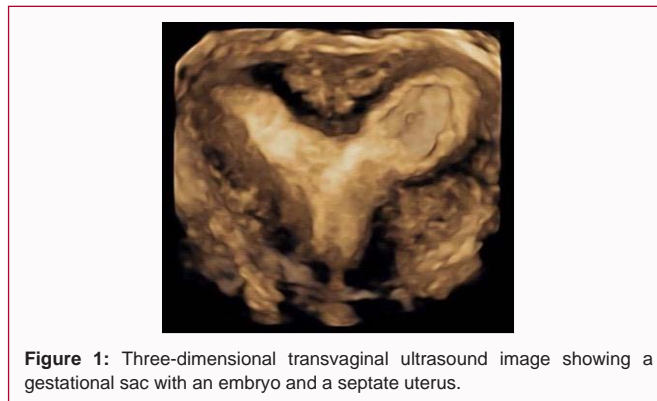


Figure 1: Three-dimensional transvaginal ultrasound image showing a gestational sac with an embryo and a septate uterus.

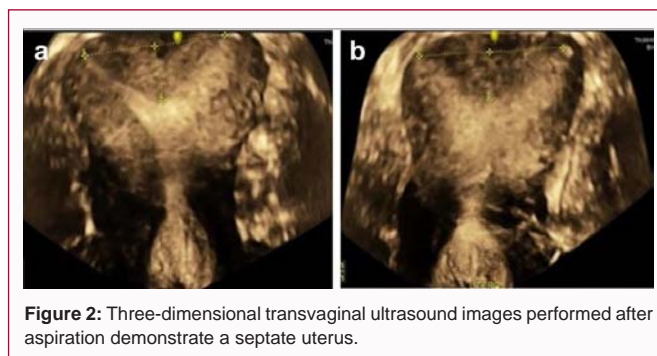


Figure 2: Three-dimensional transvaginal ultrasound images performed after aspiration demonstrate a septate uterus.

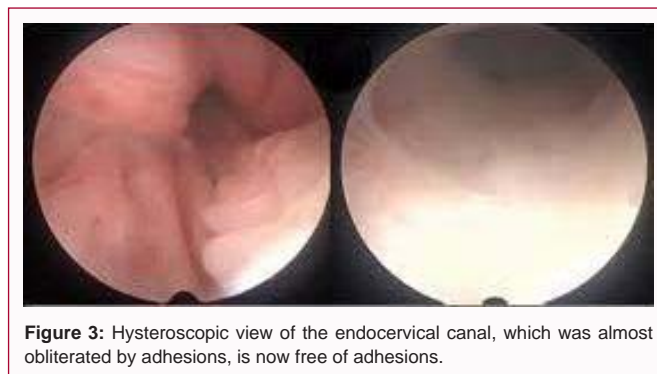

Figure 3: Hysteroscopic view of the endocervical canal, which was almost obliterated by adhesions, is now free of adhesions.

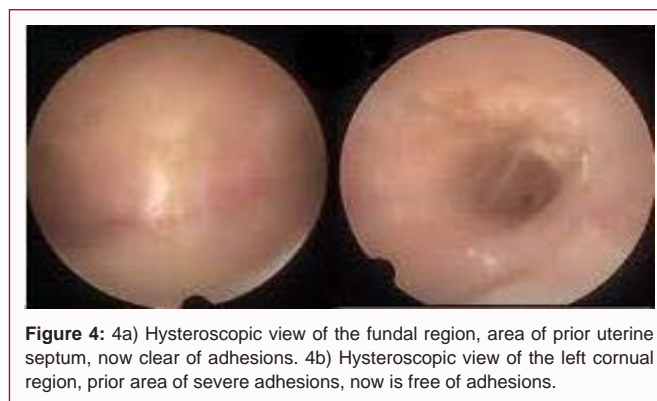

Figure 4: 4a) Hysteroscopic view of the fundal region, area of prior uterine septum, now clear of adhesions. 4b) Hysteroscopic view of the left cornual region, prior area of severe adhesions, now is free of adhesions.

prevent the formation of intrauterine adhesions, 10 ml of a synthetic dual polymer CMC+PEO gel was inserted into the uterine cavity at the end of the procedure. The patient was discharged on the same day.

Post procedure: The patient experienced mild vaginal bleeding for 5 days and mild post-procedure dysmenorrhea, which resolved without analgesics. After 40 days, a second look office hysteroscopy

was performed using the Bettocchi hysteroscope. The cervical canal was patent, with no signs of stenosis or adhesions (Figure 3). Additionally, both the septum resection site and the left cornual region appeared normal without adhesions (Figure 4).

Case 2. Septate uterus, intrauterine adhesions, and pelvic endometriosis

The patient is a 40-year-old woman, with a history of three previous curettages and hysteroscopies for removal of adhesions from the uterine septum and adjacent uterine walls. She experienced three miscarriages (2 at 15-16 weeks, and one at 8 weeks), and delivered a premature birth at 21 weeks. She presented with symptoms of dysmenorrhea, rated at 4 out of 10. She underwent a surgical hysteroscopic procedure, including a fundal metroplasty using a Gubbini Mini resectoscope, and adhesiolysis. Laparoscopy was also performed, which identified multiple sites of endometriosis that were excised or fulgurated: ovarian fossae, uterosacral ligaments, rectovaginal septum, and anterior wall of the rectum. Thirty days later, a follow up surgical hysteroscopy identified residual adhesions on the left lateral wall and right sidewall of the uterine fundus, obscuring the tubal ostia, which were resected (Figure 5). In addition, the septum in the upper fundus was observed and subsequently removed (Figure 6). At the end of the procedure, 10 ml of a synthetic dual polymer CMC+PEO gel was inserted into the uterine cavity to prevent adhesion reformation. Subsequently, the patient achieved pregnancy and carried it to term.

Case 3. Septate uterus, miscarriages, vaginal bleeding

The patient is a 34-year-old with a septate uterus who experienced miscarriages and excessive vaginal bleeding. A 3D ultrasound imaging (Figure 7) and a saline infusion sonography (Figure 8) confirmed the presence of a septate uterus. The patient underwent counseling to discuss the role of the uterine septum in recurrent pregnancy

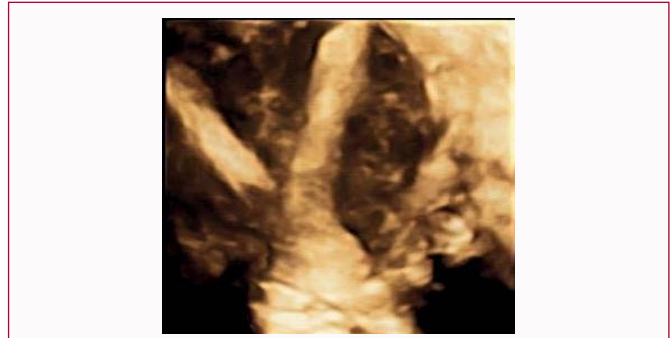

Figure 7: Three-dimensional transvaginal ultrasound image demonstrating septate uterus.

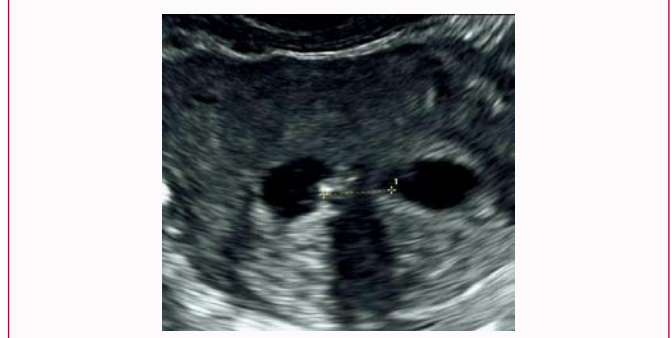

Figure 8: Saline infusion sonography image demonstrating septate uterus.

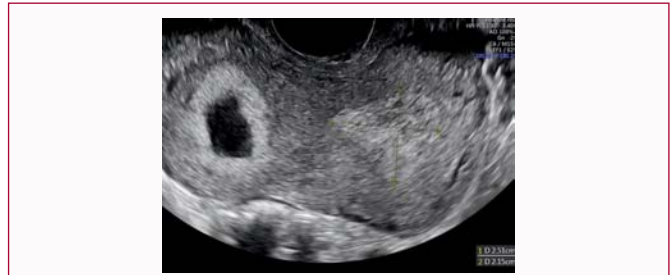

Figure 9: Transvaginal ultrasound image showing location of gestational sac at 7 weeks 5 days in the right uterine cornua with dense decidua in the left uterine cavity.

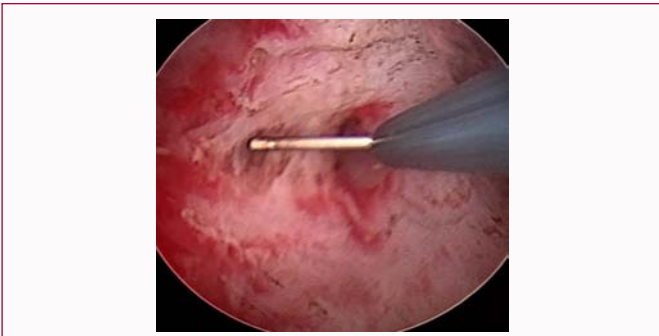


Figure 5: Hysteroscopic view of the lysis of uterine adhesions on right lateral wall, obliterating the right tubal ostium.

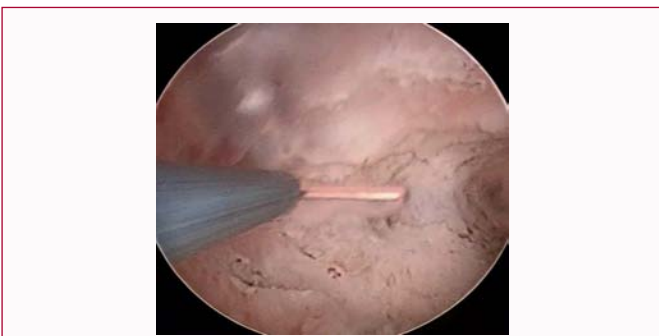


Figure 6: Hysteroscopic view of the removal of uterine septum at the fundus.

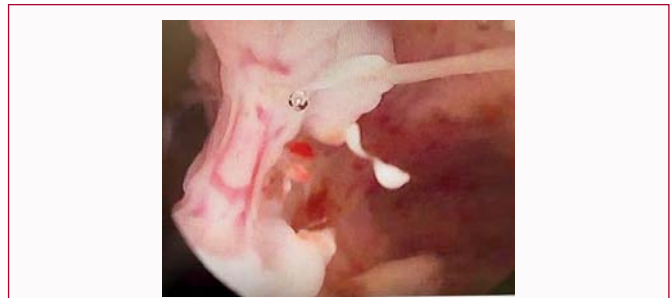

Figure 10: Hysteroscopic view of the uterine septum showing the left cavity and the septum.

losses. Initially, she decided to manage the septum expectantly and subsequently conceived in the left cornua (Figure 9) within three months of her first miscarriage.

During her pregnancy, the patient developed persistent vaginal bleeding, starting at 8 weeks of gestation and subsequently miscarried at 17 weeks of gestation. Following her 2nd miscarriage, she opted for

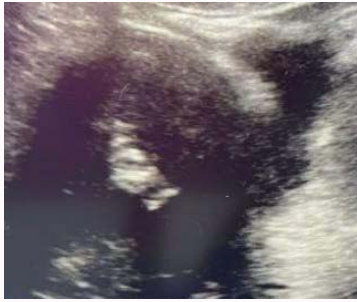

Figure 11: Transabdominal 2D gray scale imaging of the synthetic dual polymer CMC+PEO gel appearing as hyper echogenic material in the endometrial cavity.

hysteroscopic resection of the uterine septum.

Operative approach: The patient underwent a hysteroscopic resection of her uterine septum with the 2.9 mm operative Bettocchi hysteroscope (Figure 10). The procedure was uncomplicated, with less than 50 ml blood loss. After the procedure, 10 ml of a synthetic dual polymer CMC+PEO gel was instilled into the uterine cavity, which was visualized *via* a transabdominal 2D gray ultrasound during a clinic visit 2 weeks post septoplasty (Figure 11). There was minimal ooze from the resection site at the time of gel application.

Follow-up: The patient reported no abdominal discomfort or vaginal discharge immediately after surgery. She started a 3-month regimen of hormonal treatment as per a routine post-intrauterine surgery protocol, including 3 weeks of Progynova, 2 mg daily, followed by a week of Provera, 10 mg daily. Her menstrual cycles were reported as normal, with menstrual flows of 3 days in the first 3 months after surgery.

At her 6-week postoperative evaluation, a 3D image of her uterus showed normal findings. Additionally, she underwent a repeat hysteroscopy three months post-surgery to further evaluate her endometrial cavity and assess her tubal patency. The hysteroscopy showed a normalized single endometrial cavity with no adhesions post-resection and patent tubal ostia. Hormonal treatment was discontinued after the hysteroscopy, and she spontaneously conceived within a month. The patient successfully delivered a baby boy at 39-weeks' gestation.

Discussion

Treatment of intrauterine adhesions involves adhesiolysis or resection during hysteroscopy. Unfortunately, adhesions often recur at the site of removal and other sites within the uterus [5]. As a result, many gynecologists use space occupying materials [6,12], such as balloons [13,14], IUDs [14], and gels [11-21] inserted into the uterine cavity following hysteroscopic surgery to prevent adhesions [22]. Published reports, including randomized trials, have demonstrated that patients benefit from these interventions following hysteroscopic resection of adhesions, myomas, septum, or retained products of conception, with minimal risk of infection, prolonged uterine cramping, or bleeding [12].

Here, we report favorable clinical outcomes in three patients who underwent difficult hysteroscopic surgery to remove extensive disease, including uterine septum and severe adhesions. Following the procedures, the patients received a synthetic dual polymer gel composed of carboxymethylcellulose and polyethylene oxide

(CMC+PEO, Oxiplex/IU, FzioMed, San Luis Obispo, CA) inserted into their uterine cavity. Early clinical trials have shown that synthetic dual polymer CMC+PEO gels are safe and effective [21]. The study divided 110 patients into 2 groups (Group 1: Hysteroscopic surgery and installation of gel; Group 2: Only hysteroscopic surgery). There were fewer moderate and severe adhesions in Group 1 compared to Group 2.

The prevalence of intrauterine adhesions following septoplasty, a difficult hysteroscopic surgical procedure, has been reported to range between 22% to 28% when using of a Foley balloon, gels, and/or an IUD inserted into the uterus to reduce adhesion formation [9]. Women with intrauterine adhesions are considered moderate-high risk obstetric patients [23]. Of interest, the three cases reported here involving the use of a synthetic dual polymer CMC+PEO gel in the uterine cavity, following septoplasty and adhesiolysis, resulted in positive outcomes, including endometrial cavities without adhesions, normalization of menstruation, and successful pregnancies.

While intrauterine gels are currently available for use, randomized, multicenter, clinical trials with focused primary outcomes are necessary to further characterize the benefits of this simple approach to prevent adhesions following difficult hysteroscopic surgery. Although case reports do not substitute for randomized clinical trials, they offer insights into new techniques or products available in surgical practice. This is particularly crucial for women experiencing debilitating pelvic pain or aiming for successful reproduction after miscarriage(s) or infertility, where timely intervention is essential.

In conclusion, the insertion of gels into the intrauterine cavity, as illustrated in these three case reports, using a synthetic dual polymer CMC+PEO gel, resulted in favorable clinical outcomes following septoplasty and adhesiolysis, challenging hysteroscopic procedures.

Acknowledgment

The authors would like to thank Rachel Covey, Colleen Turner, and T. Carl Harday for their professional assistance with preparation of the manuscript. Oxiplex IU is the trade name of the synthetic dual polymer CMC+PEO gel that is manufactured by FzioMed, Inc. in San Luis Obispo, California, USA.

References

- Evans-Hoeker EA, Young SL. Endometrial receptivity and intrauterine adhesive disease. *Semin Reprod Med.* 2014;32(05):392-401.
- Hanstede MMF, van der Meij E, Veersema S, Emanuel MH. Live births after Asherman syndrome treatment. *Fertil Steril.* 2021;116(4):1181-7.
- Hanstede MMF, van der Meij E, Goedemans L, Emanuel MH. Results of centralized Asherman surgery, 2003–2013. *Fertil Steril.* 2015;104(6):1561-8.e1.
- Hamerlynck TWO, Meyers D, Van der Veken H, Bosteels J, Weyers S. Fertility outcome after treatment of retained products of conception: A systematic review. *Gynecol Surg.* 2018;15(1):12.
- Lee W-L, Liu C-H, Cheng M, Chang W-H, Liu W-M, Wang P-H. Focus on the primary prevention of intrauterine adhesions: Current concept and vision. *Int J Mol Sci.* 2021;22(10):5175.
- Esber S, Etrusco A, Laganà AS, Chiantera V, Arsalan HM, Khazzaka A, et al. Clinical outcomes after the use of antiadhesive agents in laparoscopic reproductive surgery. *Gynecol Obstet Invest.* 2023;88(6):325-35.
- Dason ES, Mathur S, Murji A. Hysteroscopic septoplasty: Many techniques, little evidence. *Fertil Steril.* 2021;116(5):1426-7.

8. Shen M, Duan H, Chang Y, Lin Q. Prevalence and risk factors of intrauterine adhesions in women with a septate uterus: A retrospective cohort study. *Reprod Biomed Online*. 2022;44(5):881-7.
9. Yu X, Yuhan L, Dongmei S, Enlan X, Tinchu L. The incidence of post-operative adhesion following transection of uterine septum: a cohort study comparing three different adjuvant therapies. *Eur J Obstet Gynecol Reprod Biol*. 2016;201:61-4.
10. Fayek B, Yang EC, Liu Y, Bacal V, AbdelHafez FF, Bedaiwy MA. Uterine septum and other Müllerian anomalies in a recurrent pregnancy loss population: Impact on reproductive outcomes. *J Minim Invasive Gynecol*. 2023;30(12):961-9.
11. Alvero R, Burney RO, Khorshid A, Saravanabavanandhan B, Pier BD, Rosalik KF, et al. Surgical treatment of uterine septum to improve reproductive outcomes - resect or not? *Fertil Steril*. 2021;116(2):298-305.
12. Konci R, Caminsky N, Tulandi T, Dahan MH. Supplements to conventional treatment after hysteroscopic lysis of intrauterine adhesions: A systematic review. *J Obstet Gynaecol Can*. 2020;42(8):984-1000.
13. Shi X, Saravelos SH, Zhou Q, Huang X, Xia E, Li TC. Prevention of postoperative adhesion reformation by intermittent intrauterine balloon therapy: A randomised controlled trial. *BJOG*. 2019;126(10):1259-66.
14. Lin X-N, Zhou F, Wei M-L, Yang Y, Li Y, Li TC, et al. Randomized, controlled trial comparing the efficacy of intrauterine balloon and intrauterine contraceptive device in the prevention of adhesion reformation after hysteroscopic adhesiolysis. *Fertil Steril*. 2015;104(1):235-40.
15. Cheng M, Chang W-H, Yang S-T, Huang H-Y, Tsui K-H, Chang C-P, et al. Efficacy of applying hyaluronic acid gels in the primary prevention of intrauterine adhesion after hysteroscopic myomectomy: A meta-analysis of randomized controlled trials. *Life*. 2020;10(11):285.
16. Zhou Q, Shi X, Saravelos S, Huang X, Zhao Y, Huang R, et al. Auto-cross-linked hyaluronic acid gel for prevention of intrauterine adhesions after hysteroscopic adhesiolysis: A randomized controlled trial. *J Minim Invasive Gynecol*. 2021;28(2):307-13.
17. van Wessel S, Hamerlynck T, Schutyser V, Tomassetti C, Wyns C, Nisolle M, et al. Anti-adhesion gel versus no gel following operative hysteroscopy prior to subsequent fertility treatment or timed intercourse (AGNOHSTIC), a randomized controlled trial: Protocol. *Hum Reprod Open*. 2021;2021(1):hoab001.
18. Liu Y-R, Liu B, Yang B-P, Lan Y, Chi Y-G. Efficacy of hyaluronic acid on the prevention of intrauterine adhesion and the improvement of fertility: a meta-analysis of randomized trials. *Complement Ther Clin Pract*. 2022;47:101575.
19. Trinh TT, Nguyen KD, Pham HV, Ho TV, Nguyen HT, O'Leary S, et al. Effectiveness of hyaluronic acid gel and intrauterine devices in prevention of intrauterine adhesions after hysteroscopic adhesiolysis in infertile women. *J Minim Invasive Gynecol*. 2022;29(2):284-90.
20. Fuchs N, Smorgick N, Ben Ami I, Vaknin Z, Tovbin Y, Halperin R, et al. Intercoat (Oxiplex/AP Gel) for preventing intrauterine adhesions after operative hysteroscopy for suspected retained products of conception: Double-blind, prospective, randomized pilot study. *J Minim Invasive Gynecol*. 2014;21(1):126-30.
21. Di Spiezio Sardo A, Spinelli M, Bramante S, Scognamiglio M, Greco E, Guida M, et al. Efficacy of a polyethylene oxide-sodium carboxymethylcellulose gel in prevention of intrauterine adhesions after hysteroscopic surgery. *J Minim Invasive Gynecol*. 2011;18(4):462-9.
22. Doroftei B, Dabuleanu A-M, Ilie O-D, Maftei R, Anton E, Simionescu G, et al. Mini-review of the new therapeutic possibilities in Asherman syndrome—where are we after one hundred and twenty-six years? *Diagnostics*. 2020;10(9):706.
23. Deans R, Vancaillie T, Ledger W, Liu J, Abbott JA. Live birth rate and obstetric complications following the hysteroscopic management of intrauterine adhesions including Asherman syndrome. *Hum Reprod*. 2018;33(10):1847-53.