



Using Fuzzy C-Means Index Matrix on Magnetic Resonance Images to Define Possible Cortical Malformations with Epilepsy – A Pilot Study

Yue-Loong Hsin^{1,2}, Tomor Harnod^{2,3} and Tzu-Wang Shen^{4*}

¹Department of Neurology, Chung Shan Medical University Hospital, Taiwan

²Tzu Chi University, Taiwan

³Department of Neurosurgery, Hualien Tzu Chi General Hospital, Taiwan

⁴Department of Medical Informatics, Tzu Chi University, Taiwan

Abstract

Background: Cortical malformations are important etiologies of brain developmental disorders and epileptic seizures. However, the limitations of resolution on magnetic resonance imaging (MRI) cause a high percentage of cerebral cortical malformations invisible on regular images.

Methods: Our method was developed to enhance the degree or value of blurring in the area between gray and white matters which meets the common features of cerebral cortical malformation on MR images. We retrospectively reviewed the data of six patients who had defined their seizure foci by electroencephalography recordings. Regular MR images were performed in these patients on a 1.5-T scanner with fast spoiled gradient echo sequence. The algorithm developer investigated the MRI data without knowing any clinical information. We applied the fuzzy analysis to generate a fuzzy C-means index matrix (FIM) and quantify the degree of blurring in the area between gray and white matters to meet features of cerebral cortical malformation.

Results: Comparing results of FIM in all square fragments allowed noting the areas with higher values than the background. The enhancement procedures could successfully pointed out the blurring regions of gray-white matter junctions and those highly matched the electroencephalography identified foci. Our FIM technique successfully identified five out of six cases with possible cerebral cortical malformations which corresponding to their epilepsies.

Conclusion: Using FIM technique can identify cerebral cortical malformation or micro-disorganization. This technique can help physicians define possible seizure focus.

Keywords: Cortical malformation; Epilepsy; Fuzzy C-means; MRI

Introduction

Malformations caused by cortical development abnormalities are known as disorders of cortical development, cortical dysgenesis, neuronal migration disorder, and cortical dysplasia [1]. Cerebral cortical malformations are important etiologies of brain developmental disorders and epileptic seizures. Focal cortical dysplasia (FCD) is the most well known cerebral cortical malformation underlying focal cortical epileptogenicity [2,3]. The features of FCD on magnetic resonance imaging (MRI) are usually described as blurring of the gray-white matter junction, thickening of cortical ribbon, abnormal gyral and sulcal contours, and volume and signal intensity changes of grey matter of the cerebral cortex [4,5]. However, the limitations of current imaging resolution mean that a high percentage of cerebral cortical malformations are still invisible on regular MR images [4,6].

Brain tissues with cerebral cortical malformation have changed properties, with reduced free water and shortened T2 and T1 relaxation times in MRI signals [7]. These phenomena can be detected and magnified by the recently developed magnetic resonance spectroscopy technology and image enhancement algorithms. The unsupervised learning method of fuzzy C-means (FCM) uses artificial neural networks for classification and has been widely used for tissue segmentation of MR images of the human brain [8,9]. Tissue segmentation of medical images is a currently important processing tool for classifying tissues, diagnosing diseases, and beginning three-dimensional reconstruction

OPEN ACCESS

*Correspondence:

Tzu-Wang Shen, Department of Medical Informatics, Tzu Chi University, 701, Sec. 3, Chung-Yang Road, Hualien, Taiwan,

E-mail: tshen@mail.tcu.edu.tw

Received Date: 17 Apr 2017

Accepted Date: 05 Jun 2017

Published Date: 12 Jun 2017

Citation:

Hsin Y-L, Harnod T, Shen T-W. Using Fuzzy C-Means Index Matrix on Magnetic Resonance Images to Define Possible Cortical Malformations with Epilepsy – A Pilot Study. *Ann Neurol Surg.* 2017; 1(1): 1003.

Copyright © 2017 Shen T-W. This is an open access article distributed under the Creative Commons Attribution License, which permits unrestricted use, distribution, and reproduction in any medium, provided the original work is properly cited.

Table 1: Clinical data of our patients with comparison to the results of fuzzy C-means index matrix (FIM) analysis.

Patient No.	Gender	Age (years)	Duration of epilepsy (years)	Scalp EEG findings	Did the FIM analysis match EEG finding?
1	Female	63	7	Irregular alpha activity mixed with sharp waves in occipital regions, predominantly from left occipital region	Yes
2	Female	27	13	Many median amplitude of sharp waves with phase reversal at left parietal region	Yes
3	Male	42	10	Sharp and irregular theta waves arising from bilateral occipital regions intermittently	Yes
4	Male	27	6	Spikes from bilateral frontal regions and more small spiky alpha activities from right frontal region	Yes
5	Male	43	7	Spikes and sharp waves arising from right occipital region intermittently	Yes
6	Male	28	10	Many spikes and sharp theta waves with phase reversal at right frontal and temporal regions	No

from a set of two-dimensional images [10]. Unlike usual brain image segmentation, our work seeks to apply the fuzzy analysis to generate a fuzzy C-means index matrix (FIM), that quantifies the degree or value of blurring in the area between gray and white matters and meets the common features of cerebral cortical malformation on MR images. In this study, our method was developed to enhance the visually undetectable blurring of the gray-white matter junction, identify the possible cerebral cortical malformation and help physicians define the seizure foci in patients.

Methods

Clinical data of patients

We retrospectively reviewed the clinical data of six patients who had long-term electroencephalography (EEG) recordings to study their epilepsies at the Hualien Tzu Chi General Hospital. All subjects had their seizure foci defined in EEG recordings by the same EEG specialist (Hsin YL), and all of them were diagnosed with extra-temporal lobe (neocortical) focal epilepsies (Table 1). Regular MRI studies were performed in these patients on a 1.5-T scanner (GE, Milwaukee, WI, USA) with a standard circular polarized head coil. The fast spoiled gradient echo sequence was used with the MRI software (GE Signa HD) set to these acquisition parameters: TR/TE=12/5.2 ms, flip angle=20°, matrix=512 × 512, and slice thickness=1.0 mm. When neocortical microstructural malformations were evaluated, patients were excluded if they had visible MRI abnormalities such as mesial temporal lobe sclerosis, hippocampal atrophy, brain tumor, arachnoid cyst, and hemimegalencephaly. All the patients in this study did not have structural anomalies found by visual assessment of radiologists on their MR images.

The ethical review board of the Hualien Tzu Chi General Hospital reviewed and approved this study.

Computation of fuzzy C-means index matrix from MR images

The algorithm developer (Shen TW) investigated the MRI data of the patients without knowing any clinical information such as abnormal EEG patterns and regions. The FIM sought to enhance the blurred area from a MR image by calculating a “fuzzy index” for each MRI pixel, as briefly described in steps below.

The method modifies the traditional C-means index into a fuzzy index, so the clustering can be based on (a) the distances between each point and code words, and (b) the degrees of membership for each point. The FCM algorithm follows the same steps as the C-means algorithm. However, instead of binary indices, FCM applies degrees of membership as indices. This method finds the minimum distance D between input vector x and specific classes.

$$D_{\min} = \frac{1}{N} \sum_{i=1}^C \sum_{j=1}^N I(x_j, i) d(x_j, w_i) \tag{1}$$

where C is number of classes, N is total number of data samples, w_i is a codebook, and $d(x_j, w_i)$ is the distance between x_j and w_i . The procedure first initializes each element of the fuzzy index matrix (FIM), I_{ij} , to make the sum of elements equal to one.

$$\sum_{i=1}^C I(x_j, i) = 1, \forall j = 1, \dots, N \tag{2}$$

Then, the codebook w_i is computed by using I_{ij} and input vector x.

$$w_i = \frac{\sum_{j=1}^N I(x_j, i) x_j}{\sum_{j=1}^N I(x_j, i)} \tag{3}$$

Each index of FIM is updated by using a new codebook w_i .

$$I(x_j, i) = \frac{1}{\sum_{s=1}^C \left(\frac{\|x_j - w_i\|}{\|x_j - w_s\|} \right)^{\frac{2}{m^*}}} \tag{4}$$

where I represent an fuzzy index on each pixel and the power index m^* is set as 2. The value $\|x_j - w_i\|$ is the norm between data and a center point. The distance of fuzzy C-means is calculated by

$$D = \frac{1}{N} \sum_{i=1}^C \sum_{j=1}^N I(x_j, i) \|x_j - w_i\|^2 \tag{5}$$

Then steps 1 through 4 are run until all codebooks converge.

Two dimensional filtering with Fourier transformation

Equation (4) indicates that FIM determines chance as a percentage for classifying gray matter, white matter, and cerebrospinal fluid. If only gray matter and white matter are considered, the fuzzy index matrix I with proper threshold settings can indicate the blurring area of the gray-white matter junction. Hence, I=all elements of $I(x_n, i)$ between 0.6 and 0.4. The value indicates the possible blurring areas of gray-white matter junctions. After those fuzzy points are selected, the fuzzy index matrix of the FCM method would be combined with two-dimensional (2-D) Fourier filtering to demonstrate the enhanced blurring areas of gray-white matter junctions. The 2-D Fourier transformation is equation (6).

$$F(u, v) = \int_{-\infty}^{\infty} \int_{-\infty}^{\infty} f(x, y) e^{-j2\pi(xu + yv)} dx dy \tag{6}$$

Where x and y are spatial axis and u, v are frequency axis. A Fourier filter keeps lower frequencies and eliminates higher frequencies by applying $(u-c_1)^2 + (v-c_2)^2 < r^2$. The coordinate of center point of F(u,v) is (c_1, c_2) . The value r is the radius of the 2-D Fourier filter.

Results

After smoothing, the fuzzy index matrix I (512 × 512 pixels) was summed horizontally in rows and vertically in columns (Figure 1). If the FIM of right-hand and left-hand sides of the brain was asymmetric at the certain range, possible cerebral cortical malformation areas were located. Comparing an original MR image and the corresponding results of fuzzy index matrix I and square fragments allowed easy

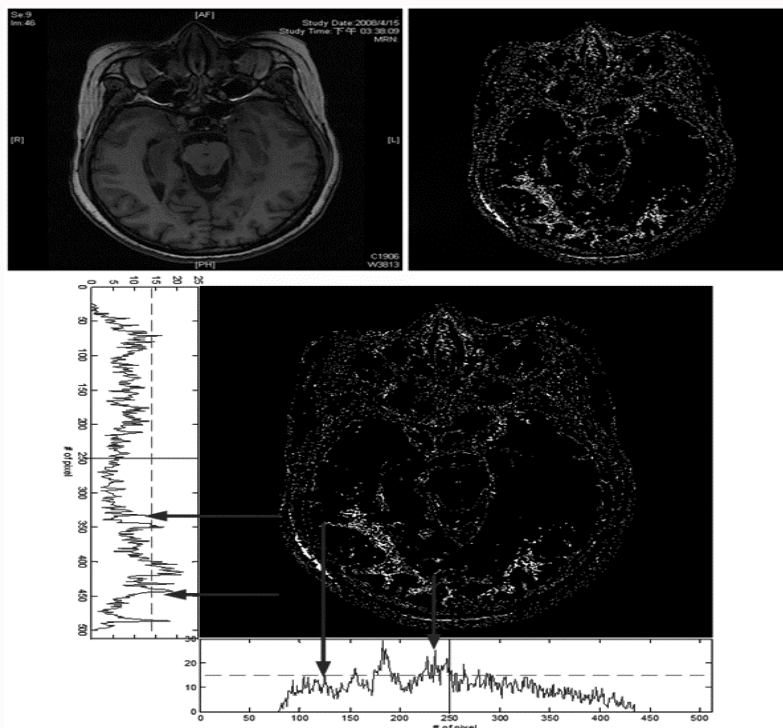


Figure 1: Left, top: the original MR image of the patient No. 1. Right, top: corresponding result of fuzzy index matrix I of the MR image. Bottom: Fuzzy elements were horizontally and vertically summed to locate the suspected areas of cerebral cortical malformation.

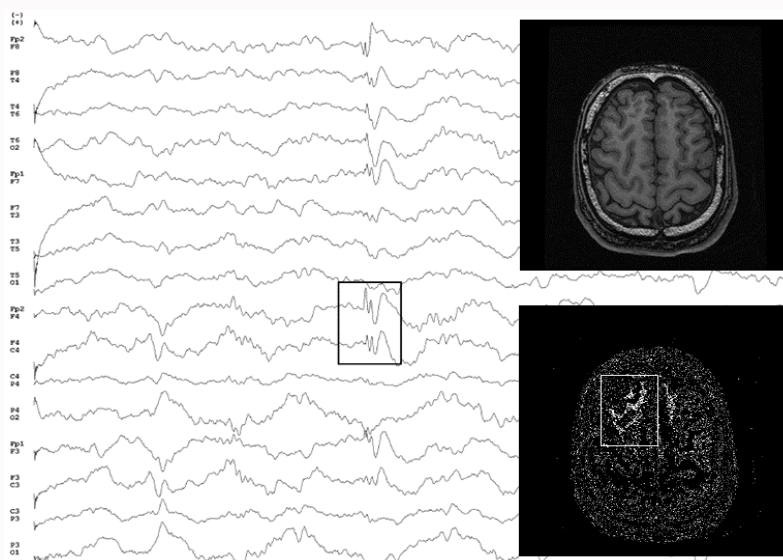


Figure 2: Left: a regular scalp EEG recording in a patient revealed the region with focal spikes, which was marked with a black square. Right, top: the original MR image of the patient. Right, bottom: the corresponding result of fuzzy index matrix I of the right top image. The results of FIM analysis (marked with the white square) matched the EEG findings and indicated possible cerebral cortical malformation with epileptogenicity over right frontal region.

assessment by noting that the sums of the fuzzy points had higher intensities than the background values in some regions (Figure 1). Additionally, since most of brain images are symmetric on a gross scale, the sum of all fuzzy points within a specific region may be compared to the corresponding region on the opposite side to further verify findings and avoid false alarms.

Analysis by FIM would enhance the regions of gray-white matter blurring, which increased the detection of cerebral cortical malformation (Figures 1 and 2). The higher intensity areas

demonstrated that image enhancement successfully identified the blurring regions of gray-white matter junctions. Though the MR images lacked any visible structural abnormalities, our FIM technique successfully identified five out of six cases with possible cerebral cortical malformations which corresponding to their seizure foci (Table 1).

Discussion

Our results revealed that seizure focus related to malformed cerebral cortical micro-structure can be successfully identified by

advanced MRI analyses. The identified regions of cerebral cortical malformations, though trivial on MR images, were highly concordant to the locations with focal epileptogenicity in EEG. The regions of focal spikes in EEG matched the result of the FIM analysis, though the tissue structure changes were not visible in regular MR images (Figure 2). When patients with epilepsy are examined by MRI, it is uncommon to observe visible cerebral cortical abnormalities in images, even when the MRI is assisted with positron-emission tomography or single-photon-emission computed-tomography [4,7,11]. Though MRI is capable of identifying the structural pathology underlying epileptic seizures or other diseases, a high percentage of abnormalities are both invisible to physicians and also time-consuming to re-inspect [4,6,12]. Additionally, visual assessments of abnormal tissue structures are limited as all micro-structure malformations cannot be found visually, especially those in the early stage of cerebral cortical malformations, where tissue structure changes may be extremely trivial on images.

Diagnosis of cerebral cortical malformation would be sometimes confirmed by surgical pathology study [12]. In histological structures, the brain tissue with cerebral cortical malformation contains enlarged, bizarre neurons with large nuclei, which are morphologically very different from normal neurons [12,13]. Even in patients with histological documentations, one third of them still had unremarkable findings by pre-surgical MRI exams [14]. If a structural malformation exists, whether which is observed or unobserved, the response to medical treatment will be predictably poorer and epilepsy surgery should be planned earlier [14,15]. Therefore, patients with epilepsy will benefit from early diagnosis of trivial cerebral cortical malformations by integrating MRI with our newly developed technique and EEG to define the seizure focus earlier as possible.

A recent report [7] described a patient with intractable epilepsy and a negative MRI since 2.5 years old. At the age of 3.5 years, the patient's EEG consistently depicted an area of irritation in accordance with de novo MRI findings, and, at age 6, a follow-up MRI finally revealed typical FCD findings over the right frontal lobe. This report informs us that current technologies are not good enough to detect cerebral cortical malformation as the seizure focus with regular MRI and analysis tools [16-18]. Our study results indicate that our technique can be an automated MRI screening tool for early detection of possible malformations of the cerebral cortical micro-structure that cannot be assessed with regular technologies currently.

Several newly developed technologies have been proposed to offer enhanced or intensified image signals for analysis. An enhanced visualization of blurred gray-white matter junctions in focal cortical dysplasia by voxel-based 3D MRI analysis used standard algorithms of statistical parametric mapping software (SPM99) with a T1-weighted MRI volume data. It was set to enhance the cerebral cortical malformation with comparing to a normal brain database [4]. Being different from that, our newly developed technique could be run for analysis without requiring a normal brain database to compare. The FIM of FCM would reveal the degrees of blurring of the gray-white matter junctions. Rather than purely enhancing the texture of an image, our MR image processing technologies could provide a window to observe micro-structure tissues with more details. It also provides a different way and information for future neuroimaging research to help diagnose early-stage brain diseases with MRI.

In conclusion, using fuzzy C-means index matrix based on modified FCM segmentation technologies can identify cerebral

cortical malformation or micro-disorganization. This technique can help physicians define possible seizure focus to plan epilepsy surgery adequately.

References

1. Palmini A, Najm I, Avanzini G, Babb T, Guerrini R, Foldvary-Schaefer N, et al. Terminology and classification of the cortical dysplasias. *Neurology*. 2004;62:S2-8.
2. Colombo N, Tassi L, Galli C, Citterio A, Lo Russo G, Scialfa G, et al. Focal cortical dysplasias: MR imaging, histopathologic, and clinical correlations in surgically treated patients with epilepsy. *Am J Neuroradiol*. 2003;24(4):724-33.
3. Wang VY, Chang EF, Barbaro NM. Focal cortical dysplasia: a review of pathological features, genetics, and surgical outcome. *Neurosurg Focus*. 2006;20(1):E7.
4. Huppertz HJ, Grimm C, Fauser S, Kassubek J, Mader I, Hochmuth A, et al. Enhanced visualization of blurred gray-white matter junctions in focal cortical dysplasia by voxel-based 3D MRI analysis. *Epilepsy Res*. 2005;67(1-2):35-50.
5. Sisodiya SM, Free SL, Stevens JM, Fish DR, Shorvon SD. Widespread cerebral structural changes in patients with cortical dysgenesis and epilepsy. *Brain*. 1995;118(4):1039-50.
6. Webster JG. *Medical Instrumentation- Application and Design*. New York: John Wiley & Sons; 1998. p. 518-77.
7. Yoshida F, Morioka T, Hashiguchi K, Miyagi Y, Nagata S, Yamaguchi Y, et al. Appearance of focal cortical dysplasia on serial MRI after maturation of myelination. *Childs Nerv Syst*. 2008;24(2):269-73.
8. Colliot O, Mansi T, Bernasconi N, Naessens V, Klironomos D, Bernasconi A. Segmentation of focal cortical dysplasia lesions on MRI using level set evolution. *Neuroimage*. 2006;32(4):1621-30.
9. Shen TW, Tseng P, Hsin YL. Fuzzy analysis on MRI image for focal cortical dysplasia (FCD) pre-screening. *Epilepsia*. 2007;48:165-6.
10. Shen S, Sandham W, Granat M, Sterr A. MRI fuzzy segmentation of brain tissue using neighborhood attraction with neural-network optimization. *IEEE Trans Inf Technol Biomed*. 2005;9(3):459-67.
11. Ruggieri PM, Najm I, Bronen R, Campos M, Cendes F, Duncan JS, et al. Neuroimaging of the cortical dysplasias. *Neurology*. 2004;62:S27-9.
12. Taylor DC, Falconer MA, Bruton CJ, Corsellis JA. Focal dysplasia of the cerebral cortex in epilepsy. *J Neurol Neurosurg Psychiatry*. 1971;34(4):369-87.
13. Hildebrandt M, Pieper T, Winkler P, Kolodziejczyk D, Holthausen H, Blümcke I. Neuropathological spectrum of cortical dysplasia in children with severe focal epilepsies. *Acta Neuropathol*. 2005;110(1):1-11.
14. Tassi L, Colombo N, Garbelli R, Francione S, Lo Russo G, Mai R, et al. Focal cortical dysplasia: neuropathological subtypes, EEG, neuroimaging and surgical outcome. *Brain*. 2002;125(8):1719-32.
15. Hong SC, Kang KS, Seo DW, Hong SB, Lee M, Nam DH, et al. Surgical treatment of intractable epilepsy accompanying cortical dysplasia. *J Neurosurg*. 2000;93(5):766-73.
16. Berge FP, Falcao AX, Yasuda CL, Cendes F. FCD segmentation using texture asymmetry of MR-T1 images of the brain. *Proceedings of 5th IEEE International Symposium on Biomedical Imaging: From Nano to Macro*. 2008; p. 424-7.
17. Besson P, Colliot O, Evans A, Bernasconi A. Automatic detection of subtle focal cortical dysplasia using surface-based features on MRI. *Proceedings of 5th IEEE International Symposium on Biomedical Imaging: From Nano to Macro*. 2008; p. 1633-6.
18. Colliot O, Mansi T, Besson P, Bernasconi N, Bernasconi A. Improved segmentation of focal cortical dysplasia lesions on MRI using expansion towards cortical boundaries. *Proceedings of 3rd IEEE International Symposium on Biomedical Imaging Nano to Macro*. 2006; p. 323-6.