



Unmasking the Problem

Sofi Matot*

Department of Otolaryngology - Head and Neck Surgery, Galilee Medical Center, Israel

Clinical Image

A 73-year-old semi-recluse female presented to the emergency department with a distal humerus fracture. As dictated by the COVID-19 pandemic regulations, she had been wearing a surgical mask (Figure 1) throughout the orthopedic evaluation. A routine COVID swab was ordered for which the patient removed her mask (Figure 2). The lady reported that a small sore had been present for years on her left nasal vestibule, rapidly progressing throughout the past months. Since this all took place during the pandemic, she avoided medical attention. A head and neck consultant performed an urgent biopsy and computerized tomographic scan (Figure 3). An ophthalmologic assessment confirmed left eye blindness. The histological diagnosis was basal cell carcinoma. Social distancing and lockdowns imposed by COVID regulations can apparently lead to postponement of medical attention and to otherwise avoidable devastating consequences. The fracture that led the patient to the hospital to begin with, was readily treated.

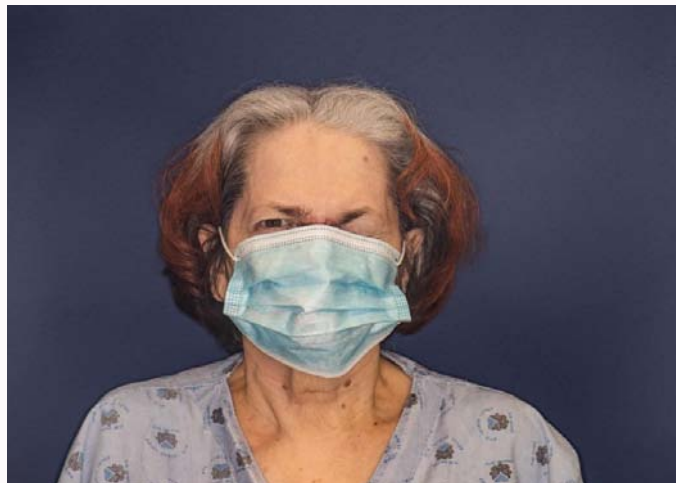

Figure 1:

OPEN ACCESS

***Correspondence:**

Sofi Matot, Department of
Otolaryngology - Head and Neck
Surgery, Galilee Medical Center,
Nahariya, Israel,

E-mail: sofimatot@gmail.com

Received Date: 10 Aug 2021

Accepted Date: 26 Aug 2021

Published Date: 30 Aug 2021

Citation:

Matot S. Unmasking the Problem. *Am J Otolaryngol Head Neck Surg.* 2021; 4(8): 1153.

Copyright © 2021 Sofi Matot. This is an open access article distributed under the Creative Commons Attribution License, which permits unrestricted use, distribution, and reproduction in any medium, provided the original work is properly cited.

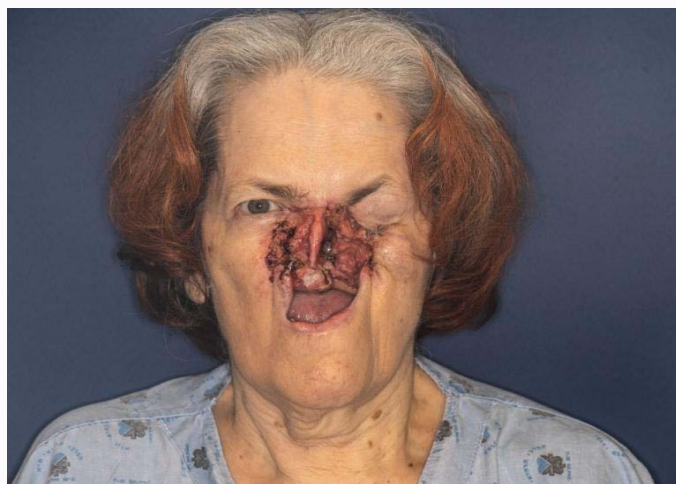


Figure 2:

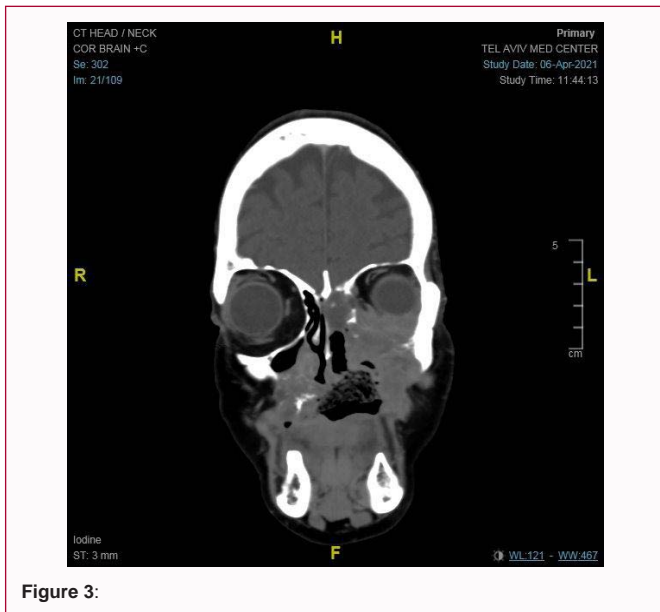


Figure 3: