



Type 4 Retro-aortic Left Renal Vein in a Kidney Donor: A Curse or a Blessing?

Gok A¹, Cimen S^{2*}, Cimen S¹, Atilgan KG³, Kahveci E⁴, Sandikci F¹ and Imamoglu A¹

¹Department of Urology, Ankara Diskapi Training and Research Hospital, Turkey

²Department of Surgery, Ankara Diskapi Training and Research Hospital, Turkey

³Department of Nephrology, Ankara Diskapi Training and Research Hospital, Turkey

⁴Department of Surgery, Turkey Organ Transplantation Foundation, Turkey

Abstract

Retro-aortic renal vein is a rare vascular variation of the left kidney. Since left kidney is preferred in the setting of live donor kidney transplantation, transplant surgeons must be familiar with this anomaly. Herein, a case of a kidney donor with type 4 retro-aortic left renal vein is presented. The laparoscopic donor nephrectomy procedure required a minor technical modification. Both donor and recipient procedures were performed successfully without any complications.

Keywords: Kidney donor; Type 4 retro-aortic left renal vein; Kidney transplantation

Introduction

Anatomical and topographical variations of the left renal vein have been investigated and expounded by anatomists but little emphasis has been placed by surgeons and radiologists on these variations until recently [1]. The location and anatomy of the reno-vascular pedicle is of great value during surgical procedures involving abdominal aorta, superior mesenteric and renal arteries, spleno-renal shunts, inferior vena cava surgeries and surgeries such as nephrectomy [1]. Additionally, these anatomical variations have a critical role during the selection process of donor candidates for renal transplantation, especially in the era of laparoscopic and robotic donor nephrectomy [1]. Failure to recognize or ignoring these anatomical variations may lead to fatal complications during these procedures [1].

The inferior vena cava is located at the right side of the midline; while the left renal vein typically runs anterior to the abdominal aorta and drains into inferior vena cava [2]. Therefore the left renal vein is approximately three times longer than its right counterpart. Considering this length advantage, transplant surgeons usually prefer the left kidney for donor nephrectomy [1]. This fact increases the clinical significance of the course of the left renal vein and its variations, particularly when live donors are involved.

Left renal vein passing behind the abdominal aorta is termed as a retro-aortic left renal vein and it is a relatively uncommon condition found in only 0.2% to 1.8% of the general population [2]. With recent advances in computed tomography and magnetic resonance imaging techniques, it is now easier to visualize the renovascular structures [1,2]. Therefore retro-aortic left renal vein and the type of this anatomical variation can be defined in detail. Recognition of these variations pre-operatively gives the surgeon the chance to be ready for any technical modifications and help avoidance from fatal intra-operative complications.

Herein we report a case of retro-aortic left renal vein anomaly found in a liver kidney donor who underwent laparoscopic left donor nephrectomy. We also describe how the surgical technique was modified to accommodate this rare anatomical variation.

Case Presentation

An 18-year-old male was admitted as a live kidney donor to his father. His father was diagnosed with End Stage Renal Disease (ESRD) secondary to hypertension and type 2 diabetes mellitus eight years ago and was on hemodialysis over the last five years. His past medical and surgical history was unremarkable. Physical examination findings and vital signs were all within normal limits. His body mass index was calculated as 25 kg/m². Laboratory study results including blood biochemistry profile,

OPEN ACCESS

*Correspondence:

Sanem Cimen, Department of Surgery,
Health Sciences University, Ankara
Diskapi Training and Research Hospital,
Organ Transplant Program, Ankara,
Turkey, Tel: 905055251473;
E-mail: gulersanem@yahoo.com

Received Date: 01 May 2018

Accepted Date: 03 Jul 2018

Published Date: 11 Jul 2018

Citation:

Gok A, Cimen S, Cimen S, Atilgan KG,
Kahveci E, Sandikci F, et al. Type 4
Retro-aortic Left Renal Vein in a Kidney
Donor: A Curse or a Blessing?. *Ann
Transplant Res.* 2018; 1(3): 1012.

Copyright © 2018 Cimen S. This is an
open access article distributed under
the Creative Commons Attribution
License, which permits unrestricted
use, distribution, and reproduction in
any medium, provided the original work
is properly cited.

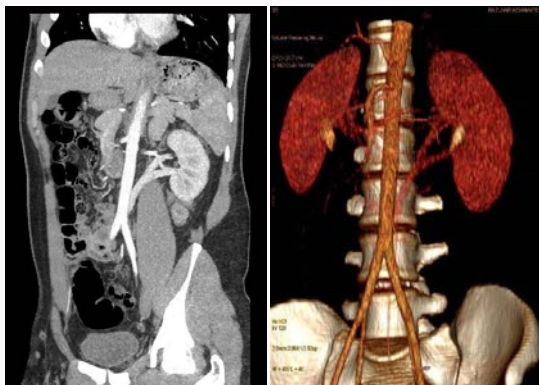


Figure 1: Spiral computerized tomography angiogram images of the retroaortic left renal vein.

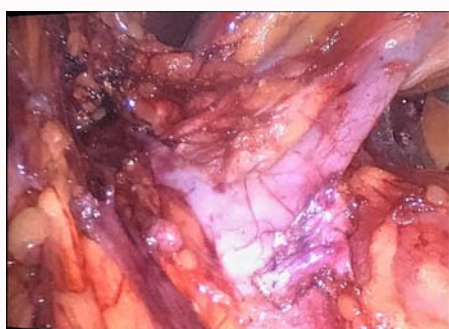


Figure 2: Intra-operative laparoscopic view of the retroaortic left renal vein.

complete blood count and urinalysis were all in the normal range. Standard pre-operative live kidney donor work-up was performed. Spiral CT angiography was carried out for the selection of kidney for donor nephrectomy (Figure 1). It showed a type 4 retro-aortic left renal vein which joined the left common iliac vein at the level of 4th Lumbar vertebra (L4). As an additional anatomical variation, two renal arteries were present at the right kidney. We selected the left kidney and proceeded with a laparoscopic left donor nephrectomy.

The patient was placed in a right decubitus position and a 10 mm trocar was introduced under direct vision. The abdomen was insufflated with CO₂ to 12 cm H₂O pressure. A 30° video endoscope and 2 additional trocars were introduced. Colon was mobilized and displaced medially. Mobilization of the colon exposed the retro-aortic left renal vein and its oblique course extending from L4 up to the renal hilum (Figure 2). As a modification of our original port placement planning, a 4th trocar was placed to the left lower quadrant medially for elevation of the kidney and introduction of endovascular staplers.

The surgical procedure continued with division of the lower pole renal fat. Subsequently, the ureter was identified and dissected. The gonadal vein was traced cephalad to the left renal vein and sealed at that level. For safe isolation of renal hilar structures in our usual technique renal vessels are dissected separately and encircled with vessel loops. However, in this particular case there was no need for encircling the renal vein since it was far away from the hilar structures and was providing enough tension to help dissect the artery. The 4th trocar placed at the left lower quadrant more medially than usual helped in elevation of the kidney for facilitating further dissection and introduction of endovascular staplers.

The rest of the surgery followed a similar course with our routine

laparoscopic donor nephrectomy procedures. A Pfannenstiel incision made to extract the kidney and an endo-bag was introduced to the abdomen. The ureter was clipped distally and divided while the renal artery and vein were divided using staplers. Finally, the kidney was extracted through the supra pubic incision and flushed with 4°C IGL-1 solution and stored in ice until transplantation. The operative time was 114 min and warm ischemia time was 4 min. There were no intra-operative complications. Estimated blood loss was 50 ml. Post-operative course was uneventful. He was discharged on postoperative day 4 with a serum creatinine level of 1.14.

Discussion

The number of people waiting for organ transplantation grows yearly; there is a significant scarcity of available organs for transplantation [1]. Liver donor organs offer the greatest opportunity for successful transplantation among all other donation types and constitute a re-emerging important source for kidneys since 1990's [3]. Factors such as steadily increasing wait times for deceased donor transplants, demonstration of survival benefits in liver transplants compared to deceased donor organ transplants and the implementation of minimal invasive surgical techniques in kidney donor surgeries paved the way for a significant increase in the numbers of liver donor kidney transplantation surgeries in the last 25 years [1].

The minimally invasive approach was demonstrated to lessen postoperative pain and shorten hospital stay compared to open donor nephrectomy [1,3]. Therefore, laparoscopic donor nephrectomy technique quickly gained support and has become the favored surgical approach [4]. It is generally accepted as a safe procedure with very low risk of morbidity and mortality [4]. Of note, any complication must be considered as harm to a healthy individual.

Left kidney is favored for laparoscopic donor nephrectomy because it provides a graft with a longer renal vein and artery compared to the right [4]. Additionally, there is increased risk of vasospasm and iatrogenic vascular injury during laparoscopic right donor nephrectomy as the right renal artery is located directly posterior to the renal vein [4]. Furthermore, some authors have reported a higher risk of vascular complications with eventual graft loss with laparoscopic right donor nephrectomy [5].

Selection of the left kidney due to these advantages may compel the surgeon to deal with renovascular anatomical variations at this side. Among these variations, circum-aortic and retro-aortic left renal vein possess a relatively higher risk of vascular injury and has previously been considered as a relative contraindication for donor nephrectomy by some authors [6].

These variations can occur as a consequence of the complex developmental process of the IVC and its branches [7]. The embryological development process starts at the fourth week of conception and ends at about the eighth week. The IVC is developed from a vast network of three pairs of parallel veins in communication: Posterior cardinal veins, sub-cardinal veins and supra-cardinal veins. The ventral portions of these veins persist to form the normal left renal vein. If the dorsal portion of this collar persists, a retro-aortic left renal vein develops.

Left retro-aortic renal vein anomalies are classified into four types (Figure 1) [2,7]. In type 1, the ventral pre-aortic limb persists and joins the IVC in the orthotopic position. Type 2 results from the obliteration

of the ventral pre-aortic limb of the left renal vein; the remaining dorsal limb turns into the retro-aortic left renal vein. The left renal vein lies at the level of L4-L5 and joins the gonadal and ascending lumbar veins before joining IVC. Type 3 is the circum-aortic left renal vein or venous collar. This type is formed due to the persistence of sub supracardinal; inter supracardinal venous anastomosis and the dorsal limb of the left renal vein. In type 4, the ventral pre-aortic limb of the left renal vein is obliterated and the remaining dorsal limb turns into the retro-aortic left renal vein. Subsequently, the retro-aortic left renal vein courses obliquely and caudally behind the aorta to join the left common iliac vein. The most common type is type 1 with a reported incidence of 0.3% to 1.9% and the least common variant is type 4 with an incidence of 0.1%.

Although rare, our case is not the first case of a donor with a retro-aortic renal vein who underwent a successful laparoscopic donor nephrectomy procedure. Deák et al. [8] reported a series of patients who had renovascular venous anomalies. Laparoscopic donor nephrectomy procedures were performed in this group of patients 6 of whom had a retro-aortic renal vein. However, these authors did not give any details regarding the type of the variation and the potential modifications in their surgical technique. On the other hand, they highlighted the importance of pre-operative renovascular imaging for safety of the surgical procedure.

Patil et al. [1] compared the outcomes of the laparoscopic donor nephrectomy procedures performed on donors who had normal renovascular anatomy to donors with retro-aortic veins at the selected side. These authors reported that they included 243 donors in this study; 13 of these donors (5.35%) had a retro-aortic or circum-aortic left renal vein. In contrast to Deák et al. [8], they categorized the variations they encountered and claimed that 7 of these patients had type 2, 4 had type 1 and 2 had type 3 (i.e. circum-aortic) retro-aortic left renal vein [1,8]. None of these donors had a type 4 anomaly. Patil et al. [1] stated that both the donor and recipient outcomes were similar between the cases with and without renovascular anomalies. They found selection of these kidneys safe, provided that a thorough pre-operative renovascular imaging has been performed.

Lin et al. [9] reported their experience regarding the donors with retro-aortic left renal vein whom underwent a left-sided laparoscopic donor nephrectomy. Among their 170 patients, 18 had either a circum-aortic (n=16) or a retro-aortic left renal vein (n=2). These authors did not give any details about the type of the retro-aortic vein however they stated that they performed a retroperitoneal laparoscopic donor nephrectomy in the setting of retro-aortic left renal vein. Transperitoneal laparoscopic approach was performed in the patients with either circum-aortic veins or normal renovascular anatomy. In line with Patil et al. [1] they compared the outcomes of patients with circum-aortic or retro-aortic vein to the patients with normal vascular anatomy and concluded that the results were similar.

Mandal et al. [10] studied on 227 donors 17 (7.5%) of whom had either circum-aortic or retro-aortic left renal vein. They did not compare donor and recipient outcomes however there were no vascular complications in the setting of left renal grafts with venous anomalies. These authors did not give any details regarding the types of the retro-aortic vein.

In our case, we encountered a type 4 retro-aortic left renal vein which had an abnormal course posterior to the aorta and was draining directly into the left common iliac vein. This variation actually led to the easier exposure of the hilar anatomy and a quicker approach with a minor modification to our routine surgical technique: We did not have to stretch across the abdominal aorta immediately antero-inferior to the renal artery; retro-aortic vein facilitated the visualization of the origin of the renal artery by not blocking the surgical view. In addition, the operative time and warm ischemia time were not prolonged. Estimated blood loss was unremarkable and the donor was discharged on postoperative day 3 without any complications. The recipient underwent an uneventful renal transplantation procedure. He had immediate graft function and he was discharged with a creatinine level of 1.06 mg/dl.

Conclusion

In conclusion, presence of a type 4 retro-aortic left renal vein should not be considered as a contraindication for laparoscopic donor nephrectomy. This variation which can lead to fatal bleeding if pre-operatively unrecognized- can even facilitate the hilar exposure as long as the surgical team is prepared for a minor modification in their surgical technique.

References

1. Patil AB, Javali TD, Nagaraj HK, Babu SMLP, Nayak A. Laparoscopic donor nephrectomy in unusual venous anatomy- donor and recipient implications. *Int Braz J Urol.* 2017;43(4):671-8.
2. Hsieh CL, Tiao WM, Chou YH, Tiu CM. Retroaortic left renal vein: Three case reports. *JMU.* 2012;20(2):115-8.
3. Ratner LE, Ciseck LJ, Moore RG, Cigarroa FG, Kaufman HS, Kavoussi LR. Laparoscopic live donor nephrectomy. *Transplantation.* 1995;60(9):1047-9.
4. Jacobs SC, Cho E, Dunkin BJ, Flowers JL, Schweitzer E, Cangro C, et al. Laparoscopic live donor nephrectomy: The University of Maryland 3-year experience. *J Urol.* 2000;164(5):1494-9.
5. Leventhal JR, Kocak B, Salvalaggio PR, Koffron AJ, Baker TB, Kaufman DB, et al. Laparoscopic donor nephrectomy 1997 to 2003: Lessons learned with 500 cases at a single institution. *Surgery.* 2004;136(4):881-90.
6. Walker TG, Geller SC, Delmonico FL, Waltman AC, Athanasoulis CA. Donor renal angiography: Its influence on the decision to use the right or left kidney. *AJR.* 1988;151(6):1149-51.
7. Fluckiger TA, Eapen AS, Bhattal GK, Joy AR. Retroaortic left renal vein- developmental and clinical implications. *Int J Anat Var.* 2016;9:13-7.
8. Deák PA, Doros A, Lovró Z, Toronyi E, Kovács JB, Végső G, et al. The significance of the circum-aortic left renal vein and other venous variations in laparoscopic living donor nephrectomies. *Transplant Proc.* 2011;43(4):1230-2.
9. Lin CH, Steinberg AP, Ramani AP, Abreu SC, Desai MM, Kaouk J, et al. Laparoscopic live donor in the presence of circum-aortic or retroaortic left renal vein. *J Urol.* 2004;171:44-6.
10. Mandal AK, Cohen C, Montgomery RA, Kavoussi LR, Ratner LE. Should the indications for laparoscopic live donor nephrectomy of the right kidney be the same as for the open procedure? Anomalous left renal vasculature is not a contraindication to laparoscopic left donor nephrectomy. *Transplantation.* 2001;71(5):660-4.