



Treatment of Large Cutaneous Defects of the Scalp by Vacuum-Assisted Wound Dressing

Bast F¹, Chadha P², Jakharia-Shah N^{3*} and Collier J⁴

¹Department for Otorhinolaryngology, AMEOS Klinikum Haldensleben, Haldensleben, Germany

²Department of Plastic Surgery, St Thomas' Hospital, UK

³King's College London, School of Medicine, London, UK

⁴Chelsea and Westminster Hospital, Craniofacial Unit, London, UK

Abstract

Introduction: Large cutaneous defects of the forehead and scalp, which can extend down to the bone, often present significant reconstructive challenges. In some patients, lack of local tissue elasticity in these areas precludes closure with simple flaps, while multi-stage tissue expansion or free tissue transfer may be limited by patient age and co-morbidities. Grafting onto bare bone must be preceded by procedures to stimulate granulation tissue, usually by drilling of the outer table. Wound healing is a long-term process requiring multiple dressing changes and the cosmetic result is often considered to be suboptimal. Vacuum assisted wound closure is well established in the management of complex or chronic wounds. However, its use for full thickness grafting on the scalp has not been well described. The aim of this article is to describe our experience with this technique and explore our perceived advantages and disadvantages of this method.

Material and Methods: We retrospectively analysed two patients with large skin defects on the forehead and scalp, created after full clearance of Basal Cell Carcinomas (BCC). All wounds were successfully closed after excision through the use of vacuum assisted closure (VAC) devices. Clinical assessments of the wounds were undertaken on a regular basis to assess progress.

Results: After 3 weeks of VAC dressing changes, undertaken in the outpatient department, the entire wound of both patients contained viable granulation tissue. Closure using a full-thickness skin graft was undertaken successfully. The VAC system was applied again at the end of the surgery and removed one week postoperatively. No wound healing problems occurred. 7 weeks after the initial BCC excision, all wounds were completely closed, the scalps were covered with viable skin grafts and the aesthetic results were deemed very satisfactory by the patients themselves.

Discussion: The VAC system can be used for the treatment of larger defects in the scalp area, where direct closure can often be problematic for a variety of reasons. In our experience, it is easy to use and well tolerated by patients. Wound healing can be expedited with minimal morbidity and the technique can also be cost effective.

Keywords: Negative-pressure; Wound closure; Wound treatment; Vacuum suction devices; Scalp defects; Vacuum assisted wound closure

Introduction

Large cutaneous defects on the forehead and scalp, independent of pathogenic cause, are often not treatable with a primary wound closure due to a lack of skin elasticity in this anatomical area. Traditional reconstruction methods include full-thickness skin grafts, local pedicle flaps such as transpositional and rotational flaps, skin implants and tissue expanders with subsequent wound closure, in addition to the use of free flaps. However, these methods have their disadvantages. Skin grafts are often a poor colour and thickness match and adjacent tissue transfer may distort important nearby structures. Tissue expanders require a stabilized wound bed before expansion can be considered and create morbidity associated with the prolonged expansion process. Free tissue transfers are long procedures that often result in inappropriate tissue thickness and colour matching [1-5].

Even when a wound closure is initially successful, for example with a local flap, problems can arise during the healing process due to skin tension in the area. As a result, the wound must be

OPEN ACCESS

*Correspondence:

Nihull Jakharia-Shah, King's College London, School of Medicine, 53 Sedgcombe Avenue, Kenton, London-HA3 0HW, Tel: 07739397198; E-mail: nihullshah@hotmail.com

Received Date: 03 Jul 2017

Accepted Date: 29 Aug 2017

Published Date: 01 Sep 2017

Citation:

Bast F, Chadha P, Jakharia-Shah N, Collier J. Treatment of Large Cutaneous Defects of the Scalp by Vacuum-Assisted Wound Dressing. *Ann Clin Otolaryngol.* 2017; 2(3): 1020.

Copyright © 2017 Jakharia-Shah N. This is an open access article distributed under the Creative Commons Attribution License, which permits unrestricted use, distribution, and reproduction in any medium, provided the original work is properly cited.

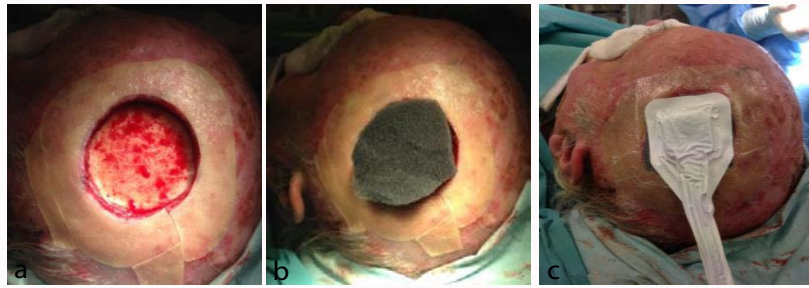


Figure 1: (A) Defect after total excision of a BCC, (B) Application of DuoDERM (C) Sponge drainage tube.

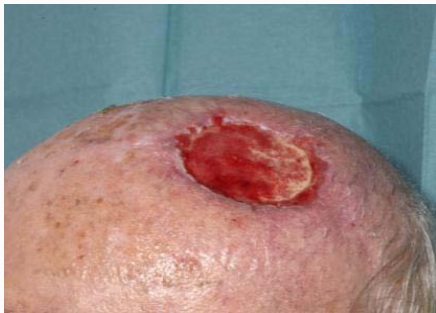

Figure 2: After 3 weeks' V.A.C therapy, wound base completely filled with vital granulation tissue, ready for transplant.

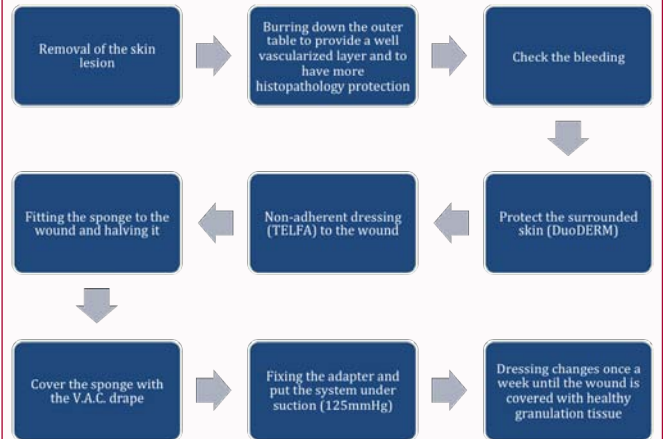


Table 1: Step-by-step recipe for the VAC dressing on the scalp and forehead.

treated regularly with secondary therapies or ultimately, with a full thickness skin graft. Skin defects on the forehead or scalp in older patients are usually post-traumatic or post-operative in origin. With large post-operative scalp defects, for example following removal of a large Basal Cell Carcinoma (BCC), the goal is secondary wound healing and subsequently a full thickness skin graft. Grafting directly on to bone must be preceded by procedures to stimulate granulation tissue, usually by drilling of the outer table. The healing process in such cases is often protracted, requiring multiple dressing changes and the cosmetic result is usually considered to be sub-optimal [5,6].

Since the end of the 1980's, experience with and studies on Vacuum-Assisted wound Closure (VAC) therapy on humans has increased. The principle of VAC is based on a wound sponge applied to the entire surface of the wound and fixed in place with an occlusive film dressing. A vacuum system is then connected to the wound cavity with a non-collapsible tube, which produces negative pressure over the wound. In the early 1990's, the plastic surgeon Michael Moryk and his team developed a therapy system with an electric vacuum pump. Compared to conventional drainage systems it has the advantage of allowing the strength of the vacuum to be precisely adjusted and controlled. In addition, it has a removable wound secretion container and an alarm that sounds when complications arise. Since then, VAC has become well established in the management of complex or chronic wounds. It works by increasing local blood flow up to four-fold and doubling the rate of angiogenesis whilst effectively reducing wound oedema and enhancing wound contraction. The process also aids with the development of new granulation tissue, reduces bacterial colonization and creates an appropriately moist wound environment. Thus, stimulation of granulation tissue can occur and an ideal, moist wound environment is created, even in poorly vascularized areas such as over tendons, bones and metal implants. An additional specific property of the equipment is its ability to act as an effective skin graft splint over irregular surfaces [1,2,7-11].

Since its introduction, the therapy has gained wide acceptance for many clinical conditions. The past decade has also been witness to an expanding role for negative pressure therapy in complex head and neck wounds and defects. However, its use prior to scalp grafting has not been well described [3,4].

The cases reported here describe the closure of large forehead or scalp defects using VAC therapy followed by coverage with a full thickness skin graft. These examples highlight a potentially new clinical application of VAC therapy in specific areas of the body. The benefits and short-falls seen in the cases shall be documented and evaluated in the hope that the treatment be used frequently and universally for similar cases.

Case Presentation

The first patient case describes an 83-year-old male who developed a large basal cell carcinoma on the scalp. This was excised down to bone for adequate clearance. Before application of the vacuum dressing, the sponge was cut to size and halved in depth due to the shallow nature of the wound. Strips of DuoDERM (DuoDERM; ConvaTec, United Kingdom) skin dressing were applied to the edges of the wound in order to protect the patient from over-granulation.

The transparent Tagoderm film was carefully positioned to only cover the sides of the sponge. After cutting a small area in the film approximately in the middle of the sponge, the drainage tube was attached and special attention was given to the caudal placement of the tube, in an effort to cause minimal disturbance and interference with the patient on a daily basis (Figure 1A-C). The suction pressure was set at 125mmHg, continuous. The dressing was left in place for a period of 3 weeks and changed once weekly thereafter. After this

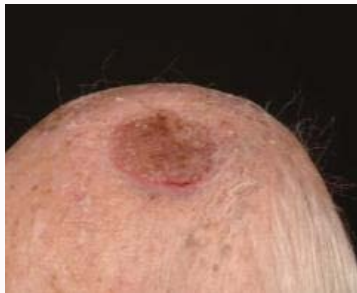

Figure 3: 7 weeks after BCC removal and three weeks after full thickness skin grafting.

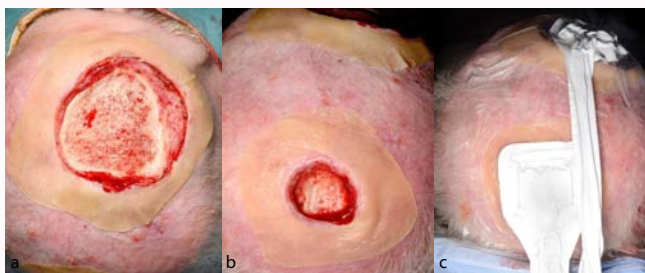


Figure 4: (A-C) Two defects on the scalp after resection and application of the V.A.C. -dressing, y-connector and one suction device.

period of time, the wound base was completely colonised with vital granulation tissue, suitable for grafting (Figure 2) and we covered the defect with a full-thickness skin graft from the groin. A VAC dressing was also applied over the graft for a period of 7 days postoperatively at a setting of 125 mmHg, intermittent pressure. All dressing changes were undertaken thereafter in the outpatient setting in our dressing clinic (Table 1).

After removal of the VAC dressing, no other measures were necessary to promote wound healing and no disruptions occurred during the postoperative healing process. Seven weeks after BCC removal, the wound appeared dry and well healed. The initial wound was covered completely with viable skin, and the aesthetic result was very satisfactory (Figure 3).

The second case was that of a 79-year old patient with two basal cell carcinomas on the scalp, both of which required excision down to bone for full clearance. The resulting defects were 4 cm and 9 cm in diameter and two VAC dressings were applied, one to each wound, as described in the first case (Table 1). The dressings were connected to the same suction device through the use of a Y-connector (Figure 4A-C). After 3 weeks of negative pressure and regular wound dressing changes, the smaller defect was small enough not to require a graft for closure. A full thickness skin graft from the supraclavicular region was applied to the larger defect and 4 weeks after grafting, the wound was completely healed.

Discussion

Large skin defects on the forehead and scalp, independent of cause, are often not treatable with primary wound closure, since the skin in this area lacks sufficient elasticity. Secondary wound healing can often be protracted and is preceded by procedures to stimulate granulation tissue such as drilling of the outer table. In order to accelerate this process and to simplify the defect closure by means of a full thickness skin graft, we have used vacuum-assisted wound

therapy. Its use is decided on an individual case basis for each patient. If primary wound closure is possible, especially with a local pedicle flap such as a transposition and rotational flap, or with implantations of skin and tissue expanders with subsequent wound closure, this option is preferable [5,6].

We propose using VAC therapy as an alternative treatment option for reconstruction of large forehead and scalp defects. The efficacy of VAC therapy has been demonstrated in both animal-based studies and, more recently, in a large patient population. Vacuum sealing promotes the necessary conditions for successful wound healing: cleansing of the wound through reduction of bacterial colonisation; reduction of wound oedema; improved blood circulation; enhanced wound contraction; acceleration of the granulation phase and promotion of a moist wound environment. This activates the stimulation of granulation tissue formation in an ideal, moist wound environment even over bradytrophic tissues such as tendons, bones and metal or plastic implants. The therapy can be widely applied, in general surgery as well as plastic, vascular and orthopaedic surgery. In 2004 the first description of defect coverage in the forehead area using vacuum-assisted wound therapy appeared, but since then this therapy has rarely shown up in the literature as the primary reconstructive modality of forehead or scalp defects [1-4,7,10-12].

The contraindications for VAC -therapy should be considered. All malignant wounds are contraindicated as tumour growth can be accelerated by vacuum therapy. However, VAC can be used after the successful, complete excision of malignant tissue, as in the cases described. Additionally, osteomyelitis is a known contraindication. If present, the infection must first be treated with antibiotics and necrotic bone must be removed. If the patient is suffering from tissue necrosis, the necrotic tissue must be surgically debrided prior to further treatment. Vacuum therapy cannot dissolve such tissue, therefore, it risks encouraging the colonisation of bacteria in the wound. Fistulae, open blood vessels and active bleeding are examples of relative contraindications. In these cases it is necessary to observe the secretions and wounds carefully and to adjust the suction strength appropriately.

If the patient fulfils the criteria for vacuum-assisted wound therapy, we apply DuoDERM (ConvaTec, United Kingdom) to the surrounding skin edges of the wound. The wound sponge can then be prepared and the VAC-system (Smith&Nephew, United Kingdom) connected. All of our patients received a portable vacuum pump and for smaller defects we used the PICO pump system (Smith&Nephew, United Kingdom), which makes the handling more convenient for the patient.

In our 2 cases, the formation of healthy granulation tissue appeared after 3 weeks over bare bone. In addition, the wound size was reduced due to the negative pressure applied. This makes the closure with a full thickness skin graft easier and the donor site is smaller which subsequently reduces the patient's postoperative discomfort and prevents restricted mobility, especially in elderly patients. With a y-connector, two defects can be treated simultaneously with one suction device (Figure 4).

Although no serious complications were encountered in this study, patients did experience some minor pain with dressing changes. To reduce the discomfort the negative pressure was turned off 30 minutes prior to removal of the dressing and the sponge was filled with warm saline solution through the drainage tube. This

Table 2: Estimated costs of the V.A.C.-therapy and secondary wound healing.

	V.A.C.-dressing	Conservative wound dressing
Average number of visits at the dressing clinic until defect can be closed with a skin graft	6	Min. 15, if patient is able to do the dressing changes from a certain date at home
Material needed and costs per visit at the dressing clinic	Medium foam with connection tube 26£ 300ml Canister for portable pump 22£	Special plaster 2£
Pump rental costs	25£ per month (special hospital rate)	Not needed
Charged cost per visit at the dressing clinic	109£	109£
Average costs per visit in total	165£	111£
Average costs until defect can be closed with a skin graft	990£ after 6 visits	1665£ after 15 visits
Payback	After 9 visits at the dressing clinic, V.A.C.-dressing is cheaper than conservative wound dressing	

allows for gentle removal of the dressing with minimal pain [2]. In our patient cohort, wound healing has been significantly accelerated through the use of vacuum assisted closure, which has resulted in a better quality of life for the patients. In addition, costs have been reduced through shorter hospital stays and fewer outpatient-dressing changes. 7 weeks after BCC resection the aesthetic result was very satisfactory (Figure 3).

From an economical point of view, the application of vacuum assisted wound therapy is cost effective. Although a vacuum pump for each patient must be rented from the company and the dressing material is often expensive, the cost of the VAC-dressing is ameliorated after the ninth dressing change (versus conservative wound management) at the hospital. In our previous experiences without the use of the VAC-devices in cases with exposed bone, even in much smaller defects, at least 15 follow-up appointments have been required until the wound bed was lined with viable granulation tissue. Due to the significantly accelerated growth of granulation tissue in the context of vacuum assisted wound therapy, personnel costs could be drastically reduced. As we have

Studied mostly older and multimorbid patients, additional costs arise simply through attendance to and from hospital e.g. transport costs (Table 2). Thus, these would also be significantly reduced by using VAC therapies.

Conclusion

The VAC system for the treatment of larger defects in the head area is, in our experience, easy to use and well tolerated by the patient. Wound healing was expedited with minimal morbidity, faster healing rates, better aesthetic results and significant cost-savings. This treatment option should be added to the surgical armamentarium of surgeons working in this area as a superior and more sustainable method of scalp wound management.

Ethics

This retrospective review was undertaken with the verbal and written consent of each patient for their case to be published. High ethical standards including data protection were adhered to throughout.

Acknowledgements

Medical Illustration Department, Chelsea and Westminster Hospital, London.

References

1. Palm HG, Hauer T, Simon C, Willy C. [Vacuum-assisted closure of head and neck wounds]. *HNO*. 2011;59(8):819-30.
2. Baisch A, Hörmann K, Goessler UR, Sauter A, Riedel F. [Vacuum-assisted closure of nonhealing wounds in head and neck reconstructive surgery]. *HNO*. 2007;55(5):392-8.
3. Hsia JC, Moe KS. Vacuum-assisted closure therapy for reconstruction of soft-tissue forehead defects. *Arch Facial Plas Surg*. 2011;13(4):278-82.
4. Powers AK, Neal MT, Argenta LC, Wilson JA, DeFranzo AJ, Tatter SB. Vacuum-assisted closure for complex cranial wounds involving the loss of dura mater. *J Neurosurg*. 2013;118(2):302-8.
5. Kruse-Losler B, Presser D, Meyer U, Schul C, Luger T, Joos U. Reconstruction of large defects on the scalp and forehead as an interdisciplinary challenge: experience in the management of 39 cases. *European journal of surgical oncology. The journal of the European Society of Surgical Oncology and the British Association of Surgical Oncology*. 2006;32(9):1006-14.
6. Lasheen AE, Saad K, Raslan M. External tissue expansion in head and neck reconstruction. *Journal of plastic, reconstructive & aesthetic surgery. JPRAS*. 2009;62(8):e251-4.
7. Bovill E, Banwell PE, Teot L, Eriksson E, Song C, Mahoney J, et al. Topical negative pressure wound therapy: a review of its role and guidelines for its use in the management of acute wounds. *Int Wound J*. 2008;5(4):511-29.
8. Kairinos N, Hudson D, Solomons M. Depth of penetration of negative pressure wound therapy into underlying tissues. *Wound repair and regeneration : official publication of the Wound Healing Society [and] the European Tissue Repair Society*. 2009;17(3):456.
9. Kairinos N, Solomons M, Hudson DA. The paradox of negative pressure wound therapy--in vitro studies. *Journal of plastic, reconstructive & aesthetic surgery. JPRAS*. 2010;63(1):174-9.
10. Kairinos N, Solomons M, Hudson DA. Negative-pressure wound therapy I: the paradox of negative-pressure wound therapy. *Plast Reconstr Surg*. 2009;123(2):589-98; discussion 99-600.
11. Kairinos N, Voogd AM, Botha PH, Kotze T, Kahn D, Hudson DA, et al. Negative-pressure wound therapy II: negative-pressure wound therapy and increased perfusion. Just an illusion? *Plast Reconstr Surg*. 2009;123(2):601-12.
12. Marathe US, Sniezek JC. Use of the vacuum-assisted closure device in enhancing closure of a massive skull defect. *Laryngoscope*. 2004;114(6):961-4.