World Journal of Physical and Rehabilitation Medicine

Research Article
Published: 27 Aug, 2020

The Immediate Effect of High-Intensity Laser Therapy on Pain Relief and Shoulder Function in Patients with Subacromial Impingement Syndrome

*Yan-Wen Chen[1], Yuan-Yang Cheng[1,2,3], Yuchun Lee[1] and Shin-Tsu Chang[1,4,5]**

[1]Department of Physical Medicine and Rehabilitation, Taichung Veterans General Hospital, Taiwan

[2]Center for Geriatrics and Gerontology, Taichung Veterans General Hospital, Taiwan

[3]School of Medicine, National Yang-Ming University, Taiwan

[4]Department of Physical Medicine and Rehabilitation, Tri-Service General Hospital, School of Medicine, National Defense Medical Center, Taiwan

[5]Department of Medicine, Chung Shan Medical University, Taiwan

Abstract

Background: Subacromial Impingement Syndrome (SAIS) is a very common and prevalent disorder worldwide. Laser therapy has been used in the treatment of SAIS while very limited studies have assessed the immediate effects of High-Intensity Laser Therapy (HILT) on SAIS.

Objectives: This study aimed to evaluate the immediate effects of HILT on patients with SAIS.

Methods: Twenty patients with SAIS were enrolled in this study between May and November 2019. All participants were clinically diagnosed with SAIS. They received one session of HILT. Visual Analogue Scale (VAS), shoulder Range of Motion (ROM) in flexion, and Constant-Murley Scale (CMS) were assessed before and immediately after intervention.

Results: In this retrospective study, at the end of the study program, comparisons before and after treatment in the HILT group showed significant improvements in all outcome measures, including VAS, shoulder ROM, and CMS ($P<0.05$).

Conclusion: HILT can immediately reduce pain and disability and improve shoulder flexion ROM in patients with SAIS.

Keywords: Subacromial impingement syndrome; Shoulder impingement syndrome; Shoulder pain; High-intensity laser therapy; High power laser therapy; Shoulder flexion; Visual analogue scale; Constant-murley scale, Subacromial injection test

OPEN ACCESS

Correspondence:
Shin-Tsu Chang, Department of Physical Medicine and Rehabilitation, Taichung Veterans General Hospital, No.161, Sec. 6, Minquan East Road, Neihu District, Taipei 11490, Taiwan, Tel: 886-935-605578; E-mail: ccdivlaser1959@gmail.com

Received Date: *19 Jul 2020*
Accepted Date*: 25 Aug 2020*
Published Date*: 27 Aug 2020*

Citation:
Chen Y-W, Cheng Y-Y, Lee Y, Chang S-T. The Immediate Effect of High-Intensity Laser Therapy on Pain Relief and Shoulder Function in Patients with Subacromial Impingement Syndrome. World J Phys Rehabil Med. 2020; 4(1): 1016.

Introduction

Shoulder pain is one of the most common sites of musculoskeletal pain in the adult population. Its incidence ranges between 6.6 to 25 per 1000 people in various studies and Subacromial Impingement Syndrome (SAIS) has been reported to be one of the most frequent etiologic factors for shoulder pain, particularly in those with repeated loading during elevation of the arm above 90 degree [1]. The condition progresses to adhesive capsulitis if left untreated. SAIS can lead to a decrease in the function of this joint, and its risk factors include acromion morphology, weak rotator cuff, abnormal kinetic patterns of scapular muscles, capsular abnormalities, poor posture, repeated loading of an arm, and overuse [2]. The goals for treatment of SAIS are to relieve pain and reduce inflammation, reinstate non-painful Range of Motion (ROM), and improve shoulder function [3]. Basic rehabilitation therapy of SAIS includes a period of relative rest, eliminating any activity that may cause an increase in symptoms. Interferential current therapy, ultrasound diathermy, magnetic field therapy, laser phototherapy, extracorporeal shock wave therapy, and transcutaneous electrical nerve stimulation are used as complementary physical modalities [4-7]. Cryotherapy and exercise (Codman's pendulum exercises and symptom limited, active, assisted ROM exercises) have been shown to relieve pain and recover function significantly [8]. Some studies have reported exercise as more effective than placebo both in the short term and midterm (moderate evidence) [9]. A conservative approach comprising non-steroid anti-inflammatory drugs, subacromial injections,

exercise, and several physical therapy agents is recommended as the first step treatment for SAIS [10,11].

High-Intensity Laser Therapy (HILT) is a new laser therapy modality that has been implemented in recent years. HILT is a promising laser treatment application. This modality is convenient, non-invasive, and painless, achieves mobility of outsized area on the surface of the body, stimulates deep tissue efficiently, and can be combined with anti-inflammation, anti-pain, and detumescence influences [12,13]. There are many kinds of HILT devices, and all of these curative methods are painless and non-invasive. High pain level can be reduced using pulsed HILT, which exhibits anti-inflammatory, anti-edematous, and analgesic effects for patients with pain [14].

A number of studies have evaluated short-term (14 to 15 days) and long-term (2 to 6 months) effects of HILT [12,14-17], but to date no studies have been conducted to evaluate the immediate effects. Thus, the aim of this study was to investigate the immediate effects of HILT on pain relief and shoulder function in patients with SAIS.

Materials and Methods

Subjects

In 2019, we started using a HILT machine for teaching and practicing purposes. The aim was to teach our students/interns how to use it for treatment of our patients and to assess pain control.

All baseline and post-treatment evaluations were done by a senior professional staff. All SAIS patients were referred to the rehabilitation OPD between April and November 2019. The inclusion criteria were: a) history of SAIS lasting more than 3 months; b) over 25 years of age.

The diagnosis of SAIS was made if Subacromial Injection Test (SIT) and shoulder impingement tests (Neer and Hawkins-Kennedy) were positive [18,19]. Regarding the SIT procedure, two percent 5 cc of lidocaine was injected using a 21 G/5 mL needle into the subacromial space just under the acromion using the anterior approach by the same physiatrist. A positive reaction was determined by 80% or more post-injection reduction in pain score and improvement in passive and/or active ROM after the injection.

The exclusion criteria were as follows: 1) concomitant shoulder pathologies such as adhesive capsulitis, calcific tendinitis, full-thickness tears of the rotator cuff, osteoarthritis of the acromioclavicular joint, dislocations or acute traumatic conditions; 2) prior applications of physiotherapy and injection of hyaluronic acid and/or corticosteroid during the preceding 3 months; 3) prior shoulder surgery; 4) acute infection; 5) malignancy; 6) neurologic motor and/or sensory deficiency in the upper extremity; 7) pregnancy; 8) inflammatory disease; and 9) cardiac pacemaker.

Initial assessment

Assessment of severity of shoulder pain was performed using Visual Analogue Scale (VAS), shoulder flexion ROM, and Constant-Murley Scale (CMS). All participants were evaluated before treatment and immediately after treatment. Demographic data, onset, and duration of complaints, were recorded at the baseline assessment. VAS, ROM, and CMS were also included.

Visual analogue scale (VAS)

Scores were recorded by making a handwritten mark on a 10-cm line representing a continuum from "no pain" (score of 0) to "worst pain" (score of 10)". The far left end received a 0 score, indicating no pain, while the right end was a score of 10, representing severe pain. VAS was utilized to assess degree of the lumbosacral pain, and radiating pain in the lower limb. VAS scores (0, no pain; 10, worst pain ever) was used to quantify the pain level during rest, activity, and night periods [20].

Figure 1: Approach of high intensity laser device in one patient with subacromial impingement syndrome.

Shoulder range of motion (ROM) in flexion

The space between the tip of the middle finger to the floor was measured when the patient was standing. The patient was instructed to bend forward to achieve spine limit, and the ROM value was recorded.

Constant-Murley scale (CMS)

CMS was used to assess the functional status of the affected shoulder. The CMS is a standardized clinical evaluation tool with a score ranging from 0 to 100 based on evaluation of four parameters: pain (15 points), daily life activities (20 points), active ROM (40 points), and muscle strength (25 points) [21]. The lower the CMS score, the worse the functional status of the shoulder is.

High-intensity laser therapy (HILT)

Subjects were instructed to assume the sitting position. Treatment probe was placed vertical to the skin and horizontally moved along the skin, as depicted in Figure 1. Table 1 shows the parameters of the HILT. The Gallium-Aluminum-Arsenide (GaAlAs) diode laser device (TI-816-12, TRANS Laser Therapy Apparatus, Taiwan) was manually set to biostimulation mode with power of 1.5 W, 2 J/cm^2, wavelength of 830 nm, and beam area of 0.75 cm^2. The laser was applied with constant moving speed with 6 points around the shoulder area, 5 sec to 12 sec at each point. In the session, total energy applied to the shoulder measured 150 J. The total application time lasted no longer than 15 min for each session. The time-amplitude curves for the various frequencies are shown in Figure 2.

Ethics statement

Informed consent was obtained from each participant before initiating the study. The study was conducted in accordance with the principles of the Helsinki Declaration of 1975, as revised in 2004. The approval of the Institutional Review Board was waived by the human ethics committee due to the retrospective nature of the study and the fact that it was for teaching purposes only.

Statistical analysis

Statistical analysis of all data was performed using IBM SPSS Statistics 22 (v.25, IBM Corp., Armonk, NY, USA) (IBM SPSS,

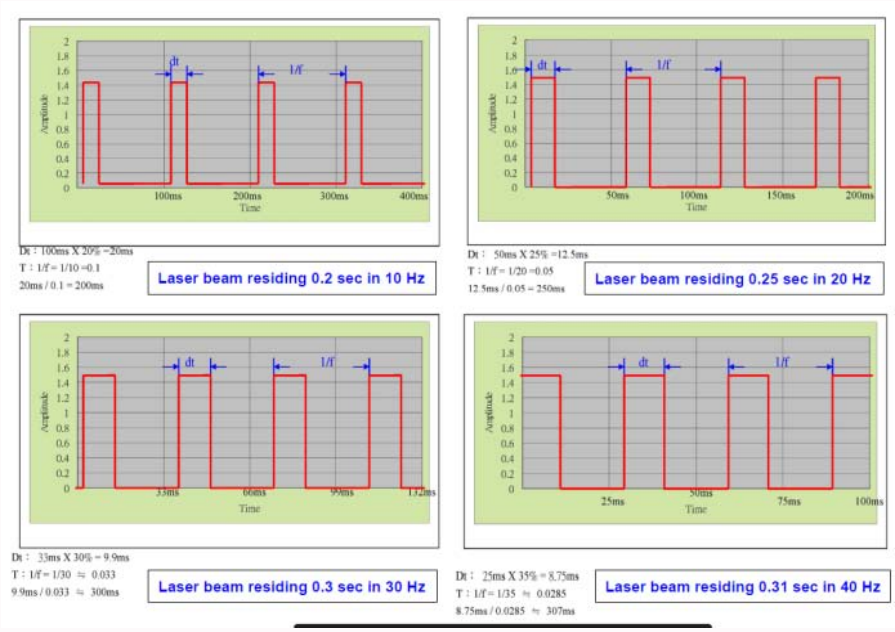

Figure 2: The characteristics of high intensity laser device in various frequencies.

Taiwan) program. All outcome measures were presented as means ± standard deviations using paired t-test. P<0.05 indicates a significant difference.

Results

The study was conducted from May to November 2019. A total of 20 patients were enrolled in this retrospective study and Table 2 shows the baseline characteristics. The mean age of the study patients was 50.5 ± 6.6 years. There were more women than men and the most prevalent affected area was the left side. The characteristics of participants are presented in the Table 2.

As shown in Figure 3, significant improvements in all parameters were observed immediately after treatment compared to pre-treatment values. Comparison of the VAS, shoulder ROM, and CMS showed a significant difference before and after treatment (6.65 ± 0.93 *vs.* 3.10 ± 0.55, 125.71 ± 15.12 *vs.* 137.52 ± 17.15, 37.51 ± 4.16 *vs.* 58.56 ± 7.27, respectively, all P<0.05). All patients tolerated the treatments well and no adverse events were found related to the treatments.

Discussion

The current study investigated the role of HILT in SAIS patients. This study aimed to evaluate the effects of HILT on patients with SAIS and to determine whether HILT is capable of relieving pain and improving shoulder flexion in SAIS. The findings of this study showed that HILT resulted in a significant improvement of VAS; shoulder ROM in flexion, and CMS at the end of the study intervention. We obtained statistically significant improvements in comparison with the baseline values in scores of pain on VAS and CMS. Previous reports have demonstrated that proinflammatory cytokines were found at high levels in the subacromial bursa of patients with rotator cuff disease [22-25]. A recent study showed increased level of IL-8 was associated with resting pain [26]. In our study, we speculate that HILT contributed to overall improvement by suppressing the inflammation.

SAIS is known to occur due to impingement and inflammation

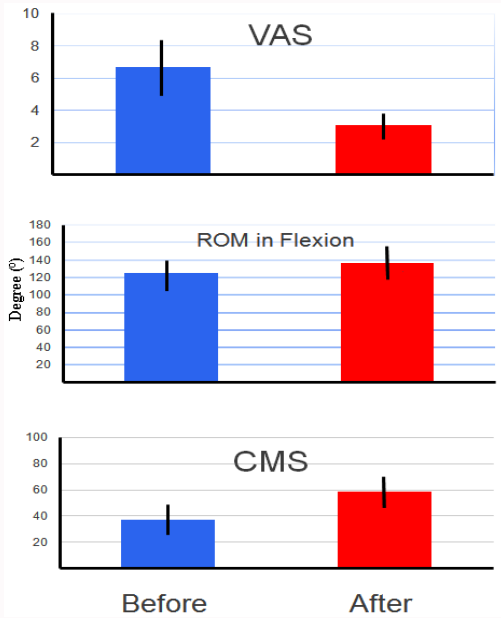

Figure 3: Comparison of VAS score, shoulder Range of Motion (ROM) in flexion, and Constant-Murley Scale (CMS) before and after treatment.

of the rotator cuff tendons in the subacromial space located between the humeral head and the coracoacromial arcus. SAIS is one of the most common causes of shoulder pain (25%), and it occurs when the supraspinatus tendon, subacromial bursa, or bicipital tendon become entrapped as they pass between the sub-acromial space during shoulder movements [5,15]. SAIS may develop as a result of several conditions such as weakness of rotator cuff muscles, abnormality of the acromion, repetitive trauma, and overuse of the shoulder. It is characterized by shoulder pain accompanied by restriction of the shoulder ROM and disability in daily life activities [27]. The underlying pathology in SAIS may present as edema, bleeding, fibrosis, tendinitis, and partial or complete rupture of the rotator cuff

Table 1: The parameters of the high-intensity laser device used in the current study.

Item and units	Laser parameters
Laser source	Gallium-aluminum-arsenide (GaAlAs) diode
Model of machine	TI-816-12-830
Wavelength (nm)	830 ± 5
Maximum power (mW)	≦ 1500
Average power (mW)	1500
Laser beam diameter (cm)	≦ 1.5 cm
Laser beam area (cm^2)	≦ 0.75, in general
Energy density (J/cm^2)	2 J/cm^2
Frequency range (Hz)	0 (continuous wave), 10, 20, 30, 40
Frequency, mostly used in the current study (Hz)	10
Duty cycle	Duty cycle (10Hz): 20%
	Duty cycle (20Hz): 25%
	Duty cycle (30Hz): 30%
	Duty cycle (40Hz): 35%
Energy density (under varying duty cycles)	2 X 20%=0.4 J/cm^2 (10Hz)
	2 X 25%=0.5 J/cm^2 (20Hz)
	2 X 30%=0.6 J/cm^2 (30Hz)
	2 X 35%=0.7 J/cm^2 (40Hz)
The frequency of treatment regularly	5 sessions per week for 3 weeks
The frequency of treatment in the current study	Only 1 session (15 min)
Distance of laser beam penetrating into skin (cm)	≦ 1cm

tendons, depending on the severity of the syndrome [28].

HILT has recently been applied as a novel modality for physical therapy [15]. In a study that assessed the short-term effects of HILT versus ultrasound diathermy in the treatment of SAIS, the results showed greater reduction in pain and improvement in joint motion functionality and muscle strength of the affected shoulder after short-term (10 treatment sessions) HILT compared with participants receiving ultrasound over a period of 2 consecutive weeks [14]. The 15-days effects of HILT and manual therapy were found to be more effective in minimizing pain and disability and increasing ROM than Kinesio taping plus exercise in patients with SAIS [12]. HILT was found to be effective in the short term (8 weeks) in the treatment of pain and disability in patients with SAIS [15]. Another recent study showed that the effect of HILT plus exercise was not better than exercise alone for reduction of pain and improvement of function in patients with SAIS after a three-month follow-up [17]. Aceituno-Gómez et al. [16] described the long-term effect of HILT in a patient with chronic shoulder refractory pain in comparison to other treatments. After 6 months, an increase in pressure pain threshold and a decrease in pain and disability scores were observed [16].

Furthermore, our results showed that patients receiving HILT displayed a higher degree of improvement in terms of VAS and shoulder flexion, when compared with pre-treatment values. HILT improves disease conditions, and thus it can play an important role in pain relief and functional recovery [29]. HILT provided analgesic and detumescence effects, which facilitated resolution of inflammation in local issue, improved circulation, reduced SAIS, and improved recovery of function in patients with SAIS, and these findings were consistent with previous study results. HILT confers real-time, complex, large-scale, deep-level, and large-dose effects on the body's diseased tissues.

Table 2: Demographic baseline characteristics of patients (N=20).

Characteristics	
Age (y), mean (SD)	50.5 ± 6.6
Sex: Male/female (n)	8/12
Duration of complaint (month)	1.17 ± 0.78
Affected side (Right/Left)	6/14
Joint restriction (capsular pattern/non-capsular pattern)	6/14

N: Number of subjects; SD: Standard Deviation

With respect to the mechanism, the analgesic effect of HILT relies on different mechanisms of action, such as slowing down the pain transmission and increasing the production of morphine-like substances. Studies have shown stronger and immediate photo effects of HILT lasers, which permeate the body more easily, reach deeper levels, enhance photo-biological impacts on tissues, activate muscles, and improve the function of core muscles, thus resulting in an overall improvement of the state of patients with SAIS and their daily life function. Its photomodulative effects can cause increased tissue stimulation, mitochondrial oxidative reaction, as well as production of adenosine triphosphate [30].

Limitations of the Study

Our results showed that HILT had an immediate benefit on pain relief, shoulder function, and CMS in patients with SAIS. Our study has some limitations. First, the sample size was small. Second, this was not a randomized investigation. Third, there was no control or placebo group. Fourth, the study period may have been too short to see the full benefits of HILT on pain relief and shoulder function. We anticipate that there may be different results if the effects of HILT are investigated over a longer duration, such as 6 months to one year post-intervention.

Conclusion

The results of our study suggest that HILT provides benefit in the treatment of SAIS. HILT reduces pain and disability and improves shoulder ROM in patients with SAIS. The clinical application benefits of HILT can immediately improve pain relief and shoulder function in patients with SAIS. In the future, the clinical benefits of different doses or treatment times should be further explored. Further studies investigating the long-term effects of HILT may contribute to a better understanding of this treatment modality.

References

1. Van der Windt DA, Koes BW, de Jong BA, Bouter LM. Shoulder disorders in general practice: Incidence, patient characteristics, and management. Ann Rheum Dis. 1995;54(12):959-64.

2. Garving C, Jakob S, Bauer I, Nadjar R, Brunner UH. Impingement syndrome of the shoulder. Dtsch Arztebl Int. 2017;114(45):765-76.

3. Radnovich R, Marriott TB. Utility of the heated lidocaine/tetracaine patch in the treatment of pain associated with shoulder impingement syndrome: A pilot study. Int J Gen Med. 2013;6:641-6.

4. Chang WK. Shoulder impingement syndrome. Phys Med Rehabil Clin N Am. 2004;15(2):493-510.

5. Thornton AL, McCarty CW, Burgess MJ. Effectiveness of low-level laser therapy combined with an exercise program to reduce pain and increase

function in adults with shoulder pain: A critically appraised topic. J Sport Rehabil. 2013;22(1):72-8.

6. Park SI, Choi YK, Lee JH, Kim YM. Effects of shoulder stabilization exercise on pain and functional recovery of shoulder impingement syndrome patients. J Phys Ther Sci. 2013;25(11):1359-62.

7. Galace de Freitas D, Marcondes FB, Monteiro RL, Rosa SG, Maria de Moraes Barros Fucs P, Fukuda TY. Pulsed electromagnetic field and exercises in patients with shoulder impingement syndrome: a randomized, double-blind, placebo-controlled clinical trial. Arch Phys Med Rehabil. 2014;95(2):345-52.

8. Akkaya N, Akkaya S, Gungor HR, Yaşar G, Atalay NS, Sahin F. Effects of weighted and un-weighted pendulum exercises on ultrasonographic acromiohumeral distance in patients with subacromial impingement syndrome. J Back Musculoskelet Rehabil. 2017;30(2):221-8.

9. Gebremariam L, Hay EM, van der Sande R, Rinkel WD, Koes BW, Huisstede BM. Subacromial impingement syndrome - effectiveness of physiotherapy and manual therapy. Br J Sports Med. 2014;48(16):1202-8.

10. Dogu B, Yucel SD, Sag SY, Bankaoglu M, Kuran B. Blind or ultrasound-guided corticosteroid injections and short-term response in subacromial impingement syndrome: A randomized, double-blind, prospective study. Am J Phys Med Rehabil. 2012;91(8):658-65.

11. Pérez-Merino L, Casajuana MC, Bernal G, Faba J, Astilleros AE, González R, et al. Evaluation of the effectiveness of three physiotherapeutic treatments for subacromial impingement syndrome: A randomized clinical trial. Physiotherapy. 2016;102(1):57-63.

12. Pekyavas NO, Baltaci G. Short-term effects of high-intensity laser therapy, manual therapy, and Kinesio taping in patients with subacromial impingement syndrome. Lasers Med Sci. 2016;31(6):1133-41.

13. Alayat MS, Mohamed AA, Helal OF, Khaled OA. Efficacy of high-intensity laser therapy in the treatment of chronic neck pain: A randomized double-blind placebo-control trial. Lasers Med Sci. 2016:31(4):687-94.

14. Santamato A, Solfrizzi V, Panza F, Tondi G, Frisardi V, Leggin BG, et al. Short-term effects of high-intensity laser therapy versus ultrasound therapy in the treatment of people with subacromial impingement syndrome: A randomized clinical trial. Phys Ther. 2009;89(7):643-52.

15. Karaca B. Effectiveness of high-intensity laser therapy in subacromial impingement syndrome. Photomed Laser Surg. 2016;34(6):223-8.

16. Aceituno-Gómez J, García-Madero VM, Criado-Álvarez JJ, González-González J, Gómez-Soriano J, Avendaño-Coy J. Long-term effect of high-intensity laser therapy for persistent shoulder pain: A case report. J Back Musculoskelet Rehabil. 2019.

17. Aceituno-Gómez J, Avendaño-Coy J, Gómez-Soriano J, García-Madero VM, Ávila-Martín G, Serrano-Muñoz D, et al. Efficacy of high-intensity laser therapy in subacromial impingement syndrome: A three-month follow-up controlled clinical trial. Clin Rehabil. 2019;33(5):894-903.

18. Caliş M, Akgün K, Birtane M, Karacan I, Caliş H, Tüzün F. Diagnostic values of clinical diagnostic tests in subacromial impingement syndrome. Ann Rheum Dis. 2000;59(1):44-7.

19. Cadogan A, McNair PJ, Laslett M, Hing WA. Diagnostic accuracy of clinical examination and imaging findings for identifying subacromial pain. PLoS One. 2016;11(12):e0167738.

20. Price DD, McGrath PA, Rafii A, Buckingham B. The validation of visual analogue scales as ratio scale measures for chronic and experimental pain. Pain 1983;17(1):45-56.

21. Constant CR, Murley AH. A clinical method of functional assessment of the shoulder. Clin Orthop Relat Res. 1987;214:160-4.

22. Voloshin I, Gelinas J, Maloney M, O'Keefe RJ, Bigliani LU, Blaine TA. Proinflammatory cytokines and metalloproteases are expressed in the subacromial bursa in patients with rotator cuff disease. Arthroscopy. 2005;21(9):1076.e1-1076.e9.

23. Blaine TA, Kim YS, Voloshin I, Chen D, Murakami K, Chang SS, et al. The molecular pathophysiology of subacromial bursitis in rotator cuff disease. J Shoulder Elbow Surg. 2005;14(1 Suppl S):84S-9S.

24. Gotoh M, Hamada K, Yamakawa H, Inoue A, Fukuda H. Increased substance P in subacromial bursa and shoulder pain in rotator cuff diseases. J Orthop Res. 1998;16(5):618-21.

25. Kim YS, Bigliani LU, Fujisawa M, Murakami K, Chang SS, Lee HJ, et al. Stromal cell-Derived Factor 1 (SDF-1, CXCL12) is increased in subacromial bursitis and down regulated by steroid and nonsteroidal anti-inflammatory agents. J Orthop Res. 2006;24(8):1756-64.

26. Okamura K, Kobayashi T, Yamamoto A, Shitara H, Osawa T, Ichinose T, et al. Shoulder pain and intra-articular interleukin-8 levels in patients with rotator cuff tears. Int J Rheum Dis. 2017;20(2):177-81.

27. Yazmalar L, Sarıyıldız MA, Batmaz İ, Alpaycı M, Burkan YK, ÖzkanY, et al. Efficiency of therapeutic ultrasound on pain, disability, anxiety, depression, sleep and quality of life in patients with subacromial impingement syndrome: A randomized controlled study. J Back Musculoskelet Rehabil. 2016;29(4):801-7.

28. Mayerhoefer ME, Breitenseher MJ, Wurnig C, Roposch A. Shoulder impingement: Relationship of clinical symptoms and imaging criteria. Clin J Sport Med. 2009;19(2):83-9.

29. Dundar U, Turkmen U, Toktas H, Ulasli AM, Solak O. Effectiveness of high-intensity laser therapy and splinting in lateral epicondylitis; a prospective, randomized, controlled study. Lasers Med Sci. 2015;30(3):1097-107.

30. Zati A, Valent A. Physical therapy: New technologies in rehabilitation medicine. Edizioni Minerva Medica. 2006:162-85.