



# Synchronous Squamous Cell Lung Carcinoma, Vocal Cord and Pulmonary Hamartoma

Cuneyt Tetikkurt<sup>1\*</sup>, Gulsum Karakas<sup>1</sup> and Seza Tetikkurt<sup>2</sup>

<sup>1</sup>Department of Pulmonary Medicine, Istanbul Cerrahpasa University, Turkey

<sup>2</sup>Department of Pathology, Demiroglu Bilim University, Turkey

## Abstract

A 64 year old male was admitted for fever, sputum and fluctuating hoarseness over the last three weeks. Physical examination revealed rales and decreased breath sounds over the lower right lower lung zones. He was a smoker with a 30-pack year history. Serum biochemistry was normal except for leukocytosis and a high CRP value. PFTs revealed a mild obstructive defect. Chest X-ray showed a dense parenchymal infiltration with air bronchograms in the right lower zone. Axial CT image revealed pneumonic consolidation and atelectasis of the right lower lobe while sagittal CT image demonstrated a nodular opacity located at the left upper division and the lingula bronchus carena. Bronchoscopic examination disclosed a pink submucosal nodule over the left vocal cord, complete obstruction of the lower lobe orifice with submucosal tumoral infiltration and another submucosal nodule in the left secondary carena between the upper division and lingula bronchus. Pathologic examination of the lower lobe mass revealed squamous cell carcinoma of the lung while vocal cord and carenal nodule histopathology showed hamartoma.

We present this case to reveal the presence of a vocal cord hamartoma which is an extremely rare finding. Our second aim was to report the simultaneous emergence of two hamartomas along with squamous carcinoma of the lung that has not been reported in the literature up to now.

**Keywords:** Hamartoma; Lung cancer; Epidermoid carcinoma; Vocal cord

## OPEN ACCESS

### \*Correspondence:

Cuneyt Tetikkurt, Department of Pulmonary Medicine, Istanbul Cerrahpasa University, Tanzimat Sok. Serkan Apt. No:8/16, 34728, Caddebostan, Istanbul, Turkey, Tel: +90-532-3810900; Fax: +90-212-5870217;

E-mail: tetikkurt@gmail.com

Received Date: 18 Nov 2019

Accepted Date: 17 Dec 2019

Published Date: 23 Dec 2019

### Citation:

Tetikkurt C, Karakas G, Tetikkurt S. Synchronous Squamous Cell Lung Carcinoma, Vocal Cord and Pulmonary Hamartoma. *J Respir Med Lung Dis.* 2019; 4(2): 1047.

ISSN: 2475-5761

Copyright © 2019 Cuneyt Tetikkurt.

This is an open access article distributed under the Creative Commons Attribution License, which permits unrestricted use, distribution, and reproduction in any medium, provided the original work is properly cited.

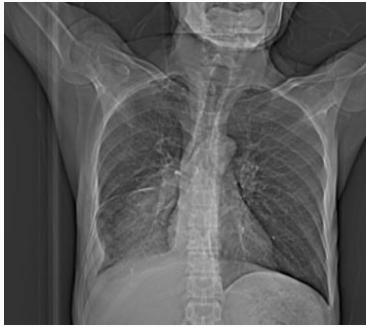## Introduction

Pulmonary hamartomas are abnormal mixture of normal developmental components, with an approximate incidence of 0.3%. Although rare, they are the most common benign lesion of lung and account for approximately 6% of all the solitary pulmonary nodules [1,2]. Hamartoma is a benign mesenchymal tumor with an abnormal mixture of tissue components or an altered proportion of a normal tissue ingredient. The tumor consists of fat, cartilage, bone, connective tissue and smooth muscle [3,4]. Chondroid hamartomas of the vocal cord are extremely rare pseudotumoral lesions that are rarely malignant in contrast to pulmonary hamartomas. Because they are slowly growing tumors they are usually asymptomatic and may not be identified for years [5-9]. Pulmonary Hamartoma (PH) also known as mesenchymoma was first described in 1904 by Albrecht. In 1934, Goldsworthy applied this term to benign tumors located in the lung that were composed predominantly of a combination of fat and cartilage [10-12]. They are usually detected incidentally on chest radiographs as an incidental coin lesions that appear as well-defined and solitary pulmonary nodules. Hamartomas can occur in any part of the lungs, but are more often found in the periphery [13-15].

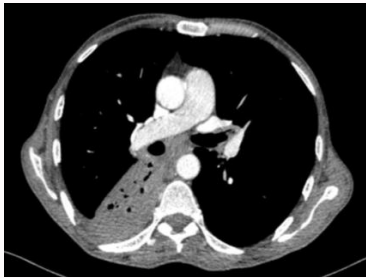We present a case of vocal cord and carenal hamartoma occurring simultaneously in a patient with squamous cell carcinoma of the lung. Hamartoma of the vocal cords is very rare and usually asymptomatic [6-12]. On the other hand, coexistence of vocal hamartoma with squamous cell lung carcinoma is another rare occurrence [4,5,8,9]. The second hamartoma in our patient which is located in the secondary carena between the upper division and lingula bronchus has not been reported in the literature previously.

## Case Presentation

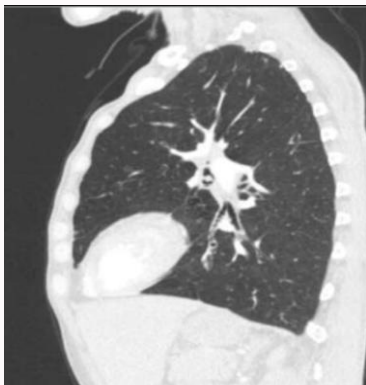A 64 year old male presented with fever, sputum and fluctuating hoarseness over the last three weeks. Personal and family histories were excellent. The patient had a 30-pack year smoking history. Serum biochemistry was within normal limits while leukocyte count (WBC:  $14.9 \times 10^3/\mu\text{L}$ ) and



**Figure 1:** Chest X-ray showing atelectasis and pneumonic infiltration in the right lower lobe.



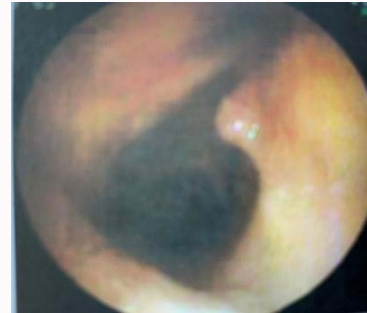
**Figure 2:** Axial thorax CT revealing right lower atelectasis and pneumonic infiltration.



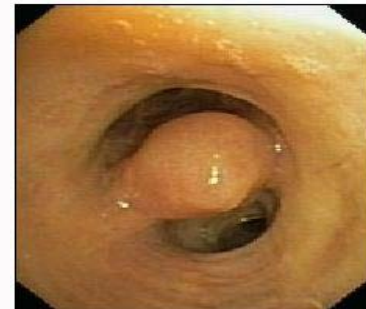**Figure 3:** Sagittal CT image demonstrating a nodular opacity in the carina between the upper division and lingula bronchus.

CRP (CRP: 112.7 mg/L) were high and consistent with infection. ECG demonstrated sinus tachycardia of 104/minute. Chest X-ray (Figure 1) showed left lower lobe atelectasis. Pulmonary function tests showed mild obstructive defect with  $FEV_1$ : 2.23L (60%), FVC: 3.14 L (64%) and  $FEV_1/FVC$ : 71%. Axial thorax CT revealed atelectasis and pneumonic consolidation with air bronchograms in the right lower lobe (Figure 2) while a nodular opacity in the left upper division and lingula bronchus carina was demonstrated in the sagittal CT image (Figure 3). Antibiotic treatment was commenced for pneumonia that showed complete resolution after ten days with leukocytosis and CRP returning to normal levels. Fiberoptic bronchoscopy revealed a left vocal nodule (Figure 4), a nodular lesion in the left upper division and lingula bronchus carina (Figure 5) and complete obstruction of the right lower lobe with submucosal tumoral infiltration (Figure 6).

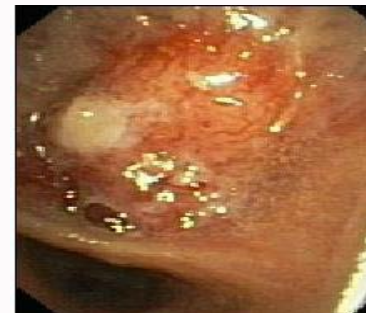Histopathologic examination of the right lower tumor was compatible with squamous cell carcinoma. Pathology of the left vocal



**Figure 4:** Bronchoscopic image of the the right vocal cord hamartoma.



**Figure 5:** Bronchoscopic view of the hamartoma in the the carina between the upper division and lingula bronchus.



**Figure 6:** Submucosal tumoral infiltration leading to complete obstruction of the right lower bronchus.

cord and the left carina one nodule revealed identical histopathologic features relevant to hamartoma. Histologic sections showed variable mixture of mature hyaline cartilage, fat, smooth muscle with immature myxomatous tissue at the periphery of the cartilage and entrapped clefts lined by respiratory epithelium.

## Discussion

Chondroid hamartomas of the larynx are extremely rare pseudotumoral lesions and they barely show malignant transformation with fewer than a dozen cases which have been reported. These tumors can go undetected for years if they do not grow to large sizes and cause symptoms such as dysphonia, dyspnea or cough [6,7,13,15-17]. On the other hand, pulmonary hamartomas are benign lesions that account 6% of all solitary lung tumors. They are usually asymptomatic if located in the peripheral lung parenchyma while endobronchial hamartomas may lead to obstructive symptoms [3,5]. We present a case of synchronous squamous lung carcinoma long with a vocal cord and a pulmonary hamartoma.

Hamartomas are benign mesenchymal tumors that may occur throughout the body. Hamartomas of the larynx are extremely rare and less than thirty five cases have been reported in the literature [6,7,13,15]. Although laryngeal hamartomas usually lead to obstructive symptoms, only one case with vocal cord paralysis has been described [16-18]. Our patient presented with pneumonia and fluctuating hoarseness. Chest CT revealed findings of obstructive pneumonia in the right lower lobe while squamous cell carcinoma of the right lower lobe, hamartomas of the vocal cord and left carina one were identified by the pathologic examination of bronchoscopic biopsy samples. As far as we know, this is the first case in literature with such a presentation. The second crucial aspect of this case is the presence of fluctuating hoarseness due to vocal cord hamartoma which has not been reported previously in literature. The intermittent hoarseness in our patient is probably due to the transient vocal cord edema and the small size of the vocal cord hamartoma. Another crucial point of our case is that the carenal hamartoma was only demonstrated in the sagittal chest CT image since it was too small to be seen end on, in the axial CT slice.

The risk of synchronous lung cancer in patients with pulmonary hamartoma is approximately six times higher than the general population [8,9]. Pulmonary hamartomas are frequently encountered in patients undergoing pulmonary resection for lung carcinomas [10] and the prevalence may be as high as 12% as Smith et al. has reported [11]. On the other hand, Kawano revealed simultaneous lung cancers in 25% of the patients with resected pulmonary hamartomas [19-23]. The coexistence of hamartoma along with lung cancer is a well-known fact but the synchronous presence of two hamartomas and squamous lung cancer has not been reported previously in literature. Another impressive hallmark of our case is the identification of the left carenal hamartoma only in the sagittal CT section but not in the routine axial CT slice. Furthermore, vocal cord hamartoma by itself is an extremely rare occurrence which is another crucial aspect of the aforementioned patient.

## Conclusion

Hamartomas are the most frequent benign tumors of the lung. These benign tumors may arise in any organ while vocal cord hamartomas are extremely rare. Hamartomas may appear as a solitary nodule or present as multiple nodules in the lung. Pulmonary hamartomas may be overlooked and may be missed clinically on axial CT scans if they are not large enough and symptomatic. It should also be noted that temporary or intermittent hoarseness may be the initial manifestation of small sized vocal cord hamartomas. Clinicians should always bear in mind the possibility of pulmonary hamartomas coexisting with lung cancer. Sagittal CT images must be evaluated with extreme caution along with the axial CT sections not to miss such type of lesions that are too small to be detected on axial CT slices alone.

## References

1. Wiatrowska BA, Yazdi HM, Matzinger FR, MacDonald LL. Fine needle aspiration biopsy of pulmonary hamartomas. Radiologic, cytologic and immunocytochemical study of 15 cases. *Acta Cytol.* 1995;39(6):1167-74.
2. Gjevne JA, Myers JL, Prakash UB. Pulmonary hamartomas. *Mayo Clin Proc.* 1996;71(1):14-20.
3. Fudge TL, Ochsner JL, Mills NL. Clinical spectrum of pulmonary hamartomas. *Ann Thorac Surg.* 1980;30(1):36-9.
4. Salminen US. Pulmonary hamartoma. A clinical study of 77 cases in a 21-year period and review of literature. *Eur J Cardiothorac Surg.* 1990;4(1):15-8.
5. Whyte RI, Donington JS. Hamartomas of the lung. *Semin Thorac Cardiovasc Surg.* 2003;15(3):301-4.
6. Amir JA, Sheikh SS. Mesenchymal hamartoma of the larynx: A rare case report and review of the literature. *Case Rep Clin Pathol.* 2015;2(3):40-3.
7. Colon J, Jang D, Signore A. Hamartoma of the larynx: A report of two cases. *The Laryngoscope.* 2011;11:S128-S128.
8. Karasik A, Modan M, Jacob CO, Lieberman Y. Increased risk of lung cancer in patients with chondromatous hamartoma. *J Thorac Cardiovasc Surg.* 1980;80(2):217-20.
9. Ribet M, Jaillard-Thery S, Nuttens MC. Pulmonary hamartoma and malignancy. *J Thorac Cardiovasc Surg.* 1994;107(2):611-4.
10. Cahan WG, Shah JP, Castro EB. Benign solitary lung lesions in patients with cancer. *Ann Surg.* 1978;187(3):241-4.
11. Smith MA, Battafarano RJ, Meyers BF, Zoole JB, Cooper JD, Patterson GA. Prevalence of benign disease in patients undergoing resection for suspected lung cancer. *Ann Thorac Surg.* 2006;81(5):1824-8.
12. Kawano R, Sato F, Tagawa K, Yokota F, Ikeda S, Hata E. Clinicopathological study of patients with coexistence of pulmonary hamartoma and primary lung cancer. *J Jpn Assoc Chest Surg.* 2007;21:526-30.
13. Windfuhr JP. Laryngeal hamartoma. *Acta Otolaryngol.* 2004;124(3):301-8.
14. Cohen SR. Posterior cleft larynx associated with hamartoma. *Ann Otol Rhinol Laryngol.* 1984;93(5 Pt 1):443-6.
15. Rinaldo A, Mannarà GM, Fisher C, Ferlito A. Hamartoma of the larynx: a critical review of the literature. *Ann Otol Rhinol Laryngol.* 1998;107(3):264-7.
16. Park SK, Jung H, Yang YI. Mesenchymal hamartoma in nasopharynx: a case report. *Auris Nasus Larynx.* 2008;35(3):437-9.
17. Mäkitie AA, Lehtonen H, Bäck L, Aaltonen LM, Leivo I. Hamartoma of the larynx: an unusual cause of dyspnea. *Ann Otol Rhinol Laryngol.* 2003;112(10):841-3.
18. Umashankar T, Devadas AK, Ravichandra G, Yaranal PJ. Pulmonary hamartoma: Cytological study of a case and literature review. *J Cytol.* 2012;29(4):261-3.
19. Lazovic B, Jakovic R, Dubajic S, Gataric Z. Pulmonary hamartoma-Case report and review of literature. *Arch Oncol.* 2011;19:37-8.
20. van den Bosch JM, Wagenaar SS, Corrin B, Elbers JR, Knaepen PJ, Westermann CJ. Mesenchymoma of the lung (so called hamartoma): a review of 154 parenchymal and endobronchial cases. *Thorax.* 1987;42(10):790-3.
21. El-Kersh K, Perez RL, Gauhar U. A 63-year-old man with a chronic cough and an endobronchial lesion. Diagnosis: Endobronchial hamartoma. *Chest.* 2014;145(4):919-22.
22. Huang CC, Sheu CY, Tzen CY, Huang WC. Pulmonary hamartoma mimicking primary bronchoalveolar cell carcinoma. *Thorax.* 2012;67(2):187-8.
23. Cosío BG, Villena V, Echave-Sustaeta J, de Miguel E, Alfaro J, Hernandez L, et al. Endobronchial hamartoma. *Chest.* 2002;122(1):202-5.