



Sternal Closure with a Braided Cable System: Another Word of Caution

Louis Edward Samuels* and David Klodowski BS

Department of Surgery, Thomas Jefferson University, Philadelphia, USA

Abstract

Sternal closure techniques following open heart surgery vary from simple stainless-steel wires to more complex products designed to improve bony stability to promote healing and reduce pain. A sternal cable, which is made of braided metallic material, has been used in cardiac surgery with mixed results. The author (L.E.S.) reports the experience with the braided cable system and the concern for sternal wound complications. A case of sternal wound infection is described in the context of a period in which a spike in complications overall occurred in association with this product. As previously reported with a plastic sternal closure system, the same concern for sternal wound problems related to the product applies and another 'word of caution' is in order. Perhaps the simplest product stainless steel wires are still the best product.

Introduction

The median sternotomy is the most commonly used approach for conducting cardiac surgery. Reconstruction of the sternum following the procedure has been achieved with a variety of products and techniques, the most common of which employ simple stainless steel wires. The number of wires varies from surgeon to surgeon and modifications of these techniques have been utilized over the decades. Alternative products, such as plates and screws, tie-bands, sternal talons, and cables have all been introduced and used in the cardiac surgical community. The experience with these alternative products has been mixed and no prospective randomized trials have ever been conducted to determine whether one product or technique is superior to another. However, individual experiences have shed light on concerns related to sternal healing and the need for sternal hardware removal. The purpose of this report is to describe a case in which a patient required removal of sternal cables due to sternal wound infection. The case illustrates the authors concern with the product a concern that was experienced by the author (L.E.S.) previously, but unreported.

OPEN ACCESS

*Correspondence:

Louis Edward Samuels, Department of Surgery, Division of Cardiothoracic Surgery, Thomas Jefferson University, Albert Einstein Medical Center, Philadelphia, PA 19107, USA, E-mail: samuelsle@aol.com

Received Date: 24 Jul 2019

Accepted Date: 14 Aug 2019

Published Date: 16 Aug 2019

Citation:

Samuels LE, David Klodowski BS. Sternal Closure with a Braided Cable System: Another Word of Caution. *Ann Thorac Surg Res.* 2019; 1(2): 1007.

Copyright © 2019 Louis Edward Samuels. This is an open access article distributed under the Creative Commons Attribution License, which permits unrestricted use, distribution, and reproduction in any medium, provided the original work is properly cited.

Case Presentation

A 72-year-old man presented with sternal pain three months after an uncomplicated triple vessel coronary artery bypass graft procedure performed *via* a median sternotomy. At the time of the initial operation sternal cables were used to reapproximate the sternum. Standard perioperative antibiotics were given at the time of surgery and there was no indication of a sternal wound problem at the time of discharge. The patient's past medical history was significant for End Stage Renal Disease (ESRD) requiring hemodialysis.

Inspection of the incision was notable for swelling, tenderness, and erythema. Labs and vitals at the time of presentation were positive for a mild elevation in white blood cell count. Chest radiography showed all sternal cables intact (Figure 1). A Computer Tomographic scan of the chest showed a complex fluid collection in the subcutaneous tissue overlying the sternum. No substernal collection was observed. Blood cultures were positive for Methicillin Sensitive Staphylococcus Aureus (MSSA).

The initial incision resulted in significant purulent drainage (Figure 2). Inspection of the area after suctioning was notable for soft tissue swelling around the braided sternal cables (Figure 3). The inflamed soft tissue was debrided leaving the body and manubrium of the sternum intact. The sternum itself was well approximated and firm with no clinical suspicion for osteomyelitis. A Vacuum Assisted Closure (VAC) system was applied and the patient discharged on antibiotics with weekly clinic follow up. Samples of soft tissue were sent during the debridement and were found to be positive for MSSA. The wound remained clean and healed without incident with no recurrence of infection. The patient's pain was completely relieved.

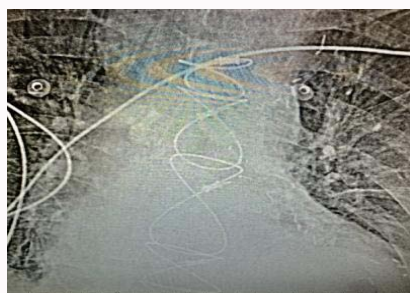

Figure 1: Radiograph of sternal cables.

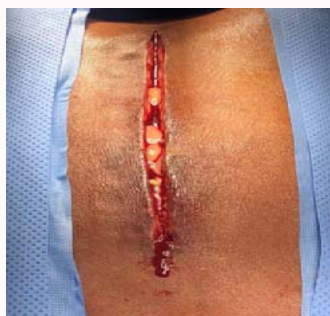

Figure 2: Sternal wound after initial incision showing purulence.

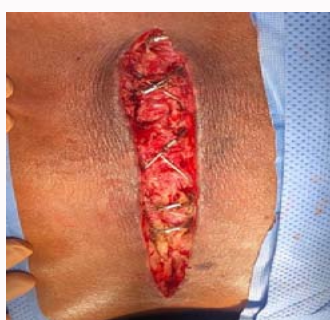

Figure 3: Sternal wound showing sternal cables.

Comments

Sternal closure techniques vary with simple stainless-steel wires being used most commonly. Alternatively, cable closure for sternotomies have been advocated because of the increased strength of cables over simple wires with the assumption that prevention of wire fracture and superiority of bony reapproximation would reduce overall sternal wound complications including pain [1]. Although the use of cable closure may be favorable in preventing misalignment and post-operative thoracic cage abnormalities, the nature of the material itself may incite microvascular compromise and subsequent local inflammation. Additionally, the increased surface area associated with the braiding of the metal may increase chances of contamination and infection. In one study of bacterial contamination of surgical suture showed that braided material was more associated with bacterial growth than non-braided (monofilament) material. In particular, *Staphylococcus aureus* adhered to suture material and formed a structure consistent with a bacterial biofilm [2]. In a clinical experience using a modular sternal cable system consisting of plates, screws, and cables, Grabert and others found a high incidence of postoperative wound infections and speculated that the hardware compromised osseous microcirculation favoring the development

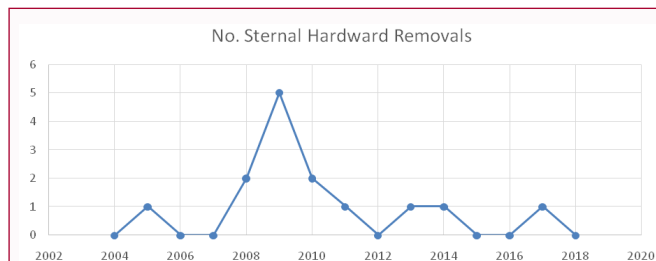


Figure 4: Increase in need for sternal hardware removal during use of cables (2008 through 2010) compared with steel wires prior to and following this time period.

of infection [3]. Dunne and colleagues, in a randomized control trial comparing sternal wires vs. cable for sternotomy closure, observed deep sternal wound infection in 3.7% of patients using braided sternal cables compared to 0.7% using traditional sternal wires [4]. However, not all investigators found sternal cables to be a problem. A retrospective study of cardiac surgical patients comparing sternal cable vs. sternal wire closure found no difference in major wound complications (1.3% vs. 1.3%, $p=1.00$) [5]. Ozen and coworkers, examining 56 patients (24 cables and 32 wires) found the braided sternal cable group more favorable than the sternal wire group with regard to postoperative sternal wound complications [6].

The case represented in this report is reflective of the author's (L.E.S.) experience with sternal cable and other non-wire closure devices. In a previous publication regarding the use of plastic tie-band (ZipFix, Synthes, Inc, West Chester, PA), a word of caution was suggested by the author regarding the failure rate and soft tissue reaction to this product [7]. In a review of the author's experience over a 17-year period examining the data for sternal hardware removal, the association between the introduction and discontinuation of sternal cables (2008 -2010) was not coincidental or random (Figure 4). Two-thirds of the cables removed during this time frame were due to persistent sternal pain with associated soft tissue edema; the other third was due to infection with *Staphylococcus aureus*. Upon removal of the cables, the pain resolved and the infections eradicated in all cases with sternal preservation. An extreme example of a case report by Bhavani et al. [8] described erosion of a sternal cable into the right ventricular outflow tract.

In summary, sternal closure with a cable system may afford excellent reapproximation of the sternum; however the tissue reaction around the braided metal may translate into pain and/or infection in some cases. The author's previous experience with sternal closure with cables resulted in a sharp and discrete rise in sternal wound problems. Although the sternal bone itself remained solid and intact, including those with superficial sternal wound infections, the soft tissue edema was evident and the pain along with it. Removal of the cables eliminated the pain and no further need for bony debridement was necessary. The case presented in this report reinforces the author's experience. It is the opinion of the author that another word of caution is in order when considering alternative sternal closure products, including cables.

References

1. Wangsgard C, Cohen DJ, Griffin LV. Fatigue testing of three peristernal median sternotomy closure techniques. *J Cardiothorac Surg*. 2008;3:52.
2. Henry-Stanley MJ, Hess DJ, Barnes AM, Dunny GM, Wells CL. Bacterial contamination of surgical suture resembles a biofilm. *Surg Infect*.

- 2010;11(5):433-9.
3. Grabert S, Erlebach M, Will A, Lange R, Voss B. Unexpected results after sternal reconstruction with plates, cables and cannulated screws. *Interact Cardiovasc Thorac Surg.* 2016;22(5):663-7.
 4. Dunne B, Murphy M, Skiba R, Wang X, Ho K, LARBalestier R, et al. Sternal cables are not superior to traditional sternal wiring for preventing deep sternal wound infection. *Interact Cardiovasc Thorac Surg.* 2016;22(5):594-8.
 5. Oh YN, Ha KJ, Kim JB, Jung SH, Choo SJ, Chung CH, et al. Multifilament cable wire versus conventional wire for sternal closure in patients undergoing major cardiac surgery. *Korean J Thorac Cardiovasc Surg.* 2015;48(4):265-71.
 6. Özen Y, Sarıkaya S, Rabuş MB, Günay D, Aksoy E, Dedemoğlu M, et al. Comparison of the sternal wires and sternal cable in closure of the sternum during cardiac surgery. *Cardiovasc Surg Intervent.* 2014;1(2):41-4.
 7. Samuels L. Sternal closure with tie bands: a word of caution. *Ann Thorac Surg.* 2016;102(2):e121-2.
 8. Bhavani SS, Slisatkorn W, Rehm SJ, Pettersson GB. Deep sternal wire infection resulting in severe pulmonary valve endocarditis. *Ann Thorac Surg.* 2006;82(3):1111-3.