



Stag Beetle Knife and 0.4% Sodium Hyaluronate in Esophageal Endoscopic Submucosal Dissection

Shinsuke Nawa* and Kiyooki Honma

Department of Therapeutic Endoscopy, Nihonkai General Hospital, Yamagata, Japan

Abstract

Objective: Esophageal endoscopic submucosal dissection (ESD) requires more skill than gastric ESD. To perform esophageal ESD safely, we used a sodium hyaluronate solution (MucoUp) as the endoscopic submucosal injection material, and the stag beetle (SB) knife as the main device for esophageal ESD. Our aim was to evaluate the clinical safety and efficiency of MucoUp and the SB knife for esophageal ESD.

Method: A total of 84 patients with 110 esophageal lesions who were treated with ESD from January 2013 to June 2016 were analyzed. The lesions were evaluated using magnifying endoscopy with narrow-band imaging and chromoendoscopy with Lugol's solution. All diagnoses were confined with histologic evaluation through biopsy. Prior to ESD, routine blood tests and computed tomography to evaluate lymph node and distant metastasis were performed for all patients. In addition, the tumor invasion depth was evaluated as necessary, using endoscopic ultrasound. All ESD procedures used MucoUp as the submucosal injection material and the SB knife as the main device for esophageal ESD.

Result: There were 78 male and 6 female patients, and average age was 69.7 years (range, 50 to 87 years). There were 19 patients with 45 multiple lesions (13 patients with 2 lesions, 5 patients with 3 lesions, and 1 patient with 4 lesions). Four lesions were excluded because they were diagnosed as nonepithelial tumors (leiomyoma in 2, granular cell tumor in 1 and undetermined in 1). The mean tumor size was 40.4 mm (range, 13 mm to 122 mm). A mean operative time was 45.3 min (range, 8 min to 132 min). The mean 3.9 vials (range, 2 to 12 vials) of MucoUp were used. The *en bloc* resection rate and R0 resection rate were 100% and 92.7%, respectively. There were no significant complications such as perforation, bleeding, or mediastinal emphysema. Postoperative esophageal stricture occurred in eight patients, all of whom were treated with endoscopic balloon dilation.

Conclusion: MucoUp and the SB knife are safe and effective agents that are useful for submucosal injection and do not cause any significant adverse events during endoscopic submucosal dissection.

Keywords: Endoscopic submucosal dissection; Sodium hyaluronate solution; Stag beetle knife; Submucosal injection; Superficial esophageal neoplasm

Introduction

Progress in the development of endoscopic diagnosis, such as narrow-band imaging (NBI), have increased the early detection of superficial esophageal neoplasms [1]. Endoscopic treatment has been broadly applied to superficial esophageal neoplasms because of its convenience and minimal invasiveness.

Endoscopic mucosal resection (EMR) was developed as an alternative to surgical therapy. However, EMR is limited in resection size. Therefore, piecemeal resection is performed for large lesions, resulting in imprecise histological evaluations and a high frequency of local recurrence.

In contrast, endoscopic submucosal dissection (ESD), which was developed in the 1990s for the surgical treatment of gastric cancer, allows for *en bloc* resection regardless of the tumor size and enables the precise histological evaluation of specimens [2,3]. In Japan, because of its minimal invasiveness, ESD was introduced for use in the esophagus and received health insurance approval in April 2008.

However, esophageal ESD requires greater skill than gastric ESD due to the narrow lumen and thin wall of the esophagus, which move continuously with respiration and cardiac pulsation, increasing the difficulty of endoscopic procedures. This can result in life-threatening complications

OPEN ACCESS

*Correspondence:

Shinsuke Nawa, Department of Gastroenterology, Kyoritsu General Hospital, 4-33 Goban-cho, Atsuta-ku, Nagoya 456-8611, Japan, Tel: +81-52-654-2211, Fax: +81-52-651-7210; E-mail: collie@tj9.so-net.ne.jp

Received Date: 09 Jun 2017

Accepted Date: 01 Sep 2017

Published Date: 10 Sep 2017

Citation:

Nawa S, Honma K. Stag Beetle Knife and 0.4% Sodium Hyaluronate in Esophageal Endoscopic Submucosal Dissection. J Gastroenterol Hepatol Endosc. 2017; 2(3): 1016.

Copyright © 2017 Shinsuke Nawa.

This is an open access article distributed under the Creative Commons Attribution License, which permits unrestricted use, distribution, and reproduction in any medium, provided the original work is properly cited.

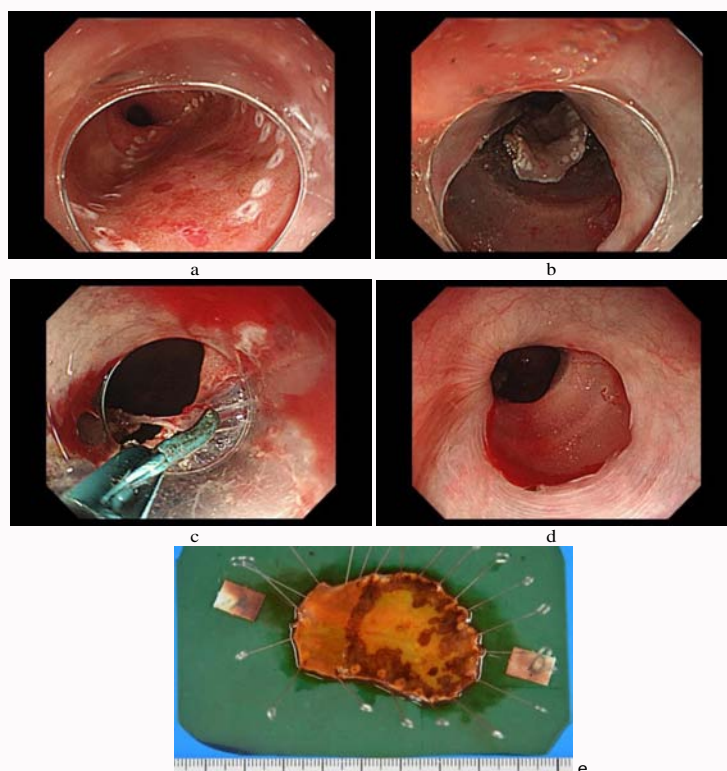


Figure 1: The method of esophageal endoscopic submucosal dissection (ESD). a) Marking around the lesion. b) Mucosal incision. c) Submucosal dissection with an SB (stag beetle) knife. d) Mucosal defect after the ESD. e) Resected en bloc specimen.

such as perforation and mediastinal emphysema. Furthermore, fever or mediastinal emphysema without perforation can occur if the muscular layer is exposed, and post-ESD esophageal strictures can occur after complete or semi-circumferential resection.

In recent years, esophageal ESD has become safer owing to development of various devices, such as the insulated-tip diathermic knife (ITknife2) [2] and the stag beetle (SB) knife [4], along with the use of submucosal injection materials, that aid in lifting the mucosa. Accordingly, ESD is now recognized as one of the standard treatments for superficial esophageal neoplasms.

The technique of submucosal injection is a standard practice in the EMR of gastrointestinal lesions and it can reduce the incidence of complications such as perforation or bleeding. Sodium hyaluronate solution is widely used as an endoscopic submucosal injection material [5,6]. MucoUp (Seikagaku Corporation, Tokyo, Japan), which is distributed as an 80 mg/20 mL vial of 0.4% sodium hyaluronate, was approved for insurance coverage for esophageal EMR/ESD in January 2014.

The SB knife (MD-447707; Sumitomo Bakelite, Tokyo, Japan) is a new scissor-type of forceps marketed for the first time. The advantage of this knife is that the target lesion can be grasped with precision despite cardiac and respiratory movements.

In this study, we retrospectively evaluated the clinical safety and efficiency of MucoUp and the SB knife for esophageal ESD in our hospital.

Methods

Patients

A total of 87 patients with 114 esophageal lesions treated with

ESD from January 2013 to June 2016 at Nihonkai General Hospital were enrolled.

The lesions were evaluated using magnifying endoscopy with narrow-band imaging and chromoendoscopy with Lugol's solution. All diagnoses were confirmed with histological evaluation through biopsy.

Prior to ESD, routine blood tests and computed tomography were performed for all patients to evaluate for lymph node and distant metastasis. In addition, the tumor invasion depth was evaluated, as necessary, using endoscopic ultrasound.

Patients who had a low performance status or severe complications were excluded from the study.

Written informed consent was obtained from all patients before they underwent esophageal ESD.

Esophageal ESD procedure

Esophageal ESD was performed with the patients under conscious sedation after intravenous administration of flunitrazepam and pentazocine.

A single-channel endoscope (GIF-Q260J; Olympus, Tokyo, Japan) and a high-frequency electric surgical unit (ESG-100, Olympus) were used with an ITknife2 (KD-611L, Olympus) and an SB knife (MD-447707; Sumitomo Bakelite, Tokyo, Japan).

The esophageal ESD procedure included the following steps.

i) Marking around the lesion: Using the tip of the electrosurgical knife, dots were placed outside of the margin of the target lesion at approximately 2-mm intervals.

ii) Submucosal injection: Using a 5-mL syringe, MucoUp was

injected into the submucosa to elevate the lesion. MucoUp was combined with 0.1 mL of 0.1% epinephrine and a small quantity of dye solution, which were used to prevent bleeding and to distinguish the injected from the non-injected area, respectively.

iii) Mucosal incision: After precutting, a circumferential incision was made around the lesion using an ITknife2.

iv) Submucosal dissection: From the proximal to the distal end of the target lesion, submucosal dissection was performed using an SB knife (Figures 1A-1E).

During the ESD procedure, bleeding points were coagulated with hemostatic forceps or an SB knife, in soft coagulation mode.

The maximum diameter of the lesion was considered the lesion size.

The operative time was calculated from the beginning of the mucosal marking to the end of the submucosal dissection.

Complications

Complications associated with the ESD procedure were diagnosed as follows.

Procedure-related perforation was diagnosed endoscopically, and mediastinal emphysema was diagnosed by the presence of free air on a plain X-ray or chest computed tomography (CT) immediately after ESD.

Procedure-related bleeding was diagnosed when a bleeding that required transfusion or surgical intervention occurred, or a decreased blood hemoglobin level >2g/dL was observed 5 days after the ESD that was accompanied by hematemesis or melena.

Post-ESD esophageal stricture was diagnosed when either dysphagia occurred after the operation that required endoscopic treatment or a standard endoscope (GIF-Q260) could not be passed through the ESD scar.

Histological findings

Histologic evaluation was performed to assess the tumor size, invasion depth, lymphovascular invasion, histological diagnosis, and resection margin.

En bloc resection was defined as the removal of the lesion in one piece. R0 resection was defined as *en bloc* resection with tumor-free lateral/vertical margins, and R1 resection was defined as positive lateral/vertical margins.

Curative resection was defined as R0 resection for pathologically confirmed intramucosal (EP (carcinoma *in situ*)/LPM (invading the lamina propria mucosae)) tumor without lymphovascular invasion. Adenocarcinomas were excluded from the calculation of the curative resection rate.

A carcinoma that extended up to 200 μ m below the lower border of the lamina muscularis mucosae was defined as SM1.

A carcinoma that extended more than 200 μ m below the lower border of the lamina muscularis mucosae was defined as SM2.

Follow-up

All patients underwent upper gastrointestinal endoscopy with Lugol's solution every 3, 6, and 12 months after ESD, in order to check for recurrence. Thereafter, follow-up endoscopy was performed every 6 to 12 months until September 2016. Follow-up computed

Table 1: Clinical findings of the patients and tumors.

Number of patients/lesions	84/110
Sex: M/F	78/6
Age (years)	69.7 (50-87)
Tumor location in the esophagus	
Upper third	13 (11.8%)
Middle third	71 (64.5%)
Lower third	20 (18.2%)
Esophagogastric junction	6 (5.5%)
Lesion size (mm)	40.4 (13-122)
Maximum diameter (<50 mm/50 mm \leq)	83/27
Circumference	
<1/2	66 (60%)
<3/4	35 (31.8%)
>3/4	9 (8.2%)
Operative time (min)	45.3 (8-132)
Amount of MucoUp used (no. of vials)	3.9 (2-12)

Table 2: Treatment outcomes.

<i>En bloc</i> resection, n (%)	110/110 (100%)
R0 resection, n (%)	102/110 (92.7%)
Curative resection, n (%)	88/110 (80.7%)
Lateral margin (+)	7 (6.4%)
Vertical margin (+)	2 (1.8%)
Hemorrhage, n (%)	0 (0%)
Perforation, n (%)	0 (0%)
Stricture, n (%)	8 (9.5%)
Histology	
squamous cell carcinoma (SCC)	76 (69.1%)
high-grade intraepithelial neoplasia (HGIN)	22 (20%)
adenocarcinoma	4 (3.6%)
neuroendocrine tumor (NET)	1 (0.9%)
low-grade intraepithelial neoplasia (LGIN)	7 (6.4%)
Depth of invasion of SCC	
EP	19 (25%)
LPM	46 (60.5%)
MM	6 (7.9%)
SM1	2 (2.6%)
SM2	3 (3.9%)

tomography was performed annually if the patients did not have a curative resection.

Results

Patients

The clinical findings of the patients and tumors are shown in Table 1. A total of 110 lesions in 84 patients were analyzed. Four lesions were excluded because they were diagnosed as nonepithelial tumors (leiomyoma in 2, granular cell tumor in 1 and undetermined in 1). One of the four patients who had these nonepithelial tumors had other epithelial lesion and was not excluded. There were 78 male and 6 female patients with an average age of 69.7 years (range, 50 to 87 years). There were 19 patients with 45 multiple lesions (13 patients with 2 lesions, 5 patients with 3 lesions, and 1 patient with 4 lesions).

The mean lesion size was 40.4 mm (range, 13 mm to 122 mm).

An average of 3.9 vials (range, 2 to 12 vials) of MucoUp (80 mg/20 mL per vial) was used.

The mean operative time was 45.3 min (range, 8 min to 132 min) in 81 lesions with data on operative time.

No perforation occurred during ESD.



Figure 2: Distal tip of the ITknife2 (insulated-tip diathermic knife).

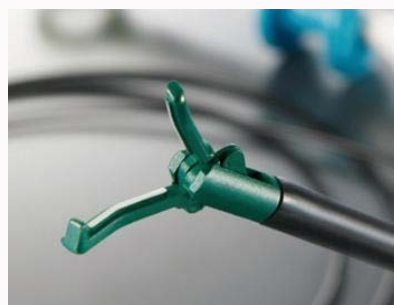

Figure 3: Distal tip of the SB (stag beetle) knife.

No procedure-related bleeding or perforation was noted.

Histological findings

The treatment outcomes are shown in Table 2. The histologic diagnosis of the 110 lesions was squamous cell carcinoma (SCC) in 76 (69.1%), high-grade intraepithelial neoplasia (HGIN) in 22 (20%), adenocarcinoma in 4 (3.6%), neuroendocrine tumor (NET) in 1 (0.9%), and low-grade intraepithelial neoplasia (LGIN) in 7 (6.4%).

All lesions were resected in an *en bloc* fashion. R0 resection was accomplished in 102 of the 110 lesions (92.7%). R1 resection was performed for 8 lesions. Six lesions had a positive lateral margin, 1 lesion had a positive vertical margin, and 1 lesion had both positive lateral and vertical margins.

The invasion depth of SCC (76 lesions) was EP in 19 (25.0%), LPM in 46 (60.5%), MM (invading the muscularis mucosae) in 6 (7.9%), SM1 in 2 (2.6%), SM2 in 3 (3.9%).

Curative resection was accomplished in 88 of the 110 lesions (80.7%).

Noncurative resection was performed in 22 lesions. The histologic diagnosis of the 22 lesions in 21 patients was SCC in 14, adenocarcinoma in 4, HGIN in 3 and NET in 1.

R1 resection was performed in 8 lesions in 8 patients. The histologic diagnosis of the 8 lesions was SCC in 4, adenocarcinoma in 1, HGIN in 3. The invasion depth of the R1 resected SCC in 4 patients was EP/LPM in 2 and SM2 in 2. Three patients with SCC underwent an additional chemoradiation, and another patient was followed-up without treatment because of severe liver cirrhosis. One patient with adenocarcinoma (SM2, both positive lateral/vertical margins) underwent an additional esophagectomy. Three patients with HGIN that had positive lateral margins were followed up without treatment. In all cases of R1 resected lesions, no recurrence was noted.

The histologic diagnosis of the 14 remaining lesions, which were defined as noncurative resections with tumor-free margins, was SCC in 10, adenocarcinoma in 3, and NET in 1.

The invasion depth of the SCC (10 lesions) in 10 patients was LPM in 1, MM in 6, SM1 in 2, and SM2 in 1. Among the 5 patients with positive lymphovascular invasion (LPM in 1 and MM in 4), 3 patients (MM) underwent additional chemoradiation, while the others were followed up without treatment. Another 5 patients who had negative lymphovascular invasion (MM in 2, SM1 in 2, and SM2 in 1) were followed up without treatment. In all cases, no recurrence was noted.

Two of 3 patients diagnosed with adenocarcinoma (SM2, negative lymphovascular invasion) underwent additional esophagectomy.

Another patient (MM, negative lymphovascular invasion) was followed up without treatment. In all patients with adenocarcinoma, no recurrence was noted.

Long-term outcomes after ESD

Until September 2016, the mean postoperative follow-up period was 24.8 months (range, 3 to 44 months). After ESD, 6 patients were lost to follow-up: four patients discontinued follow-up after >1 year after treatment and 2 patients moved to another hospital.

Death caused by malignant tumors in other organs occurred in 3 of the remaining 78 patients (3.9%). No patients died from SCC. One patient who was diagnosed with NET and who did not want additional treatment was followed up and died 13 months after ESD.

Post-ESD stricture occurred in 8 of the 84 patients (9.5%). Seven of the 8 patients had lesions covering more than 3/4 of the circumference of the esophagus, and the other patient was treated for esophageal cancer recurrence after chemoradiation. The 8 patients with esophageal stricture were managed with endoscopic balloon dilation for a median of 4 sessions (ranging from 1 to 9 sessions). All of these patients experienced symptomatic improvement.

Since October 2015, endoscopic injections of triamcinolone acetonide (Kenacort; Bristol-Myers Squibb, Tokyo, Japan) have been administered to prevent strictures. In the present study, 4 patients received endoscopic triamcinolone injections owing to the extent of the resection based on the circumference. One patient had a 2/3 circumferential resection and 3 patients had a more than 3/4 circumferential resection. No esophageal strictures occurred after the injection of triamcinolone acetonide.

Discussion

Since the endoscopic treatment of superficial esophageal neoplasms is a minimally invasive treatment with few complications, T1a-MM or T1b-SM1 cancers are a relative indication for endoscopic treatment in Japanese esophageal cancer diagnosis and treatment guidelines [7]. A step-up strategy that involves an additional treatment based on the histological findings of the resected lesion using endoscopic treatment is also performed. For that purpose, an accurate pathological diagnosis of the *en bloc* resected specimen is necessary, regardless of the tumor size.

Our results showed an *en bloc* resection rate of 100% and an R0 resection rate of 92.7%. There were no major complications such as perforation, bleeding, or mediastinal emphysema.

It is believed that the submucosal injection of sodium hyaluronate creates adequate space to allow for safe endoscopic procedures [5,6].

Insufficient injection creates only a small space in the submucosal

layer, and the electrosurgical devices tend to contact the muscle, resulting in a high risk of perforation. To prevent perforation, it is necessary to ensure adequate space in the submucosal layer. An ideal endoscopic submucosal injection material should provide a thick submucosal fluid cushion that remains in the submucosal space long enough to perform ESD safely and to preserve tissue specimens for precise pathologic staging.

Hyaluronic acid is a type of glycosaminoglycan that is widely found in the connective tissues of mammals. It is a thick substance with a high viscosity and marked ability to retain water. Moreover, it is neither antigenic nor toxic to humans [8].

Submucosal injection of hyaluronic acid has been reported to lift the mucosa and maintain a large mucosal protrusion [9,10]. The use of hyaluronic acid as a submucosal injection material is recommended to maintain an elevated protrusion [11]. This makes it possible to resect safely with a large distance between the mucosa and muscle layer. Onaya et al. [12] reported that compared with other materials, such as normal saline, 50% dextrose, hypertonic saline (3.7% NaCl), and glycerol, a 0.4% hyaluronic acid solution injected into the submucosal layer of the stomach of live rabbits created a significantly larger protrusion. Yamamoto et al. [9] reported no significant differences in the histological findings for ulcers created with saline or sodium hyaluronate-assisted resections. Re-epithelialization was also seen in the ulcer edge. The anatomical structure of the esophagus is similar to that of the stomach. The EMR/ESD procedure, in which a submucosal injection to elevate the lesion and mucosal resection are performed, is commonly used in the treatment of stomach and esophageal tumors.

In Japan, some studies have reported the usefulness of MucoUp in esophageal ESD. An *en bloc* resection rate of 96.6% to 100% has been reported, and postoperative complications occurred in only 1 case with delayed perforation [13-15].

In the present study, a mean of 3.9 MucoUp vials were used in the procedures. Eleven patients required more than 6 vials. Nine patients had large lesions of >5 cm in maximum diameter. One patient had 2 lesions resected in 1 day. A greater amount of MucoUp was used for larger lesions. No relationship between adhesions and previous chemoradiation or ESD was found.

The ITknife2 was used for mucosal incision in all patients. This knife consists of a small ceramic ball attached to the tip of the blade. On the base of the ceramic ball are 3 short radial blades (Figure 2). This ceramic ball functions as an insulator so that the incision and dissection of the mucosa and submucosa can be performed safely and quickly [16]. To prevent perforation, it is important that the short blades do not face the muscular layer.

The SB knife was used for the submucosal dissection in all patients. The SB knife is a scissor-type of forceps that is coated with electrical insulation except for the edge of the blade (Figure 3). The advantage of this knife is that the target lesion can be grasped with precision despite cardiac and respiratory movements. There is no need to move the endoscope during incision and dissection [17].

This single center, retrospective, uncontrolled study had some limitations. In our hospital, all cases of esophageal ESD procedure were performed with MucoUp as the submucosal injection material and the SB knife as the main device. Therefore, we compared our outcomes with the outcomes of other institutions.

Among the lesions that were >5 cm in maximum diameter, the

en bloc resection rate was 100% (27 of 27) and the R0 resection rate was 96.3% (26 of 27). Oyama et al. [18] reported an *en bloc* resection rate of 99.3% (137 of 138), and an R0 resection rate of 88.4% (122 of 138) in a multicenter study in advanced institutions. The results of our study were not inferior to those of previous studies.

Conclusion

Based on the results of previous studies and the present study, the combination of MucoUp and the SB knife is useful in esophageal ESD. MucoUp is a safe and effective agent that does not cause any significant adverse events and effective facilities for submucosal injection during ESD.

Although esophageal ESD is more difficult than gastric ESD, the use of MucoUp makes esophageal ESD safer and more complete. However, further data on ESD-related treatment outcomes from randomized controlled studies are necessary to evaluate the clinical safety and efficiency of MucoUp compared with other submucosal injection materials.

References

1. Arima M, Tada M, Arima H. Evaluation of microvascular pattern of superficial esophageal cancers by magnifying endoscopy. *Esophagus*. 2005;2(4):191-7.
2. Ono H, Kondo H, Gotoda T, Shirao K, Yamaguchi H, Hosokawa K, et al. Endoscopic mucosal resection for treatment of early gastric cancer. *Gut*. 2001;48(2):225-9.
3. Oyama T, Kikuchi Y, Tomori A, Hotta K, Shimatani S, Miyata Y, et al. Endoscopic mucosal resection using hooking knife for esophageal early cancer. *Clin Gastroenterol*. 2001;16(12):1609-15.
4. Honma K, Kobayashi M, Watanabe H, Suga T, Tominaga K, Yamagata M, et al. Endoscopic submucosal dissection for colorectal neoplasia. *Dig Endosc*. 2010;22(4):307-11.
5. Yamamoto H, Yahagi N, Oyama T, Gotoda T, Doi T, Hirasaki S, et al. Usefulness and safety of 0.4% sodium hyaluronate solution as a submucosal fluid "cushion" in endoscopic resection for gastric neoplasms: a prospective multicenter trial. *Gastrointest Endosc*. 2008;67(8):830-9.
6. Hirasaki S, Kozu T, Yamamoto H, Sano Y, Yahagi N, Oyama T, et al. Usefulness and safety of 0.4% sodium hyaluronate solution as a submucosal fluid "cushion" for endoscopic resection of colorectal neoplasms: a prospective multi-center open-label trial. *BMC Gastroenterol*. 2009;9:1.
7. The Japan Esophageal Society. Diagnosis and Treatment Guideline of the Japan Esophageal Society for Cancer of the Esophagus. Kanehara Syuppan, Tokyo, Japan; 2012.
8. Balazs E, Denlinger J. Clinical uses of hyaluronan. *Ciba Found Symp*. 1989;143:265-75.
9. Yamamoto H, Yube T, Isoda N, Sato Y, Sekine Y, Higashizawa T, et al. A novel method of endoscopic mucosal resection using sodium hyaluronate. *Gastrointest Endosc*. 1999;50(2):251-6.
10. Fujishiro M, Yahagi N, Kashimura K, Mizushima Y, Oka M, Matsuura T, et al. Different mixtures of sodium hyaluronate and their ability to create submucosal fluid cushions for endoscopic mucosal resection. *Endoscopy*. 2004;36(7):584-9.
11. Japan Gastroenterological Endoscopy Society. *Gastroenterology Endoscopy Handbook*. Nihon Medical Center, Tokyo, Japan; 2012.
12. Onaya J, Yoshioka K, Zuinenn R, Hoshino J, Minamisawa Y, Takahashi T, et al. Evaluation of hyaluronan as an endoscopic submucosal injectant. *Endoscopia Digestiva*. 2008;20(2):242-8.
13. Toyonaga T, Man-I M, Fujita T, Nishio E, Ono W, Morita Y, et al. The

- performance of a novel ball-tipped Flush knife for endoscopic submucosal dissection: a case-control study. *Aliment Pharmacol Ther.* 2010;32(7):908-15.
14. Motohashi O, Nishimura K, Nakayama N, Takagi S, Yanagida N. Endoscopic submucosal dissection (two-point fixed ESD) early esophageal cancer. *Dig Endosc.* 2009;21(3):176-9.
15. Minami H, Inoue H, Ikeda H, Sato Y, Kaga M, Sugaya S, et al. Endoscopic submucosal dissection using the triangle tip knife. *Stomach Intest.* 2009;44(3):374-7.
16. Kawata N, Ono H. Characteristic and effective use of the IT knife family. *Endoscopia Digestiva.* 2014;26(9):1343-8.
17. Honma K, Nawata Y, Miura T, Kobayashi M. How to use the SB knife safely and effectively. *Endoscopia Digestiva.* 2014;26(9):1385-91.
18. Oyama T, Takahashi A, Takeuchi M, Ishihara R, Yamashita T, Ono H, et al. Long-term prognosis of superficial esophageal cancer of at least 50 mm in diameter treatment by endoscopic submucosal dissection. *Stomach Intest.* 2014;49(8):1182-89.