World Journal of Oral and Maxillofacial Surgery

Case Presentation
Published: 21 Oct, 2019

Sixteen Persistent Primary Teeth in Maxillary and Mandibular Arch of an Adult: A Rare Case Presentation

*Nyer Firdoose**

Department of Oral and Maxillofacial Surgery, East Riyadh Specialized Centre, Saudi Arabia

Abstract

A primary tooth is considered persistent/over-retained if the last eruption time of the permanent successor tooth had been expired for more than one year and if the primary teeth did not exfoliated yet. The most common type of persistent primary teeth seen on the dental arch was mandibular primary second molars, followed by maxillary primary canines. The following manuscript presents a rare occurrence of sixteen such teeth in both maxillary and mandibular arches of an adult aged 17 years.

Introduction

Primary teeth are occasionally found in adults. A primary tooth is considered persistent if the last eruption time of the permanent successor tooth had been expired for more than one year and if the primary teeth did not exfoliated yet. The congenital absence of the permanent successor teeth was found to be the most common reason for the persistence of primary teeth, followed by impaction, abnormal position, and late eruption of successor teeth.

Based on the previous literature available it is well known fact that the primary mandibular second molars were the most frequently retained deciduous teeth, followed by the right and left primary maxillary canines and second molars on both sides. Persistence of other primary teeth was relatively rare. The previous studies also that showed the prevalence of tooth agenesis and the relationship between agenesis of permanent teeth and the persistence of primary teeth [1-4]. Therefore, primary mandibular second molars persist most often due to most common developmental absence of permanent mandibular second premolars which are their successors. Similarly, the most frequent impaction of maxillary permanent canines leads to second most common persistence rate of primary maxillary canines. In the light of these findings, the results of the present study indicate that persistence of primary teeth may be related to developmental anomalies of their permanent successors.

There is very less literature pertaining to persistent teeth in adult, their diagnosis and management. The following manuscript aims at detailing the possible etiologies, diagnosis and its management in adults by illustrating a case report of rare combination of fifteen such teeth in both maxillary and mandibular arches of an adult female 17 years aged, a rare of its kind in the available literature.

Case Presentation

Routine radiographic investigation pertaining to the chief compliant of the patient the panaromic radiograph revealed the incidental findings such as shown in Figure 1.

These teeth did have their respective permanent successors. The clinical and radiographic examinations of our case revealed relatively normal jaws and oral soft tissues.

Discussion

Common local causes for over-retained deciduous teeth are malposition of the tooth germ, abnormal resorption of the roots, ankylosis, supernumerary teeth in the path of eruption, and agenesis of the replacing tooth.

If the root and coronal structure of persistent teeth are good, the tooth is functionally and aesthetically acceptable, and then there is no compelling orthodontic need for extraction of intact over retained primary tooth. Where root and crown structure are good, but infra-occlusion has occurred or aesthetic improvement is required, the primary tooth may be retained and reshaped

OPEN ACCESS

Correspondence:
Nyer Firdoose, Department of Oral and Maxillofacial Surgery, East Riyadh Specialized Centre, Ministry of Health, Ishbiliyah, Riyadh, 13226, Saudi Arabia, E-mail: drnyeromfs@gmail.com

Received Date: *25 Sep 2019*
Accepted Date*: 15 Oct 2019*
Published Date*: 21 Oct 2019*

Citation:
Firdoose N. Sixteen Persistent Primary Teeth in Maxillary and Mandibular Arch of an Adult: A Rare Case Presentation. World J Oral Maxillofac Surg. 2019; 2(4): 1033.

Copyright *© 2019 Nyer Firdoose. This is an open access article distributed under the Creative Commons Attribution License, which permits unrestricted use, distribution, and reproduction in any medium, provided the original work is properly cited.*

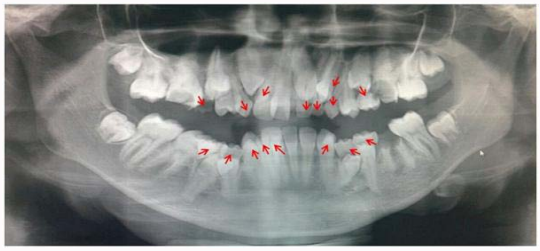

Figure 1: Panoramic radiograph revealing the presence of 16 over retained deciduous teeth.

with direct composite or indirect restorations, such as composite, porcelain, or gold onlays.

Where crowding exists, and an extraction is necessary to align the arch orthodontically, it is usually common to extract the primary teeth. If the arch is well aligned, but the prognosis of the primary teeth is poor due to root resorption, caries, periodontal or periapical disease, or insufficient aesthetics, extraction and prosthetic replacement may be necessary, such as fixed replacement, conventional bridge, resin bonded bridge, dental implant supported crown, or bridgework.

Treatment options for the management of impacted teeth are separated into four categories: Observation, intervention, relocation, and extraction. Each strategy has to be judged according to individual case, taking into consideration the position of the impacted teeth and the relationship to each on X-ray images, oral examination, and plaster model [5].

In this case, after taking into consideration various factors, it was decided to go for extraction of persistent deciduous teeth, followed by surgical exposure and orthodontic traction of impacted teeth. However, patient was not willing for any kind of surgical treatment and was lost to follow-up.

This case report adds to rare reported literature on multiple retained primary teeth along with impacted permanent teeth. Early diagnosis with advanced imaging and appropriate management can minimize the potential complications caused by such impacted teeth. Dental practitioners should be aware of their clinical signs and the treatment options. Further research is needed at cellular and genetic levels to exactly localize the reasons for such failure of eruption.

Conclusion

Persistent primary teeth in adults results in poor oral hygiene due to difficulty in brushing also they may further complicate by causing non- eruption or delayed eruption of permanent teeth. Its prompt diagnosis with thorough evaluation is necessary to execute an appropriate treatment plan for the well being of the patient. Treatment may vary from simple extraction to extraction followed by orthodontic treatment.

References

1. Aktan AM, Kara İ, Şener İ, Bereket C, Çelik S, Kırtay M, et al. An evaluation of factors associated with persistent primary teeth. Eur J Orthod. 2011;34(2):208-12.
2. Nordquist I, Lennartsson B, Paulander J. Primary teeth in adults--a pilot study. Swed Dent J. 2005;29(1):27-34.
3. Roy S. Management of over-retained mandibular deciduous second molars with and without permanent successors. World J Orthod. 2008;9(3):209-20.
4. Deepa D, Rana Nazar, Arun Kumar KV. Non-syndromic bilateral multiple retained primary incisors in mandibular arch: A rare case report. 2016;8(2):79-81.
5. Bhatia V, Jain N, Bhatia N, Garg R. A 25-year-old man with 50 teeth: Astonishing but true. J Nat Sci Biol Med. 2013;4(2):472-5.