



## Sister Mary-Joseph's Nodule Revealing a Digestive or Gynecological Carcinoma: About 5 Cases

Tamegnon D<sup>1\*</sup>, Kokou K<sup>1</sup>, Iroukora K<sup>2</sup>, Yendoubé K<sup>3</sup>, Ayi A<sup>4</sup>, Boyodi T<sup>4</sup>, Komlan A<sup>4</sup>, Foussemi A<sup>4</sup>, Samadou AA<sup>3</sup> and David DE<sup>4</sup>

<sup>1</sup>Department of General Surgery, Kara Teaching Hospital, Togo

<sup>2</sup>Department of General Surgery, Kara-Tomdè Hospital, Togo

<sup>3</sup>Department of Gynecology, Kara Teaching Hospital, Togo

<sup>4</sup>Department of General Surgery, Sylvanus Olympio of Lomé Teaching Hospital, Togo

### Abstract

Sister Mary-Joseph nodule is an umbilical skin metastasis from a malignant tumor of abdominal origin. It is a rare and late clinical sign, indicative of an advanced stage of digestive or ovarian carcinoma. We report five cases of an umbilical skin metastasis revealing a colonic tumor in 3 cases and an ovarian tumor in two cases. Through five cases we want to describe the epidemiological, diagnostic, therapeutic and prognostic peculiarities of Sister Mary-Joseph's nodule.

**Keywords:** Sister Mary-Joseph nodules; Umbilical metastasis; Computed tomography; Carcinoma biopsy; Togo

### Introduction

The umbilicus is the parietal scar left by the insertion of the cord. It maintains relations with the intra-abdominal organs. It is sometimes the elective seat of infectious, malformative, inflammatory and tumor of skin diseases [1,2]. Malignant tumor lesions are primary or secondary. The secondary lesion is represented by Sister Mary-Joseph's nodule, which is an umbilical skin metastasis from digestive or gynecological cancer [2]. The objective of this work is to show, through five cases of Sister Mary-Joseph's nodule, the diagnostic, therapeutic and prognostic features of this condition in developing countries.

### OPEN ACCESS

#### \*Correspondence:

Dossouvi Tamegnon, Department of General Surgery, Kara Teaching Hospital, PO BOX: 18, Kara, Togo,

E-mail: dboris@ymail.com

Received Date: 14 Apr 2021

Accepted Date: 04 Jun 2021

Published Date: 07 Jun 2021

#### Citation:

Tamegnon D, Kokou K, Iroukora K, Yendoubé K, Ayi A, Boyodi T, et al. Sister Mary-Joseph's Nodule Revealing a Digestive or Gynecological Carcinoma: About 5 Cases. *Am J Cancer Res Ther.* 2021; 1(1): 1003.

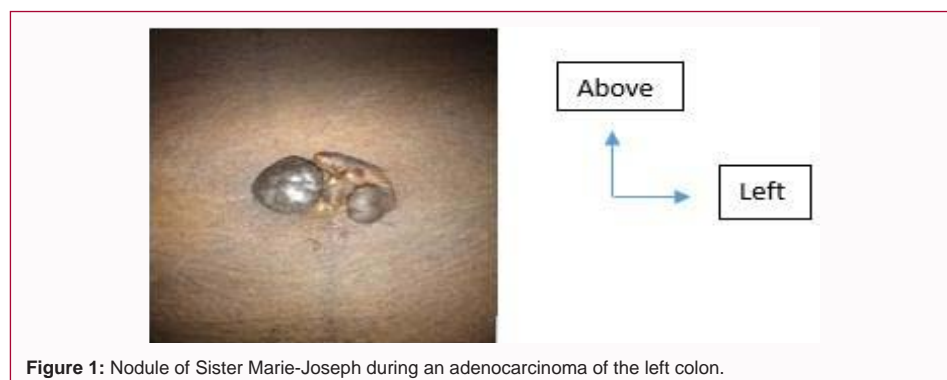**Copyright** © 2021 Tamegnon D. This is an open access article distributed under the Creative Commons Attribution License, which permits unrestricted use, distribution, and reproduction in any medium, provided the original work is properly cited.

#### Observation 1

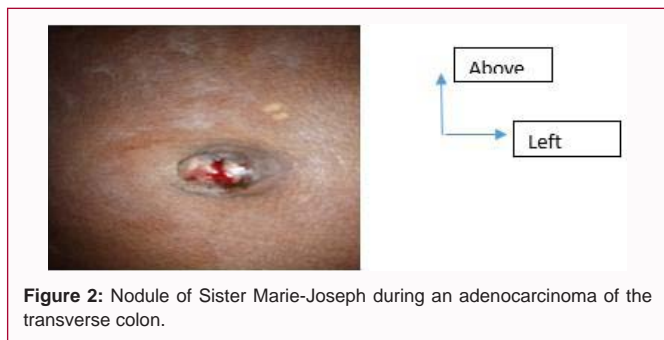A 70-year-old patient, known hypertensive, admitted in emergency for umbilical and periumbilical pain evolving for more than 72 h. The examination showed apyrexia; a deterioration of the general condition; the abdomen was of normal size without scar, with the presence of an umbilical nodule, hard and tender. The hernial orifices and ganglionic areas were free; no rectal nodule. Abdominal Computed Tomography (CT) noted a tumor in the left colon with nodules of peritoneal carcinoma. Biopsy of the nodule noted an undifferentiated adenocarcinoma of colonic origin. He was put on chemotherapy. The outcomes were marked by death a few months later.

#### Observation 2

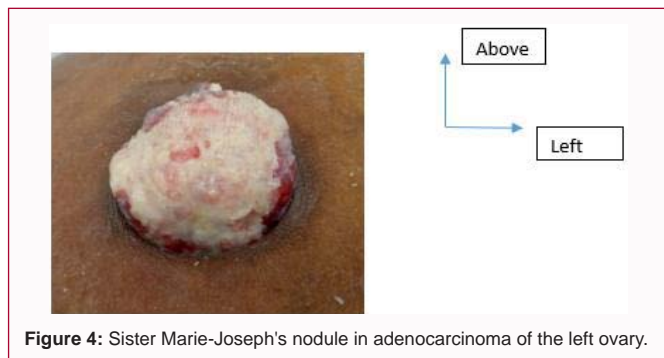
A 38-year-old patient, with no specific history, admitted for an abdominal mass in a context of deterioration of general condition, evolving for weeks without notion of transit disorders. The



**Figure 1:** Nodule of Sister Marie-Joseph during an adenocarcinoma of the left colon.



**Figure 2:** Nodule of Sister Marie-Joseph during an adenocarcinoma of the transverse colon.



**Figure 4:** Sister Marie-Joseph's nodule in adenocarcinoma of the left ovary.

clinical examination revealed apyrexia; a deterioration of the general condition; an abdomen of normal size without a scar; the presence of a weeping, painful umbilical nodule measuring 3 cm in diameter on its longest axis; an abdominal mass adhering to the deep plane and the umbilicus; the lymph node areas were free. The diagnostic hypothesis of an abdominal tumor was posed. The abdominal ultrasound revealed an abdominal tumor developed on a digestive structure and adherent to abdominal wall with ascites of minimal abundance. Exploratory laparotomy noted a transverse colon tumor invading the stomach with peritoneal carcinoma. A right hemicolectomy with transverse ileocolic anastomosis and an atypical partial gastrectomy were performed. The biopsy was in favor of adenocarcinoma of the transverse colon. The diagnosis of transverse colon adenocarcinoma with umbilical metastasis was made. Due to lack of funds, the patient was unable to benefit from adjuvant chemotherapy. The postoperative follow-up was good. The patient reviewed for control 1, 3 and 6 months later had a satisfactory physical state with regular weight gain.

**Observation 3**

A 68-year-old woman with a history of hysterectomy was admitted with diffuse abdominal pain that had progressed for months without transit problems. The clinical examination noted apyrexia, a change in general condition. The abdomen was enlarged, with the presence of a Pfannenstiel scar, a hard, tender umbilical nodule, a right pelvic mass. Abdominal Computed Tomography (CT) revealed a right ovarian tumor with peritoneal carcinoma. The umbilical nodule biopsy suggested a serous adenocarcinoma. The diagnosis was cancer of the right ovary with umbilical and peritoneal metastases. Management was limited to symptomatic treatment. The death occurred 2 weeks after his admission.

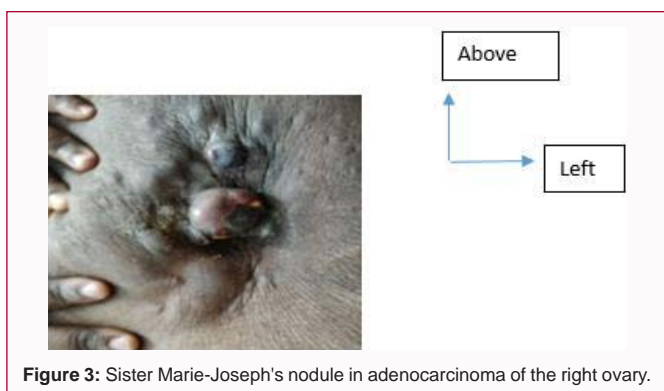
**Observation 4**

A 56-year-old woman with a history of left total salpingectomy for a ruptured left ectopic pregnancy in 1990 and a cesarean section

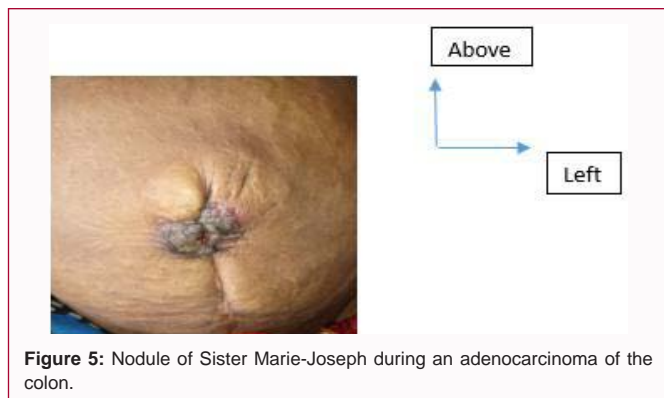
in 1997, admitted for abdominal distension which had progressed for one month in a context of progressive deterioration of the general condition. There was no metrorrhagia. The examination noted a change in general condition; an enlarged abdomen with elastic resistance; an ulcerative nodule, oozing from the umbilicus, measuring 4 cm in diameter in its longest axis and sensitive. Elsewhere, there was a free ascites of great abundance with umbilical perimeter at 128 cm, a tumor-like hepatomegaly. The cytochemical examination of the ascites showed an exudate with the presence of a few clusters of suspicious cells. CA-125 was elevated to 997 U/ml (N<35 U/ml). Carcinoembryonic Antigen (CEA), alpha-fetoprotein and CA19-9 were normal. Abdomino-pelvic CT revealed a left ovarian cystic mass of 3.5 cm consistent with an ovarian tumor, an umbilical parietal mass of 4 cm x 3 cm of suspicious appearance, a homogeneous hepatomegaly with irregular contours without an abnormality of the portal vein and free ascites of great abundance. The umbilical nodule biopsy was in favor of a well differentiated adenocarcinoma. The diagnosis retained was cancer of the left ovary with umbilical and hepatic metastases. She is currently receiving symptomatic treatment due to lack of funding for chemotherapy.

**Observation 5**

An 86-year-old patient with a history of caesarean section admitted for abdominal pain, vomiting and transit arrest progressing approximately one week before admission. The examination revealed apyrexia; a deterioration of the general condition; a median subumbilical scar; an enlarged abdomen with elastic resistance; an umbilical nodule about 1 cm in diameter, hyperpigmented polylobed, indurated, tender to palpation; free hernial orifices; free ganglionic areas; the empty rectal bulb with soft rectal walls. The rest of the exam unremarkable. An X-ray of the abdomen without preparation made demonstrated water-arsenic levels in favor of colonic occlusion. We strongly suspected a colonic tumor in occlusion. The biopsy could not be performed due to lack of financial means. The patient died a



**Figure 3:** Sister Marie-Joseph's nodule in adenocarcinoma of the right ovary.



**Figure 5:** Nodule of Sister Marie-Joseph during an adenocarcinoma of the colon.

few days later.

## Discussion

Sister Marie Joseph's Nodule (SMJ) is a nodular umbilical metastasis of an intra-abdominal tumor of digestive or pelvic origin. It may be the first manifestation of an intra-abdominal tumor as in our first case [3]. This nodule is rare with an incidence varying between 1% to 3% of patients with intra-abdominal neoplasia [3]. These neoplastic nodules represent approximately 30% of all umbilical tumors [1]. Primary tumors are of gastrointestinal origin in 35% to 65%, genitourinary in 12% to 35%, unknown in 15% to 30% and of thoracic origin (lungs and breasts) in 3% to 6% [4]. In our series we had only two colonic and ovarian locations with a predominance of the first.

The pathophysiological mechanism can be explained by peritoneal infiltration, migration of cancer cells through the umbilical venous system, umbilical arterial system, lymphatic drainage, falciform ligament, round ligament and urachus [5-7]. In addition, direct implantation during laparoscopy is another mode of tumor spread to the umbilicus [3].

The typical clinical appearance of JMS nodule is a generally firm, indurated swelling with irregular margins; the surface is sometimes cracked or ulcerative, often painful or even itchy. The size is variable, from 0.5 cm to 2 cm in general. A few spectacular cases up to 10 cm have been reported. Depending on the histological origin, there may be serous, blood, mucoid or purulent discharge [1].

An umbilical nodule can recognize several other pathologies including sarcoma, endometriosis, melanocytic nevus, lymphangioma, lipoma, granuloma, endometriosis, dermatofibroma, urachic cyst, seborrheic keratosis, pilonidal cyst, talc granuloma, pyogenic granuloma, omphalitis, keloid, foreign body, abscess, see hernia [1,3,8,9]. Only a biopsy with histological examination can make the differential diagnosis.

Imaging, including ultrasound and computed tomography, will help find the primary tumor [3,9].

The prognosis after the diagnosis of JMS nodule is unfavorable, with an average life expectancy of ten to eleven months [10,11].

A radical surgical procedure with adjuvant chemotherapy is associated with a better prognosis with a longer life expectancy compared to surgery or chemotherapy alone [10].

In our countries where the means of treatment are limited, the exploration of a nodule of JMS poses major diagnostic and therapeutic problems. In our study, the late diagnosis in our 5 patients is partly due to the lack of awareness of the nodule by practitioners, its

discreet nature often trivialized by patients, the lack of accessibility to referral health structures and the absence of complementary exams as histology in our health structures [3]. This diagnosis at an advanced stage, as in all five patients in our study, coupled with the inaccessibility of chemotherapy, constitute obstacles to optimal management in developing countries.

## Conclusion

Sister Marie-Josèphe's nodule is often a late indicator of abdomino-pelvic cancer. It may be the first manifestation of an intra-abdominal tumor. Its clinical, etiological and therapeutic diagnosis poses a problem in developing countries because of the limitation of the technical platform and the means of care which are often the responsibility of the patient. His prognosis is unfavorable.

## References

1. Kluger N. Umbilical and periumbilical dermatoses. *Ann dermatol vénérol.* 2014;141(3):224-35.
2. Gara S, Litaïem N, Boumaïza S, Chaabani M, Rammeh S, Jones M, et al. Nodule ombilical: Aspects épidémio-cliniques et étiologiques. *La Revue de Médecine interne.* 2019;40(2):133-4.
3. Touré PS, Tall CT, Dioussé P, Berthe A, Diop MM, Sarr MM, et al. Nodule de Soeur Marie-Josèphe révélateur de carcinomes digestif et ovarien: à propos de 4 cas. *Pan Afr Med J.* 2015;22:269.
4. Palaniappan M, Jose WM, Mehta A, Kumar K, Pavithran K. Umbilical metastasis: A case series of four Sister Joseph nodules from four different visceral malignancies. *Curr Oncol.* 2010;17(6):78-81.
5. Goyal S, Jain A, Goyal S. Umbilical cutaneous nodule: A diagnostic dilemma. *Clin Cancer Investig J.* 2014;3(5):420-2.
6. Agrawal V, Garg PK, Mohanty D, Jaswal V. Umbilical nodule in cholangiocarcinoma. *Saudi J Gastroenterol.* 2012;18(5):345-6.
7. Gabriele R, Conte M, Egidi F, Borghese M. Umbilical metastasis: Current viewpoint. *World J Surg Oncol.* 2005;3(1):313-5.
8. Ramia JM, de la Plaza R, López-Marcano A, Kuhnhardt A, David Gonzales J. Nódulo de la hermana María José: Metástasis umbilical de cancer de vesícula. *Gastroenterol Hepatol.* 2016;39(4):302-4.
9. Douhi Z, Mernissi FZ. Nodule de Soeur Marie-Joseph: Pensez à regarder le nombril. *Pan African Med J.* 2014; 18:289
10. Yoshinori I, Takashi K, Kenya K, Koji K, Daisuke H, Tomoyuki A. A long-term survival case of Sister Mary Joseph's nodule caused by colon cancer and treated with a multidisciplinary approach. *Nagoya J Med. Sci.* 2019;81:325-9.
11. Roth M, Bartz L, Rahm B, Honegger CM. Nodule de soeur Mary Joseph. Première manifestation d'un -carcinome endométrial ou ovarien. 2020;20(1112):201-3.