



Ruptured Hypogastric Aneurysm and Acute Myocardial Infarction: A Rare Case Report

Mariano E¹, Ascoli Marchetti A^{2*}, Volpe GA¹, Fabiano S³, Romeo F¹ and Ippoliti A²

¹Department of Cardiovascular, Tor Vergata University of Rome, Italy

²Department of Vascular Surgery, Tor Vergata University of Rome, Italy

³Department of Radiology, Tor Vergata University of Rome, Italy

Abstract

The simultaneous presence of aneurysm rupture and a myocardial infarction are rare and the recognition of the two pathologies can be a significant diagnostic problem. We report our experience with a patient with ruptured left hypogastric aneurysm and myocardial infarction, successfully treated and controlled after 12 months. The speed of treatment and the multidisciplinary approach are essential for success in cases like this.

Introduction

We report the case of a 53 years old man smoker and with previous diagnosis of hypertension that was admitted to our Emergency Department because of intense abdominal pain localized at left iliac fossa associated with profuse sweating followed by intense chest pain.

Case Report

After the hospital admission for abdominal pain, the male patient of 65 yrs old has an intense chest pain. The 12-lead ECG electrocardiographic monitoring performed in Emergency Department showed ST-segment elevation in anterior leads complicated by ventricular fibrillation at symptoms onset. The patient was promptly transferred in cath lab and subjected, from percutaneous right transfemoral access, to primary PCI with DES implantation because of tight stenosis in the middle segment of left anterior descending coronary artery with achievement of TIMI 3 flow and without administration of glycoprotein IIb - IIIa inhibitor agent. Procedure was free from relevant complications. ST-segment and chest pain resolution were promptly achieved. Control angiography at groin puncture level documented patent iliofemoral axis with mild atherosclerotic calcified plaque and no signs of bleeding.

The patient was then referred to coronary unit in stable haemodynamic conditions and asymptomatic for chest pain. Nevertheless, after a short time he underwent profound and rapid hypotension and poor general conditions associated with rapid lowering of hemoglobin levels. We rapidly decide performing thoracoabdominal computed tomography scanning with intravenous contrast in order to exclude retroperitoneal hematoma, aortic dissection, aneurysm, or thrombosis. Scanning clearly showed huge bleeding in abdomen especially at the level of left iliofemoral axis with the suspicion of vascular perforated mass at the same level. Blood and plasma transfusions were administered while vascular surgeon and interventional radiologist immediately performed lower limbs angiography that clearly documented patent right iliofemoral axis and absence of clear bleeding at the same site while ruptured huge aneurysm of left hypogastric artery was visualized. The aneurysm was then occluded with Amplatzer plug and implantation of covered stent at the level of left iliac artery. Final control angiography demonstrated complete resolution of vascular bleeding. During procedure patient was incubated and supported with inotropic drugs and blood transfusions. Moreover, haemodialysis was necessary because of acute renal failure while antibiotic therapy with ciprofloxacin and piperacillin was administered in the first days after percutaneous procedure because of augmentation of inflammation levels. Intensive care and drugs were slowly withdrawn and patient was discharged after fifteen days in optimal clinical conditions without any cardiac, renal, pulmonary or neurological sequelae. Actually, a rapid decision making of immediate coronary revascularization and emergent vascular procedure for ruptured aneurysm saved the patient's life in this case.

OPEN ACCESS

*Correspondence:

Ascoli Marchetti A, Department of Vascular Surgery, Tor Vergata University of Rome, Italy,

E-mail: ascolimarchetti@med.uniroma2.it

Received Date: 27 Mar 2018

Accepted Date: 26 Apr 2018

Published Date: 03 May 2018

Citation:

Mariano E, Ascoli Marchetti A, Volpe GA, Fabiano S, Romeo F, Ippoliti A. Ruptured Hypogastric Aneurysm and Acute Myocardial Infarction: A Rare Case Report. *Glob J Emerg Med*. 2018; 1(1): 1005.

Copyright © 2018 Ascoli Marchetti

A. This is an open access article distributed under the Creative Commons Attribution License, which permits unrestricted use, distribution, and reproduction in any medium, provided the original work is properly cited.

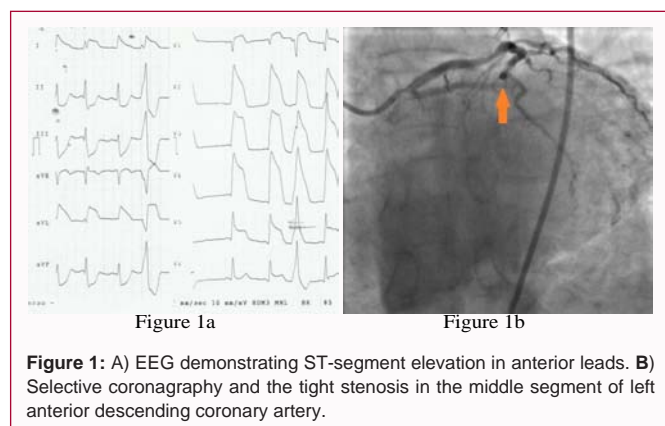


Figure 1: A) ECG demonstrating ST-segment elevation in anterior leads. B) Selective coronagraphy and the tight stenosis in the middle segment of left anterior descending coronary artery.

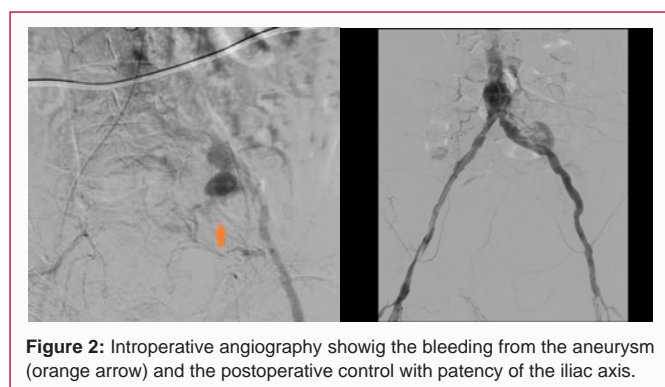


Figure 2: Intraoperative angiography showing the bleeding from the aneurysm (orange arrow) and the postoperative control with patency of the iliac axis.

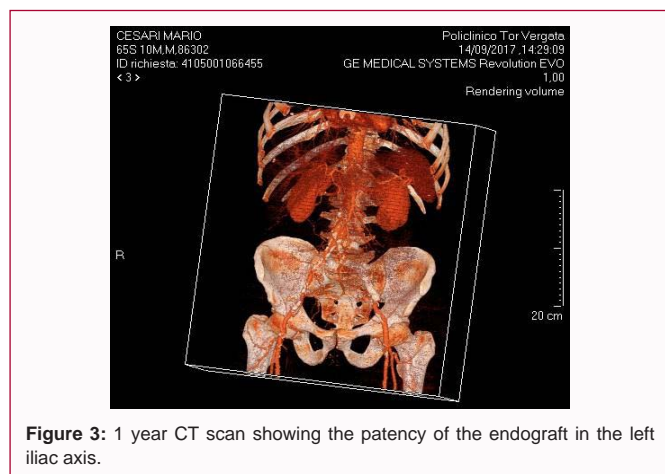


Figure 3: 1 year CT scan showing the patency of the endograft in the left iliac axis.

Discussion

No data are available in the literature of simultaneous different thoracic and abdominal pain. The presence of contemporary thoracic and abdominal discomfort poses diagnostic problems and treatment priorities difficult to solve. Our case is not reported previously in the Literature. The severity of the clinical picture must be assessed on the basis of the severity of the two districts, concerned the evaluation of the urgency of treatment. Regarding the thoracic pain, in the Nam and colleagues review, about 16 studies, including 13521 patients, was observed that in Out-of-hospital 12-lead ECG was associated with a 39% reduction in relative risk of 30-day mortality for percutaneous

coronary intervention [1-3]. Regarding the abdominal pain, only after the evaluation of the ED doctor, the surgeon is consulted, as Brady et al demonstrated in a survey involving 440/1000 ED [4]. Also in our experience, the patient was referred to the surgeon after the CT scan. In our experience in a high volume hospital with 24/24 hour cardiac hemodynamic service, the evidence of ST segment elevation was considered a priority and life saving for our patient. But, despite the successful outcome of the coronarography procedure, we have witnessed a worsening of the clinical picture associated to the decrease of the hemoglobin, suggesting the execution of a II level examination to highlight any possible complications of the access performed for the previous procedure or bring out diseases related to abdominal pain. The evidence of large hypogastric aneurysm with rupture represents a second life saving emergency in our case. The mortality rate with endovascular repair is 18% whit good immediate result [5,6], while open surgery is associated to 60% of mortality for open repair [7]. Considering these data, our case was promptly treated with occlusion of the origin of hypogastric artery and the endografting of iliac axis. In this case the benefit of this treatment was documented by 1 year Ct scan, showing the complete and permanent exclusion of the aneurysm and the patency of the left iliac axis. The patient is well after 18 months.

Conclusion

Our case is characterized by a rarity and a singular life saving treatment. The anemia caused by the discharge of blood from the aneurysmal sac has slowed down a coronary pathology that was immediately recognized and treated successfully. The multidisciplinary approach and the timeliness of treatment allowed to obtain a good result, maintained at a distance.

References

- Nam J, Caners K, Bowen JM, Welsford M, O'Reilly D. Systematic review and meta-analysis of the benefits of out-of-hospital 12-lead ECG and advance notification in ST-segment elevation myocardial infarction patients. *Ann Emerg Med.* 2014;64(2):176-86.
- Karras CM, Donlan S, Aitchison R, Wang E, Kharasch M, Aitchison P. Acute coronary syndromes. *Disease-a-Month.* 2013;59(5):202-9.
- O'Connor RE, Bossaert L, Arntz HR, Brooks SC, Diercks D, Feitosa-Filho G, et al. Part 9: Acute Coronary Syndromes 2010 International Consensus on Cardiopulmonary Resuscitation and Emergency Cardiovascular Care Science With Treatment Recommendations. *Circulation.* 2010;122(16 Suppl 2):S422-65.
- Wolfe JM, Lein DY, Lenkoski K, Smithline HA. Analgesic administration to patients with an acute abdomen: a survey of emergency medicine physicians. *Am J Emerg Med.* 2000;18(3):250-3.
- Pirvu A, Gallet N, Perou S, Thony F, Magne JL. Midterm results of internal iliac artery aneurysm embolization. *J Med Vasc.* 2017;42(3):157-61.
- Millon A, Paquet Y, Ben Ahmed S, Pinel G, Rosset E, Lermusiaux P. Midterm outcomes of embolisation of internal iliac artery aneurysms. *Eur J Vasc Endovasc Surg.* 2013;45(1):22-7.
- Morris ME, Huber KM, Maijub JG. Ruptured hypogastric artery aneurysms: A contemporary review. *Vascular and Endovascular Surgery.* 2013;47(3):239-44.