



Retrospective Study on the Treatment of Submucous Tumor by conventional ESD and Complete Removal of Mucous and Submucous Tissue of the Lesion Mucous and Submucous Tissue of Cross Incision Method

Yue Yuan Wang¹, Ya Ping Weng¹, Fei Da¹, Sensen Tang¹, Zhiyong Wang^{2*}, Guo Dong Li², Jian Liang Wu², Li Wei Sun², Zhi Guo La² and Ting Xu²

Department of Gastroenterology, Hospital of Hangzhou Normal University, China

Abstract

During the past 2015-2017 years, patients with gastric submucosal tumor were hospitalized in the Affiliated Hospital of Hangzhou Normal University.

Method: The treatment of submucous tumor by conventional ESD and Complete removal of mucous and submucous tissue of the lesion and mucous and submucous tissue of cross-incision method.

Results: In 40 patients, 37 cases of complete endoscopic gastric submucosal tumor resection, tumor diameter 1.0 cm - 5.0 cm, complete resection of the tumor with success rate of 92.5%; intraoperative transit surgery in 3 cases, 1 cases of extracellular growth of tumor and diameter 3.0 cm × 4.0 cm. 1 cases of lesions of capsule with bean curd residue, and cannot be completely stripped, bleeding in 1 cases and no effective hemostasis; in 37 cases, endoscopic resection of tumor tissue of gastric mucosa under send pathology, including 30 patients with gastric stromal tumors, 5 cases of gastric ectopic pancreas, 2 cases of angiomylipoma.

Conclusion: Conventional ESD technology for large gastric submucosal tumor complete resection of gastric mucosa and submucosa, such as perforation wound closure is often difficult; "dispel top" method, the utility model has the advantages of gastric submucosal tumors, first complete resection of gastric mucosa and submucosa tissue to fully exposed tumor, direct discovery of tumor, increase tumor stripping efficiency; the "cross incision" method, the utility model has the advantages of the first lesions of the mucosa and submucosa of cross incision, and complete reservative gastric mucosa and submucosa, reduce trauma and for large submucosal lesions, for titanium clips closed the wound and reduce bleeding, perforation and postoperative complications.

Introduction

Early detection and early diagnosis of gastric stromal tumors have created favorable conditions for minimally invasive endoscopic treatment. Besides conventional ESD resection of gastric submucosal tumors, we should explore other endoscopic procedures to make operation more convenient, safe, shorten operation time and reduce complications.

General information

During the past 2015-2017 years, patients with gastric submucosal tumor were hospitalized in the Affiliated Hospital of Hangzhou Normal University. After the adoption of the hospital ethics committee, the patient signed the informed consent and regular postoperative pathology.

Equipment and Materials

Olympus-GIF H260, H260J electronic gastroscope, Olympus-ME-2 ultrasonic endoscopy and ultrasonic probe, frequency MHZ20, NM-4L-1 injection needle, FD-1u-1 hot biopsy forceps, ERBE-200, titanium clip, endoscope special transparent cap. Anesthetic methods: painless endoscopy and general anesthesia.

Method

1. The conventional ESD method: the classic method.

OPEN ACCESS

*Correspondence:

Zhiyong Wang, Department of Gastroenterology, Hangzhou Normal University Affiliated Hospital, China, E-mail: Zywang157@sina.com

Received Date: 29 Jan 2018

Accepted Date: 10 Feb 2018

Published Date: 23 Feb 2018

Citation:

Wang YY, Weng YP, Da F, Tang S, Wang Z, Li GD, et al. Retrospective Study on the Treatment of Submucous Tumor by conventional ESD and Complete Removal of Mucous and Submucous Tissue of the Lesion Mucous and Submucous Tissue of Cross Incision Method. *J Gastroenterol Hepatol Endosc.* 2018; 3(1): 1036.

Copyright © 2018 Zhiyong Wang. This is an open access article distributed under the Creative Commons Attribution License, which permits unrestricted use, distribution, and reproduction in any medium, provided the original work is properly cited.

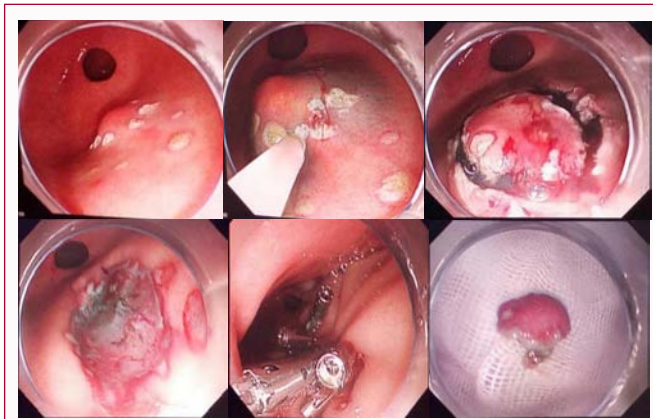


Figure 1: The APC mark of gastric submucosal tumor edge.

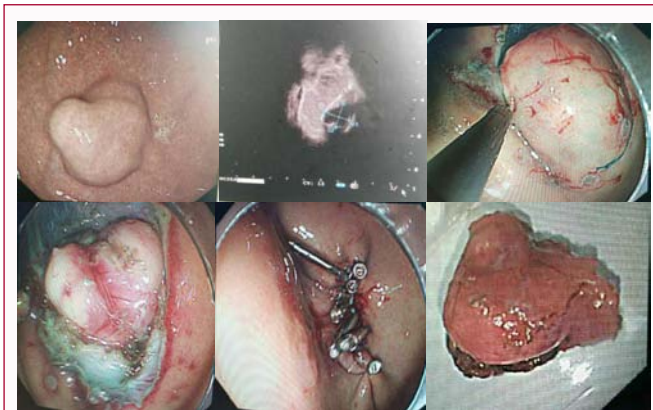


Figure 2: The edge of gastric submucosal tumor was marked by APC markers.

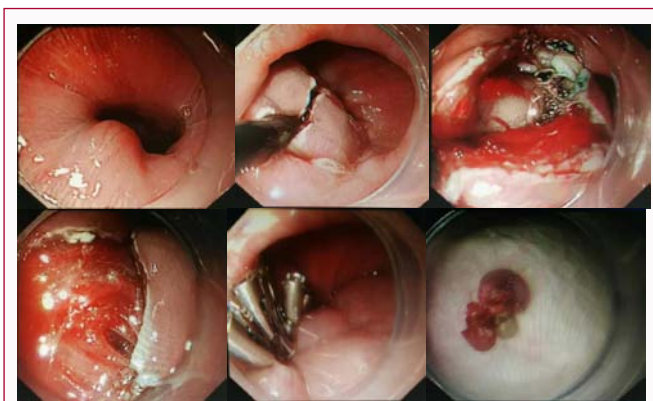


Figure 3: Cross incision in the mucous and submucosa of the lesion.

The APC mark of gastric submucosal tumor edge, Dissection of mucosa and submucosa of Hook and IT knife, hemostatic and metal titanium clips closed wound (Picture as follows).

2. Complete removal of mucous and submucous tissue of the lesion (abbreviation "dispel-top method"):

The edge of gastric submucosal tumor was marked by APC markers; the snare was excised completely, and the mucosa and submucosa were removed by Hook and IT knife. The lesions were complete dissected. Metal titanium clips closed wound (Picture as follows).

3. Cross incision in the mucous and submucosa of the lesion

Table 1: General information on patients.

	Sex		Age (y)	Samplesize (n)	SMT diameter (cm)
	men	women			
Routine ESD group	6	14	56	20	2.0-3.0
"dispel top" method	4	6	62	10	1.0-2.0
"Crossincision" method	3	7	53	10	3.0-5.0

(abbreviation "cross" method).

The mucous and submucosal of the central regoing lesion was Cross incision. The Hook and IT knife were used to remove the lesion. The hemostasis and titanium clips closed the wound. (Picture as follows).

Results

In 40 patients, 37 cases of complete endoscopic gastric submucosal tumor resection, tumor diameter 1.0 cm - 5.0 cm, complete resection of the tumor with success rate of 92.5%; intraoperative transit surgery in 3 cases, 1 cases of extracellular growth of tumor and diameter 3.0 cm × 4.0 cm. 1 cases of lesions of capsule with bean curd residue, and cannot be completely stripped, bleeding in 1 cases and no effective hemostasis; in 37 cases, endoscopic resection of tumor tissue of gastric mucosa under send pathology, including 30 patients with gastric stromal tumors, 5 cases of gastric ectopic pancreas, 2 cases of angiomyolipoma.

Discussion

Development and popularization of gastroscopy and endoscopic ultrasonography can greatly improve the detection rate of gastric submucosal tumor, but benign and malignant tumors unable to determine [1], the group of 37 patients, 30 cases of gastric stromal tumor after postoperative pathology, 5 cases of gastric ectopic pancreas, 2 cases of angiomyolipoma, therefore, early removal of the tumor to obtain accurate, complete pathological data. ESD, EFR, ESE and its derivative technology such as STER SMT in clinical routine treatment has been carried out [2-4]; conventional ESD technology for large gastric submucosal tumor complete resection of gastric mucosa and submucosa, such as perforation wound closure is often difficult; this study reports "dispel top" method, the utility model has the advantages of gastric submucosal tumors, first complete resection of gastric mucosa and submucosa tissue to fully exposed tumor, direct discovery of tumor, increase tumor stripping efficiency; the "cross incision" method, the utility model has the advantages of the first lesions of the mucosa and submucosa of cross incision, and complete reservative gastric mucosa and submucosa, reduce trauma and for large submucosal lesions, for titanium clips closed the wound and reduce bleeding, perforation and postoperative complications. 3 cases of intraoperative trans-surgical surgery are the primary stage of ESD operation, which may be related to our lack of experience. Gastrointestinal stromal tumors often occur in elderly patients, located in the upper part of the body of stomach, most were very low or low risk, but the biological behavior of larger than 1.5 cm in diameter The possibility of a high risk or a malignant, there is a high risk may suggest the intervention of [5].

References

1. Ponsaing LG, Kiss K, Hanhen MB. Classification of submucosal tumors in the gastrointestinal tract. *World J Gastroenterol.* 2007;13(24):3311-5.
2. Tingsheng L, Qing FS, Ying L. Efficacy and safety of endoscopic resection

- of giant gastric stromal tumors. *Chinese J Digestendosc.* 2013;30(2):90-3.
3. Jiabin X, Pinghong Z. Advances in endoscopic full resection for gastric submucosal tumors. *Chinese J Digestendosc.* 2013;30(2):63-5.
 4. Jianghong L, Feng L, Xingang S. Comparative analysis of endoscopic submucosal tumor excavation and endoscopic mucosal resection for gastric my esophageal tumors. *Chinese J Digestendosc.* 2017;34(3):173-80.
 5. Juanjuan M, Fang X, Jing T. Clinical and pathological features of small gastrointestinal stromal tumors. *Chinese J Digestendosc.* 2016;33(12):834-7.