



Regenerative Effects of Local Injection of Basic Fibroblast Growth Factor into the Vocal Fold Atrophy and Scarring: Results of 60 Cases

Shigeru Hirano^{1*}, Mami Kaneko² and Yo Kishimoto²

¹Department of Otolaryngology-Head and Neck Surgery, Kyoto Prefectural University of Medicine, Japan

²Department of Otolaryngology-Head and Neck Surgery, Graduate School of Medicine, Kyoto University, Japan

Abstract

Introduction: Vocal fold atrophy and scar are featured with altered histological architecture of the vocal fold mucosa, which leads to permanent intractable dysphonia. Although there has been no optimal treatment for this entity, basic fibroblast growth factor (bFGF) has proven to be effective for the treatment of vocal fold scar and atrophy. Local injection of bFGF into the vocal fold proved positive effects in preliminary studies. Subsequent large series of patients' data were reviewed and reported here.

Study Design: Retrospective.

Method: Sixty cases (35 atrophy and 25 scar) were treated by local injection of bFGF. Injection regimen was to locally apply 10 micrograms of bFGF in 0.5mL saline into each vocal fold under topical anesthesia repeatedly (4 times with interval of one week between each injection). Therapeutic outcomes were retrospectively reviewed during the follow up periods of 3 months through 12 months (mean period: 4.5 months).

Results: Maximum phonation time, voice handicap index (VHI)-10, and GRBAS scale were assessed and were significantly improved in both atrophy and scar cases. Success rate, defined by improvement of VHI-10 more than 5, was 89.6%, 72% in atrophy and scar patients, respectively. Temporal erythema was observed in 34 cases (52.5%), but no major adverse effects were observed.

Conclusion: Local injection of bFGF has shown to be effective for improvement of vocal function in vocal fold atrophy and scar.

Keywords: Vocal fold atrophy; Scar; Basic fibroblast growth factor; Phonatory outcome

Introduction

Vocal fold scar and atrophy causes permanent dysphonia, and remains therapeutic challenge [1,2]. The critical problem is the alteration of micro-architecture of the vocal fold mucosa. Layer structure, consisting of the superficial layer of the lamina propria (SLP), intermediate layer of the lamina propria (ILP), and deep layer of the lamina propria (DLP), is essential for vibratory property of the vocal fold mucosa. Normally the SLP contains few fibers but is rich in amorphous substances such as hyaluronic acid, which makes the SLP pliable and easy to vibrate. In vocal fold scar or atrophy, however, the SLP becomes thin, and is occupied with thick collagen bundles with few hyaluronic acid, which makes the vocal fold stiff and difficult to vibrate [2,3]. There have been no optimal treatments for vocal fold scar or atrophy because there was no effective way to soften the stiffened vocal folds.

The organization of extracellular matrix (ECM) in the vocal fold mucosa is controlled mainly by fibroblasts which produce every ECMs including collagen, elastic, hyaluronic acid, and proteoglycans. It is well known that the function of fibroblasts in the scarred or atrophied vocal folds is deteriorated, which lead to accumulation of thick collagen bundles and decrease of hyaluronic acid [4-6]. It is essential to improve the function of the fibroblasts to treat vocal fold scar and atrophy. Basic fibroblast growth factor (bFGF) is a potent protein that stimulates growth of fibroblasts and improves the function of fibroblasts. We have proven that bFGF increase hyaluronic acid production from the vocal fold fibroblasts and in mean time reduce collagen accumulation in

OPEN ACCESS

*Correspondence:

Shigeru Hirano, Department of Otolaryngology-Head and Neck Surgery, Kyoto Prefectural University of Medicine, Kajii-cho, Kamigyo-ku, Kyoto 602-8566, Japan, Tel: +81-75-251-5603; Fax: +81-75-251-5604; E-mail: hirano@koto.kpu-m.ac.jp

Received Date: 22 Nov 2016

Accepted Date: 20 Dec 2016

Published Date: 22 Dec 2016

Citation:

Hirano S, Kaneko M, Kishimoto Y. Regenerative Effects of Local Injection of Basic Fibroblast Growth Factor into the Vocal Fold Atrophy and Scarring: Results of 60 Cases. *Ann Clin Otolaryngol.* 2016; 1(1): 1005.

Copyright © 2016 Shigeru Hirano. This is an open access article distributed under the Creative Commons Attribution License, which permits unrestricted use, distribution, and reproduction in any medium, provided the original work is properly cited.

Table 1: Demographic data of patients.

Demographic data of patients	Atrophy	Scar/Sulcus
<i>n</i>	35	25
M/F	24/11	21/4
Age (ave.)	62.8 ± 19.9	58.3 ± 18.3
Occupation		
Prof. voice user	6	8
Non-prof. voice user	29	17
Smoker	0	0
Pre-treatment assessment		
MPT	12.2±7.9	14.1±7.7
VHI-10	17.4±9.8	18.7±8.2
GRBAS	5.3±2.6	5.4±2.1
Follow up (ave.)	3-72 mo (12 mo)	3-48 mo (11.5 mo)

the vocal fold [7,8]. We have also confirmed the regenerative effects of bFGF for vocal fold scar and atrophy using animal models [9,10]. Our previous preliminary clinical trials have indicated improvement of phonatory function in human patients with vocal fold scar and atrophy by local injection of bFGF into the vocal folds [11,12]. The current study is the follow-up study of bFGF injection to vocal fold scar and atrophy in a larger series of patients.

Materials and Methods

Patients

Sixty cases (35 atrophy and 25 scar) were treated by local injection of bFGF under topical anesthesia. Atrophy group consisted of 24 males and 11 females with age ranging from 18 years to 89 years old (mean 62.8 years old). Young cases were regarded as congenital atrophy of the vocal fold. Six cases were professional voice users, and 29 cases were non-professional voice users. Scar group consisted of 21 males and 4 females with age ranging from 19 years to 85 years old (mean 58.3 years old). Eight cases were professional voice users, and 17 cases were non-professional voice users. No smoking history was confirmed in all cases. Pre-treatment maximum phonation time (MPT) was 12.2±7.9 and 14.1±7.7 in atrophy and scar cases, respectively. Voice handicap index 10 (VHI-10) was 17.4±9.8 and 18.7±8.2 in atrophy and scar cases, respectively. The sum of GRBAS scales was 5.3±2.6 and 5.4±2.1 in atrophy and scar cases, respectively. Follow-up periods were 3-72 months (average 12 months) and 3-48 months (average 11.5 months) for atrophy and scar cases, respectively (Table 1).

Drug information

A commercial form of human recombinant bFGF (Fiblast®RR, Kaken Co., Tokyo) was prepared. The active ingredient of this drug is Trafermin (a recombinant genetically engineered form of human bFGF). The supplied drug information shows that this drug stimulates growth and proliferation of endothelial cells and fibroblasts, and contributes in improvement of wound healing by stimulating angiogenesis and formation of proper granulation tissue. Adverse effects were reported in 1.5% of cases, including pain, rash, and itching at the application site. It is not recommended to use the drug to the site of malignant tumors, because the drug may stimulate growth of the tumor. Information of half-life of the drug is not provided.

Fiblast®RR was approved for the treatment of skin ulcers and

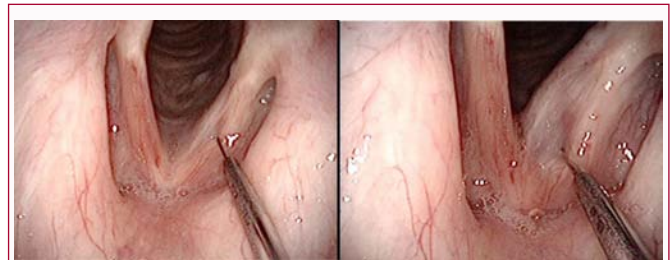

Figure 1: Procedure of local injection of bFGF into the vocal fold. (Left) The needle is placed at the superficial lamina propria near to the lesion of atrophy or scar. (Right) Ten micrograms of bFGF in 0.5 mL solution is injected.

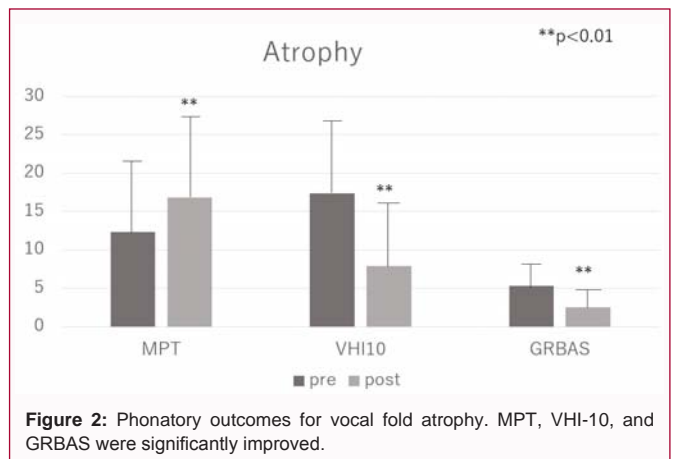


Figure 2: Phonatory outcomes for vocal fold atrophy. MPT, VHI-10, and GRBAS were significantly improved.

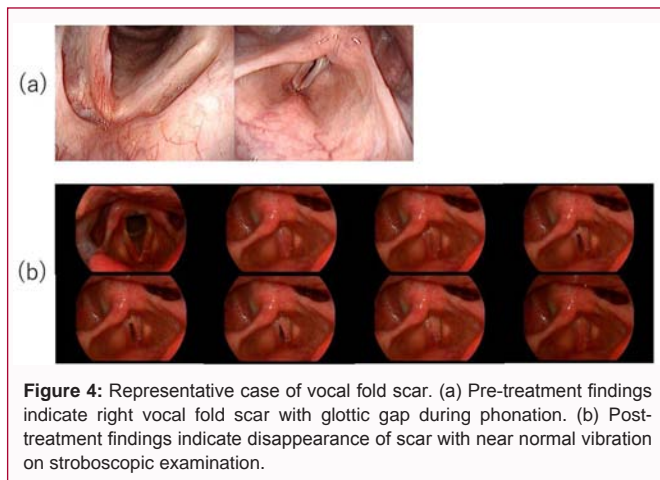
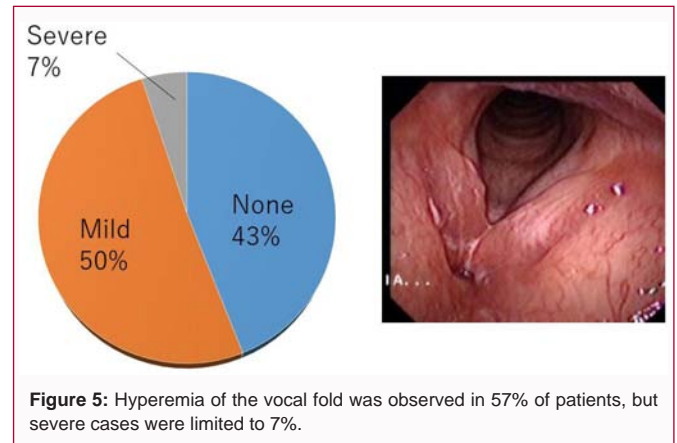
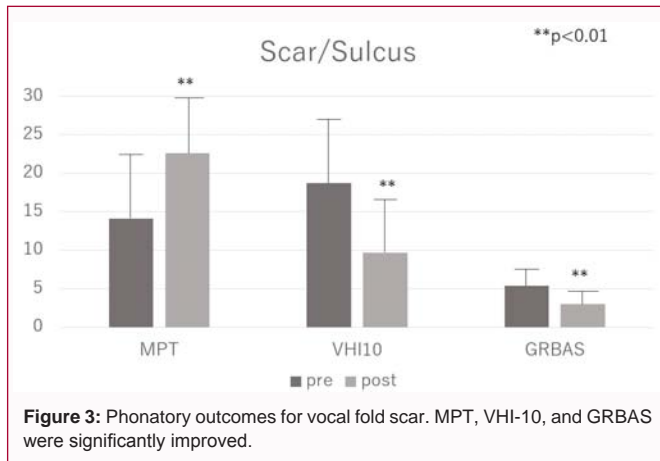
bed sores by the Japanese Ministry of Health and Welfare in 1991, and has been widely used on human patients in spray form. No serious adverse effects have been reported.

Injection protocol

Ten micrograms of bFGF in 0.5 mL buffer was injected transorally into one side of the vocal fold. Injection was performed unilaterally or bilaterally depending on the site of lesion. The pharynx and larynx were completely anesthetized with 4% lidocaine atomizer. The injection was performed with a curved injection needle under transnasal fiberoptic monitoring of the larynx (Figure 1). Possible allergic response, including edema of the vocal fold, was examined 1 hour after the injection. The injection was repeated 4 times with an interval of 1 week between each injection. The first check up of the effects was performed at 3 months after the initial injection by perceptive voice quality assessment and stroboscopic examination. Patients were instructed to keep voice rest on the day of injection, and allowed to phonate from the next day.

Assessment of vocal outcomes

Vocal outcomes were evaluated at least 3 months after the final procedures. Maximum phonation time (MPT), voice handicap index (VHI)-10, and GRBAS scale were assessed in both groups. GRBAS scale was evaluated by two listeners, one laryngologist (SH) and one speech pathologist (MK) with thorough experience in clinical practice, independently. This scale was first developed by the Japanese Society of Logopedics and Phoniatrics, and became popular worldwide. The GRBAS scale is scored from 0 to 3, in which 0 = within normal limits, 1 = slight, 2 = moderate and 3 = severe. The ratings of the five subscales (G, R, B, A, S) were summed and the mean rating-score between two listeners was calculated. The inter-rater reliability between the listeners was made using Cronbach's



alpha and the results showed significant correlation with a correlation coefficient of $r = 0.8$ ($p < 0.001$).

Statistical test

Statistical tests for pre- and post-treatment data were completed for each parameter using paired t test. A *p* value of less than 0.05 was considered significant.

Results

Phonatory outcome

Regarding atrophy cases, MPT was significantly elongated ($p=0.0010$), VHI-10 was significantly decreased ($p=0.0001$), and GRBAS score was significantly decreased ($p=0.0001$) (Figure 2). MPT, VHI-10, and GRBAS were also significantly improved in scar cases ($p=0.0027, 0.0001, 0.0003$, respectively) (Figure 3). There were no significant differences in the degree of improvement on any parameters between atrophy and scar cases.

Figure 4 shows a representative case with vocal fold scar on the right vocal fold caused by cordectomy, which indicated glottic gap during phonation. Six months after injection of bFGF, the scar tissue almost disappeared with improved vibration and no glottic gap.

Success rate

It is really difficult to present success rates because there has been no criterion to determine success rates in medical care for dysphonia. Recently Gartner-Schmidt et al. proposed to define “success” by reduction of VHI-10 more than 5 in voice therapy for patients with vocal fold atrophy [13]. If this criterion is adopted for the current

study, the success rates for vocal fold atrophy and scar were 89.6% and 72%, respectively.

Adverse effects

All cases showed no allergic response or any severe adverse effects. Minor adverse effects were hyperemia of the vocal fold, which caused temporary rough voice. Hyperemia was found in 34 cases (52.5%) of 60 cases including 30 mild cases and 4 severe cases (Figure 5). This reaction disappeared within a couple of months. Temporary rough voice was also improved with reduction of the hyperemia.

Recurrence of dysphonia

Three of 35 cases (8.5%) with vocal fold atrophy recurred dysphonia at 12-36 months (median 30 months) after treatment. Two of 25 cases (8%) with vocal fold scar recurred dysphonia at 36 and 48 months. The total rate of recurred dysphonia was 8.2%.

Discussion

Tissue engineering and regenerative medicine was the breakthrough at late 20th century [14]. The principle concept is to regenerate tissues using cells, growth factors and scaffolds. Cell is the most powerful regenerative tool, and several stem cells have been developed and researched including bone marrow derived mesenchymal stem cell (MSC), adipose derived mesenchymal stem cell (ASC), and embryonic stem cell (ES cell). The induced pluripotent stem cell (iPS cell) was an innovation to reprogram somatic cells back to stem cells. In spite that several preclinical researches using these cells have proven the positive effects for regeneration of the vocal fold [15-17], cell therapy has yet been approved for use to patients with vocal fold pathology.

Growth factors are another promising tool to induce tissue regeneration by stimulating growth of cells and controlling the function of the cells. Our previous in vitro studies have demonstrated that bFGF stimulated the production of hyaluronic acid (HA) from vocal fold fibroblasts and reduced collagen production meanwhile, and exogenous growth factor stimulated the cells to produce the endogenous growth factor in autocrine manner [18], which was thought to endure the growth factor inside the tissue. Basic FGF also has potent effects on angiogenesis and wound healing. A GMP-compatible product of bFGF is available for human in Japan. The appropriate dose and time of application were confirmed based on our animal experiments [10].

The current results with larger series of cases with vocal fold atrophy and scar were compatible with our previous preliminary

studies, indicating improvement of MPT, VHI-10, and GRBAS scale. Although there was no statistically significant difference in the effects for both groups, the success rate seemed to be better in atrophy, and still insufficient for scar. Further improvement will be warranted for vocal fold scar possibly using drug delivery system, etc.

Safety aspect was confirmed with no severe adverse effects in all cases. Hyperemia was observed in approximately half of the patients, but this was caused by angiogenic effects of the growth factor. Regenerative mechanism always requires sufficient blood flow in the tissues, and in this sense, hyperemia can be regarded as a positive event that predicts regenerative effects of the growth factor.

There were 5 cases (8.2%) with recurrence of dysphonia. Regarding vocal fold atrophy, the fibroblasts usually become geriatric with reduction of function, and bFGF stimulates them to work harder in producing ECM proteins. This is also the case with scar in which fibroblasts change their phenotype. With times after treatment, however, the cells can become geriatric again, which may cause recurrent dysphonia. Although the rate is low, it is possible to apply bFGF to additionally improve the function of the cells.

Conclusion

Injection of bFGF has been performed for sixty human patients with vocal fold atrophy or scar. The results confirmed safety aspect with positive regenerative effects on both pathologies. Vocal fold scar still remains difficult to treat as compared to vocal fold atrophy, and further investigation will be needed to establish optimal treatment. However, the current results at least indicate effectiveness of bFGF treatment for vocal fold atrophy and scar.

References

- Hirano S. Current treatment of vocal fold scarring. *Curr Opin Otolaryngol Head Neck Surg.* 2005; 13: 143-147.
- Johns MM, Arviso LC, Ramadan F. Challenges and opportunities in the management of the aging voice. *Otolaryngol Head Neck Surg.* 2011; 145: 1-6.
- Hirano S, Minamiguchi S, Yamashita M, Ohno T, Kanemaru S, Kitamura M. Histologic characterization of human scarred vocal folds. *J Voice.* 2009; 23: 399-407.
- Hirano M, Sato K, Nakashima T. Fibroblasts in geriatric vocal fold mucosa. *Acta Otolaryngol.* 2000; 120: 336-340.
- Chen X, Thibeault SL. Characteristics of age-related changes in cultured human vocal fold fibroblasts. *Laryngoscope.* 2008; 118: 1700-1704.
- Kumai Y, Kobler JB, Park H, Lopez-Guerra G, Karajanagi S, Herrera VL, et al. Crosstalk between adipose-derived stem/stromal cells and vocal fold fibroblasts *in vitro*. *Laryngoscope.* 2009; 119: 799-805.
- Hirano S, Bless DM, Heisey D, Ford CN. Effect of growth factors on hyaluronan production by canine vocal fold fibroblasts. *Ann Otol Rhinol Laryngol.* 2003; 112: 617-624.
- Suehiro A, Hirano S, Kishimoto Y, Tateya I, Rousseau B, Ito J. Effects of basic fibroblast growth factor on rat vocal fold fibroblasts. *Ann ORL.* 2010; 119: 690-696.
- Suehiro A, Hirano S, Kishimoto Y, Rousseau B, Nakamura T, Ito J. Treatment of acute vocal fold scar with local injection of basic fibroblast growth factor: a canine study. *Acta Otolaryngol.* 2010; 130: 844-850.
- Hirano S, Nagai H, Tateya I, Tateya T, Ford CN, Bless DM. Regeneration of aged vocal folds with basic fibroblast growth factor in a rat model: a preliminary report. *Ann Otol Rhinol Laryngol.* 2005; 114: 304-308.
- Hirano S, Mizuta M, Kaneko M, Tateya I, Kanemaru S, Ito J. Regenerative phonosurgical treatments for vocal fold scar and sulcus with basic fibroblast growth factor. *Laryngoscope.* 2013; 123: 2749-2755.
- Hirano S, Tateya I, Kishimoto Y, Kanemaru S, Ito J. Clinical trial of regeneration of aged vocal folds with growth factor therapy. *Laryngoscope.* 2012; 122: 327-331.
- Gartner-Schmidt J, Rosen C. Treatment success for age-related vocal fold atrophy. *Laryngoscope.* 2011; 121: 585-589.
- Vacanti JP, Langer R. Tissue engineering. *Science.* 1993; 260: 920-926.
- Kanemaru S, Nakamura T, Omori K, Kojima H, Magruffov A, Hiratsuka Y, et al. Regeneration of the vocal fold using autologous mesenchymal stem cells. *Ann Otol Rhinol Laryngol.* 2003; 112: 915-920.
- Hertegard S, Cedervall J, Svensson B, et al. Viscoelastic and Histologic Properties in Scarred Rabbit Vocal Folds After Mesenchymal Stem Cell Injection. *Laryngoscope.* 2006; 116: 1248-1254.
- Xu W, Hu R, Fan E, Demin Han. Adipose derived mesenchymal stem cells in collagen hyaluronic acid gel composite scaffolds for vocal fold regeneration. *Ann ORL.* 2011; 120: 123-130.
- Kishimoto Y, Hirano S, Suehiro A, Tateya I, Kanemaru S, Nakamura T, et al. Effect of exogenous hepatocyte growth factor on vocal fold fibroblasts. *Ann Otol Rhinol Laryngol.* 2009; 118: 606-611.