Annals of Plastic and Reconstructive Surgery

Research Article
Published: 15 Aug, 2022

Regenerative Approach to Facial Scars with the Vampire Scar Technique: A Single Center Experience

*Daniele Bollero**

Department of Plastic Surgery, CTO Hospital - Turin, Italy

Abstract

Objectives: Evaluation of the acceptance and patient satisfaction of the combination of Platelets Rich Plasma (PRP) with microneedling in the treatment of face scars of various cause.

Patients and Methods: The author reports his experience on 50 patients (42 F, 8 M), with face scars. Twenty patients (18 F, 2 M; age: 18 to 30 years) were affected by atrophic acne scars in inactive phase. Twenty patients presented with scars in a remodeling phase (14 F, 6 M; age: 28 to 60 years)) lasting up to 6 month after traumatic injuries or surgical procedures. Ten patients (7 F, 3 M; 35 to 51 years) were affected by post-burn scars.

Patients' satisfaction was evaluated with the GAIS score.

Results: Adherence was complete in all cases. At the end of the treatment scars were evaluated as "very much improved" by 10 patients (20%) and "much improved" by 24 patients (48%). In 24 (12%) cases the scars were considered "improved". Only 4 /50 patients (8 %) declared that the procedures gave no results.

Conclusion: The combination of PRP and needling can be safely and satisfactorily used to treat face scars.

Keywords: Regenerative medicine; Platelets rich plasma; Needling; Scar; Vampire; Dermapen

Introduction

Facial scars, even if minor, have significant psychological impact on quality of life [1-3]. There may also be functional consequences but patients are usually mainly concerned by the aesthetic aspects [4]. Thus, in our experience, face scar treatments are more requested than bodies. Several scars treatments, such as lasers, radiofrequency and topical preparations, have been described [5] and, recently, regenerative medicine has received increased interest. The best regenerative approach in face scars should aim to promote angiogenesis, improve hydration, smooth the skin and be non-invasive [6].

Since regenerative treatments were introduced those based on Platelets Rich Plasma (PRP) have proven to be easiest to apply and hence are most commonly used, but combined therapies provide better outcomes [7-9].

The author has developed the Vampire Scar Technique as a combined treatment based on Transdermal Drug Delivery (TDD) of PRP through micro-pores created by micro-needles of 0.5 mm to 1 mm [10].

A single center experience is here reported on the use of this technique in the treatment of facial scars of various origins.

Methods

Design

This is a retrospective case series. The setting was a private clinic with long experience in regenerative treatments in aesthetic medicine [11]. Patients have been recruited from January 2019 to December 2020. All patients received the Vampire Scar Techinique as a combined treatment based on transdermal drug delivery of PRP through micro-pores created by micro needles of 0.5 mm to 1.0 mm [11].

Participants

Fifty patients were included respecting the following criteria: Age 18 to 60, with face scars caused

OPEN ACCESS

Correspondence:
Daniele Bollero, Department of Plastic Surgery, Burn Unit, CTO Hospital - Turin, Italy,
E-mail: info@danielebollero.it

Received Date: *25 Jul 2022*
Accepted Date*: 09 Aug 2022*
Published Date*: 15 Aug 2022*

Citation:
Bollero D. Regenerative Approach to Facial Scars with the Vampire Scar Technique: A Single Center Experience. Ann Plast Reconstr Surg. 2022; 6(3): 1096.

Table 1: Patient characteristics.

		Indications for treatment	
	Atrophic acne scars	Post-burn scars	Face scars in remodeling phase
Number of patients (%)	20 (40%)	10 (20%)	20 (40%)
Age range (yrs)	18-30	35-51	28-60
Gender			
Female n (%)	18 (90%)	7 (70%)	14 (70%)
Male n (%)	2 (10%)	3 (30%)	6 (30%)

by acne, burns or by traumas or surgery (Table 1).

Twenty patients (18 F, 2 M; age: 18 to 30 years) were affected by atrophic acne scars in inactive phase. Twenty patients presented with scars in a remodeling phase (age 28 to 60 years, 14 F and 6 M) lasting up to 6 month after trauma injuries or surgical procedures. Finally, 10 patients (7 F, 3 M; 35 to 51 years) were affected by post-burn scars.

Treatment

In order to obtain an adequate platelet concentration complying with the Italian rules we used the YES kits and a GYROZEN 416® centrifuge.

Seventeen ml of patient's venous blood obtained through a 19 G needle were mixed with 3 ml of anticoagulant (sodium citrate or ACD-A). The syringe was connected to the YES PRP system and the blood centrifuged at 2500 RPM for 8 min using the SOFT START system to avoid hemolysis. This system decelerates softly to avoid remixing of plasma, buffy coat, and RBC ensuring maximum PRP concentration. In addition, the YES PRP system allows to exclude the buffy coat when separating the various components. The syringe containing PRP was gently shaken to obtain the final platelet concentrate. This system requires a single centrifugation leading to a final platelet concentration 5 to 7 times higher (1.000.000 to 1.200.000 platelets/µl) and minimizes structural damages.

Dermapen® was used for the micro-needling. A disposable Dermapen®'s tip cartridge is made of 12 microneedles, which penetrate vertically through the skin [12]. The depth of the needles, settled at 0.7 mm, allows an optimal PRP penetration through the created micro-channels (Figure 1).

Treatment protocol

Vampire Scar Technique consists of 3 monthly sessions:

1. Session: Microneedling with PRP (0.7 mm multiple passages) + Intradermal PRP (4 ml)

2. Session: Microneedling

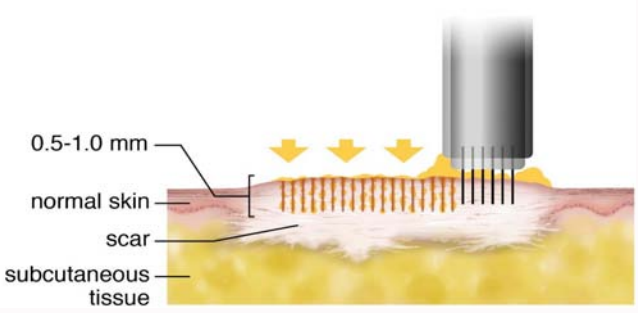

Figure 1: The depth of the Dermapen® needles allows an optimal PRP penetration through the created micro-channels.

Figure 2a: 28 Years old, female. Inactive Acne scars.

Figure 2b: Clinical result after the vampire scar treatment 1 year follow-up.

3. Session: Microneedling

In case of post-burn face scars a further treatment was added: 3 months after the first treatment: microneedling with PRP (0.5 mm to 1 mm multiple passages) + intradermal PRP 4 ml.

After each treatment the patients were told not to use makeup for 12 h and were advised to use a cream containing panthenol 5%, copper and Zinc in the 48 h following the procedure.

Annual microneedling and PRP treatment were highly recommended to maintain the results.

Outcome measures

Patient's satisfaction was assessed at a follow up visit three months after the last treatment, using the Global Aesthetic Improvement Scale (GAIS) a 5-point scale rating global aesthetic improvement [13]. The rating categories are "worse," "no change," "improved," "much improved," and "very much improved." This score has previously proven to be simple and quick for the patients and has been used in the evaluation of aesthetic treatments [14,15].

Improvement of the scar was also evaluated according to the reduction in the use of makeup during the follow up visit as reported by patients.

At follow up information about adverse effect have been systematically collected, potential severe adverse reaction being pain during the treatment, burning sensation, post treatment erythema, injections related ecchymosis.

Statistics

Most of the available variables were categorical, binary or multilevel or ordinal. Therefore the description of the sample is done with proportions.

Results

All patients completed the programmed treatments. During the study period convenient samples of 50 patients have been recruited, 84% were females. Examples of the results obtained are reported in Figures 2a-3b.

Figure 4 shows the overall GAIS scores: independently on the etiology of the scars, the large majority of the patients were satisfied. Scars were considered as "very much improved" by 10 patients (20%) and "much improved" by 24 patients (48%). In 12 (24%) cases the scars were considered "improved". Only 4 /50 patients (8%) declared that the procedures gave no results.

Most of the female patients spontaneously reported a significant reduction in the use of makeup.

No severe adverse reactions, either immediate or delayed, have been reported in the three months period. Some patients reported minor transitory side effects: pain during the treatment, burning sensation, post treatment erythema and injections related ecchymosis.

Figure 3a: 50 Years old, female. Scar after acid burns, inactive. After several surgical interventions the patient asked for an aesthetic improvement of the residual scars.

Figure 3b: Clinical result after application of the Vampire protocol. 3 months follow-up.

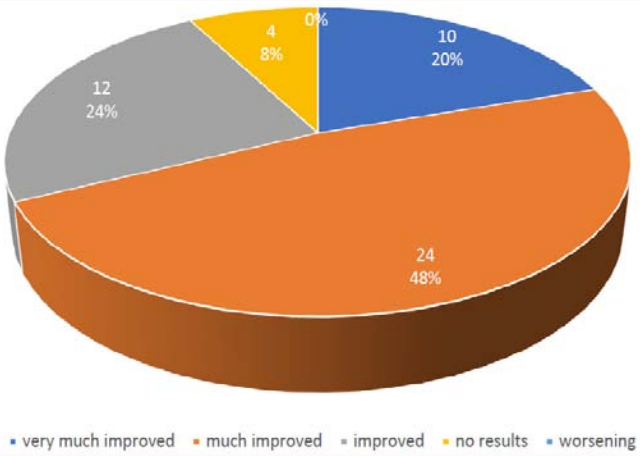

Figure 4: Treatment evaluation according to the GAIS scale. Treatments were considered as "very much improved" by 10 patients (20%) and "much improved" by 24 patients (48%). In 12 (24%) cases the scars were considered "improved". Only 4/50 patients (8%) declared that the procedures gave no results.

Discussion

In this study we found that independently on the cause of the scar the Vampire Scar Technique significantly improved the aesthetic perception of the patient with a reported reduction in the use of makeup.

The "Vampire Scar Technique" combines PRP and microneedling in the treatment of facial scars. We coined this expression as an easy way to communicate with patients which is crucial when results are expected months after performing the procedures.

The three following principles are readily understood by the patients:

- NEEDLING - Vampire's fangs that penetrates the tissue
- PRP - The healing capacity of the vampire
- SCARS - Signs of the vampires' fang

The single components used in the treatment have been widely described. In short, platelets promote cell differentiation, proliferation, and renewal by producing growth factors such as, Transforming Growth Factor-b (TGF-b), Platelet-Derived Growth Factor (PDGF), Vascular Endothelial Growth Factor (VEGF), cytokines, adhesion molecules and chemokines [16,17]. High platelets concentrations attract immune cells via chemotaxis and enhance synthesis of healing proteins improving wound healing and scarring [6]. Since their first use in 1980's huge progresses in regenerative medicine have been made in a variety of applications from dermatology and dentistry to orthopedics, sport medicine and plastic surgery [18,19].

Microneedling, or, Percutaneous Collagen Induction (PCI), is also widely used in multiple skin conditions and for the skin rejuvenation [7]. Modern PCI devices create numerous punctures, 0.5 mm to 1.5 mm in depth, into the stratum corneum and papillary dermis. This allows to avoid significant downtime, hyper or hypo-pigmentation or other more severe complications. No important bleeding usually is observed. These micro-injuries promote natural

regeneration, causing the release of growth factors, triggering collagen and elastin formation in the dermis [20]. Busch et al. [21] in their studies in post-burn scars demonstrated that microneedling alone could reduce itching in 73% of patients and improve scars quality. Moisture, transepidermal water loss, skin tension and elasticity were also improved. Matrix Metalloproteinase's (MMPs) are activated in response to microneedling and play an important role in scar remodeling and therefore in the reduction of aberrantly organized collagen fibers. Neo-angiogenesis and neo-collagenesis improve tissue blood and oxygen supply. It was shown that after only three sessions of meso-needling alone significant improvements were visible in 10 to 20 weeks [20]. PCI is safe since it does not cause necrotic tissue necrosis or severe inflammation.

TDD became well known thanks to the laser scar treatments [22]. Clementoni et al. [23] have studied the effect of fractional laser therapy on severe post-burn scars and an eventual drug delivery through the columns of tissue vaporization. However, they could not predict the number of treatments necessary to optimize the edema, crusting and scaling.

The average duration of crusting or scaling was 7 days [24]. The approach selected in our center is based on a combination of treatments which enhances results and outcomes being thus preferable than single procedures [7-9]. As shown by numerous studies, the combination of PRP and PCI is synergistic allowing improvement in skin hydration [25-28], elasticity and microcirculation [20,29,30].

The Vampire Scar Technique exploits the synergistic effect of the delivery of PRP at deeper skin levels through micro-pores created by microneedles of 0.5 mm to 1 mm and as shown in Figure 1 [27,28]. We used a depth of 0.7 mm since deeper penetration allows similar PRP absorption but causes more side effects, such as "tram track", i.e. criss-crossing tram signs which appear more often with derma-roller devices [31].

Minimally invasive scar treatments are extremely needed. The author wishes to underline five key points. First, regenerative medicine procedures are well accepted by patients since they use only natural products. Secondly, the synergism of two non-invasive procedures allows to minimize the downtime obtaining the best results. Third, patients should have proper expectations, thus adequate communication is essential to prepare correctly them regarding results and timing. Moreover, the Vampire Scar Technique can be performed in an outpatient clinical setting at low costs and in all seasons. PRP centrifuge, microneedling device and disposables are much cheaper than laser machines or surgical procedures. Finally, based on our experience the Vampire Scar Technique causes only mild side effects and is highly appreciated by patients for face scars treatment. The available data did not allow a quantitative analysis and this represents the main limitation of the present study, nevertheless, we recognize the contribution of the presented case series for clinicians as helpful for patient management and communication.

References

1. Hoogewerf CJ, van Baar ME, Middelkoop E, van Loey NE. Impact of facial burns: Relationship between depressive symptoms, self-esteem and scar severity. Gen Hosp Psychiatry. 2014;36(3):271-6.
2. Möller E, Martinez R, Rode H, Adams S. Scar Wars. S Afr J Surg. 2019;57(4):41.
3. Tebble NJ, Adams R, Thomas DW, Price P. Anxiety and self-consciousness in patients with facial lacerations one week and six months later. Br J Oral Maxillofac Surg. 2006;44(6):520-5.
4. Newberry CI, Thomas JR, Cerrati EW. Facial scar improvement procedures. Facial Plast Surg. 2018;34(5):448-57.
5. Negenborn VL, Groen JW, Smit JM, Niessen FB, Mullender MG. The use of autologous fat grafting for treatment of scar tissue and scar-related conditions: A systematic review. Plast Reconstr Surg. 2016;137(1):31e-43e.
6. Alser H, Goutos I. The evidence behind the use of Platelet-Rich Plasma (PRP) in scar management: A literature review. Scars Burn Heal. 2018;4:2059513118808773.
7. Kubiak R, Lange B. Percutaneous collagen induction as an additive treatment for scar formation following thermal injuries: Preliminary experience in 47 children. Burns. 2017;43(5):1097-102.
8. Leo MS, Kumar AS, Kirit R, Konathan R, Sivamani RK. Systematic review of the use of platelet-rich plasma in aesthetic dermatology. J Cosmet Dermatol. 2015;14(4):315-23.
9. Bhargava S, Cunha PR, Lee J, Kroumpouzos G. Acne scarring management: Systematic review and evaluation of the evidence. Am J Clin Dermatol. 2018;19(4):459-77.
10. Hou A, Cohen B, Haimovic A, Elbuluk N. Microneedling: A comprehensive review. Dermatol Surg. 2017;43(3):321-39.
11. Bollero D, Fogli A. Vampire Scar: Outpatient quality improvement of scar regeneration with a composite approach with needling and PRP. In: Kalaaji A, editor. Plastic and Aesthetic Regenerative Surgery and Fat Grafting. Springer, Cham; 2022.
12. Dogra S, Yadav S, Sarangal R. Microneedling for acne scars in Asian skin type: An effective low cost treatment modality. J Cosmet Dermatol. 2014;13(3):180-7.
13. Hersant B, Abbou R, SidAhmed-Mezi M, Meningaud JP. Assessment tools for facial rejuvenation treatment: A review. Aesthetic Plast Surg. 2016;40(4):556-65.
14. Savoia A, Accardo C, Vannini F, Pasquale BD, Baldi A. Outcomes in thread lift for facial rejuvenation: A study performed with happy lift™ revitalizing. Dermatol Ther (Heidelb). 2014;4:103-14.
15. Kim J. Topographic computer analysis for acne scar treatment on face accompanying biopsy study after dermal injection of hydrotoxin mixture. J Cosmet Dermatol. 2020;20(1):75-83.
16. Son D, Harijan A. Overview of surgical scar prevention and management. J Korean Med Sci. 2014;29(6):751-7.
17. Hesseler MJ, Shyam N. Platelet-rich plasma and its utility in medical dermatology: A systematic review. J Am Acad Dermatol. 2019;81(3):834-46.
18. Kaiser LR. The future of multihospital systems. Top Health Care Financ. 1992;18(4):32-45.
19. Mao S, Mooney DJ. Regenerative medicine: Current therapies and future directions. Proc Natl Acad Sci U S A. 2015;112(47):14452-9.
20. Zduńska K, Kołodziejczak A, Rotsztejn H. Is skin microneedling a good alternative method of various skin defects removal. Dermatol Ther. 2018;31(6):e12714.
21. Busch H, Aliu A, Bender R, Walezko N, Aust MC. [Medical needling: Effect on skin tension and elasticity of hypertrophic burn scars]. Handchir Mikrochir Plast Chir. 2019;51(5):384-93.
22. Forbat E, Ali FR, Al-Niaimi F. Treatment of keloid scars using light-, laser- and energy-based devices: A contemporary review of the literature. Lasers Med Sci. 2017;32(9):2145-54.
23. Clementoni MT, Pedrelli V, Zaccaria G, Pontini P, Motta LR, Azzopardi EA. New developments for fractional Co2 resurfacing for skin rejuvenation and scar reduction. Facial Plast Surg Clin North Am. 2020;28(1):17-28.

24. Xu Y, Deng Y. Ablative fractional CO2 laser for facial atrophic acne scars. Facial Plast Surg. 2018;34(2):205-19.

25. Nam SM, Kim YB. The effects of platelet-rich plasma on hypertrophic scars fibroblasts. Int Wound J. 2018;15(4):547-54.

26. Fabbrocini G, Vita VD, Izzo R, Monfrecola G. The use of skin needling for the delivery of a eutectic mixture of local anesthetics. G Ital Dermatol Venereol. 2014;149(5):581-5.

27. Sasaki GH. Micro-needling depth penetration, presence of pigment particles, and fluorescein-stained platelets: Clinical usage for aesthetic concerns. Aesthet Surg J. 2017;37(1):71-83.

28. Sasaki GH. Response to commentaries on "micro-needling depth penetration, presence of pigment particles, and fluorescein-stained platelets: Clinical usage for aesthetic concerns". Aesthet Surg J. 2017;37(5):NP60-1.

29. Ibrahim MK, Ibrahim SM, Salem AM. Skin microneedling plus platelet-rich plasma versus skin microneedling alone in the treatment of atrophic post acne scars: A split face comparative study. J Dermatolog Treat. 2018;29(3):281-6.

30. Asif M, Kanodia S, Singh K. Combined autologous platelet-rich plasma with microneedling verses microneedling with distilled water in the treatment of atrophic acne scars: A concurrent split-face study. J Cosmet Dermatol. 2016;15(4):434-43.

31. Pahwa M, Pahwa P, Zaheer A. "Tram track effect" after treatment of acne scars using a microneedling device. Dermatol Surg. 2012;38:1107-8.