



# Pulmonary Nocardiosis Caused by *Nocardia otitidiscaviarum* - A Case Report

Mohamadiya Rizwana M\* and Appalaraju B

Department of Microbiology, PSG Institute of Medical Sciences and Research, India

## Abstract

Respiratory nocardiosis remains a diagnostic challenge. The disease is rare in immunocompetent individuals. Early identification and appropriate treatment results in decreased mortality in these patients.

**Case presentation:** Herein we report a case of pulmonary nocardiosis due to *Nocardia otitidiscaviarum* in a 56 year old diabetic male with COPD. The patient complained of cough for 2 weeks. Respiratory samples (sputum, BAL) were sent for microbiological analysis. On routine staining, gram positive branching filamentous bacteria were seen. Modified Ziehl Neelsen staining confirmed the presence of acid fast bacilli resembling *Nocardia*. Further analysis by MALDI TOF identified the species to be *Nocardia otitidiscaviarum*. The patient was treated with combination therapy of cotrimoxazole and ciprofloxacin and had a good recovery.

**Conclusion:** Prompt identification and reporting of *Nocardia* aids in the clinical prognosis of the patients.

**Keywords:** Pulmonary Nocardiosis; *N. Otitidiscaviarum*; MALDI TOF

## Introduction

*Nocardia* species are aerobic, beaded, branched gram positive bacilli. They belong to the order Actinomycetales. They are ubiquitous found in soil, water, dust and decayed woods [1]. The most frequently reported species include *Nocardia brasiliensis*, *Nocardia farcinica* and *Nocardia nova*. The less common species includes *Nocardia otitidiscaviarum*, *Nocardia pseudobrasiliensis* and *Nocardia African* [2]. Pulmonary Nocardiosis are commonly encountered in immunocompromised patients. The various factors that predispose this infection includes steroid therapy, chemotherapy and in HIV patient [3]. Here we report a case of pulmonary nocardiosis caused by less pathogenic species *Nocardia Otitidiscaviarum* (*N. otitidiscaviarum*).

## Case Presentation

A 56 year old male diabetic, normotensive, known COPD patient presented to the respiratory OPD with complains of productive cough for 2 weeks and fever for 3 days duration. On examination blood pressure was 120/80 mmHg, respiratory rate 30 per min, temperature was 38°C. Respiratory findings revealed bilateral normal ventricular breath sounds, rhonchi and crepitations were also reported. Base line investigations showed leukocytosis. ABG showed Type 1 respiratory failure. On chest X-ray left mid and lower non homogenous opacity with air fluid level, right lower zone ring shadows was noted. Chest computed tomography showed cystic bronchiectasis with bronchial wall thickening in both lungs predominantly involving left lower lobe with loss of lung volume. Multiple foci of nodular consolidation with surrounding ground glass densities in right upper middle and lower lobe was noted. USG chest showed bilateral minimal pleural effusion with underlying consolidation.

Sputum and Broncho Alveolar Lavage (BAL) sample were positive for gram positive filamentous branched bacteria which was acid fast suggestive of *Nocardia*. The sample was inoculated onto blood agar and chocolate agar. Small white dry wrinkled colonies were isolated in blood agar after incubation for 72 h. Acid fastness was confirmed by doing modified ZN stain from the culture. The isolate was identified as *N. otitidiscaviarum* by MALDI-TOF with a score value of 2.0 (good probability). The antibiotic susceptibility test was done and the isolate was found to be susceptible to gentamicin, ciprofloxacin, amikacin, cotrimoxazole, ceftriaxone, imipenem and resistant to amoxicillin-clavulanic acid. The patient was treated with cotrimoxazole, double the strength twice

## OPEN ACCESS

### \*Correspondence:

Mohamadiya Rizwana M, Department of Microbiology, PSG Institute of Medical Sciences and Research, Avinashi Road, Peelamedu, Coimbatore- 641004, Tamil Nadu, India, Tel: 6374612312;

E-mail: mrizwana123@gmail.com

Received Date: 11 Jun 2020

Accepted Date: 30 Jun 2020

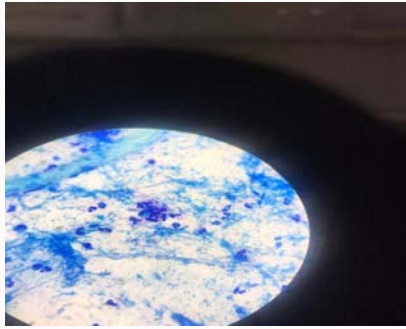
Published Date: 04 Jul 2020

### Citation:

Mohamadiya Rizwana M, Appalaraju B. Pulmonary Nocardiosis Caused by *Nocardia otitidiscaviarum* - A Case Report. *J Respir Med Lung Dis.* 2020; 5(2): 1053.

ISSN: 2475-5761

**Copyright** © 2020 Mohamadiya Rizwana M. This is an open access article distributed under the Creative Commons Attribution License, which permits unrestricted use, distribution, and reproduction in any medium, provided the original work is properly cited.



**Figure 1:** The modified Ziehl Neelsen stain done with 1% sulphuric acid shows pink colored acid fast branching *Filamentous bacilli*.



**Figure 2:** Further culture on sheep blood agar plate showed wrinkled dry white colonies were observed.

daily for 12 weeks with reduction in the dosage after 4 weeks along with ciprofloxacin. The patient showed good response after 1 week initiation of treatment. The patient was discharged with a combination treatment of cotrimoxazole and moxifloxacin. On further follow up of appointment, there was clinical and radiological improvement noted.

## Discussion

*N. otitidiscaviarum* was initially known as *Nocardia caviae* which was first isolated from middle ear infection of guinea pig in 1924 [4]. Among the pulmonary nocardiosis, studies report that *N. otitidiscaviarum* account for 0.3% to 2.9% of all infections [5]. Kageyama et al. [6] described that of more than 303 *Nocardia* strains isolated from Japanese patients with respiratory nocardiosis during 1992 to 2001, only 14 were *N. otitidiscaviarum* [6]. Similar findings were noted by Beaman et al. [7] in United States. The lower incidence of this species has been linked with the reduced prevalence [7].

Studies support its isolation from both immunocompromised and immunocompetent individuals to cause pulmonary, cutaneous and lymphocutaneous infection. But the risk of infection remains high in immunocompromised individuals [8]. *N. otitidiscaviarum* infection in humans occur as 2 major forms pulmonary and cutaneous. Case reports of human to human or animal to human transmission has not been reported [9].

A retrospective study from Australia for over a period of 5 years in patients with pulmonary nocardiosis report that 1 out of 35 was *N. otitidiscaviarum* [10]. South Indian studies have reported this organism as a causative agent in one out of eight cases of pulmonary nocardiosis [11]. Staining methods as Gram stain and modified acid fast stain followed by culture in blood agar plate remains the ideal conventional methods in diagnosis of *Nocardia*, as neither Chest X-ray nor CT-chest is pathognomic. The usual turnaround time for conventional microbiological diagnosis is 1 week or even further which is due to its slow growth. On the contrary to this, newer techniques as polymerase chain reaction, MALDI TOF and 16s rDNA sequencing are more rapid and accurate in identification. Currently there are no serological tests available for nocardiosis [12]. In our case MALDI-TOF identification confirmed the species with a good probability.

The clinical presentation of nocardiosis varies from subacute to chronic presentation mimicking bacterial and fungal pathology. Fever, cough and malaise are the main presenting features as in our case that can lead to suspicion of tuberculosis especially in India where tuberculosis is endemic. Proper clinical examination of patients and appropriate respiratory sampling with importance to

modified acid fast staining to rule out *Nocardia* plays a pivotal role in this identification [13].

In our case sputum sample and Broncho Alveolar Lavage (BAL) both grew *Nocardia* which was speciated as *N. otitidiscaviarum* by MALDI-TOF.

The speciation of *Nocardia* is important as it has an influence on the susceptibility patterns. The pulmonary infection with *Nocardia* demands treatment for long duration and it is observed that antibiotic therapy for 6 months in immunocompetent and 1 year in immunocompromised patient have a better outcome. Studies have suggested that combination therapy with meropenem and parenteral cotrimoxazole for a period of 6 months aids in the efficacy of the treatment especially in critically ill patients [14]. Studies have reported that *N. otitidiscaviarum* has complex resistant mechanisms to beta lactam antibiotic as ampicillin, amoxicillin-clavulanic acid and imipenem but they have a good susceptibility to fluoroquinolones and amikacin. The optimal protocol for *N. otitidiscaviarum* pulmonary infection is still under debate and a combination therapy has proved to be effective [15]. Based on the susceptibility pattern to certain antibiotics, the speciation of *Nocardia* can be done in the microbiological laboratory. But in our case the patient showed a good response to combination treatment of cotrimoxazole and ciprofloxacin that was started following modified acid fast stain result and microbiology advice.

## Conclusion

In the recent times *N. otitidiscaviarum* has been emerging as a new respiratory pathogen. As this species is a slow grower longer incubation would increase the yield of this organism in the sample. Appropriate speciation and prompt treatment would aid in better outcome of the patient.

## References

- Sharma NL, Mahajan VK, Agarwal S, Katoch VM, Das R, Kashyap M, et al. Nocardial Mycetoma: Diverse clinical presentations. Indian J Dermatol Venereol Leprol. 2008;74:635-40.
- Schlaberg R, Huard RC, Della-Latta P. *Nocardia cyriacigeorgica*, an emerging pathogen in the United States. J Clin Microbiol. 2008;46(1):265-73.
- Hwang JH, Koh WJ, Suh GY, Chung MP, Kim H, Kwon OJ, et al. Pulmonary nocardiosis with multiple cavitary nodules in a HIV-negative immunocompromised patient. Intern Med. 2004;43(9):852-4.
- Clark NM, Braun DK, Pasternak A, Chenoweth CE. Primary cutaneous *Nocardia otitidiscaviarum* infection: Case report and review. Clin Infect

- Dis. 1995;20(5):1266-70.
5. Shahapur PR, Peerapur BV, Shahapur RP, Honnutagi RM, Biradar MS. Lymphocutaneous nocardiosis caused by *Nocardia otitidiscaviarum*: A case report and review of literature. *J Nat Sci Biol Med.* 2014;5(1):197.
  6. Kageyama A, Yazawa K, Ishikawa J, Hotta K, Nishimura K, Mikami Y. Nocardial infections in Japan from 1992 to 2001, including the first report of infection by *Nocardia transvalensis*. *Eur J Epidemiol.* 2004;19(4):383-9.
  7. Beaman BL, Burnside J, Edwards B, Causey W. Nocardial infections in the United States, 1972-1974. *J Infect Dis.* 1976;134(3):286-9.
  8. Ishihara M, Takada D, Sugimoto K, Oguro H, Gono T, Akiyama Y, et al. Primary brain abscess caused by *Nocardia otitidiscaviarum*. *Intern Med.* 2014;53(17):2007-12.
  9. Hemmersbach-miller M, Martel AC, Benítez AB, Sosa AO. Brain abscess due to *Nocardia otitidiscaviarum*: Report of a case and review. *Scand J Infect Dis.* 2004;36(5):381-4.
  10. Hui CH, Au VW, Rowland K, Slavotinek JP, Gordon DL. Pulmonary nocardiosis re-visited: Experience of 35 patients at diagnosis. *Respir Med.* 2003;97(6):709-17.
  11. Chawla K, Mukhopadhyay C, Payyanur P, Bairy I. Pulmonary nocardiosis from a tertiary care hospital in Southern India. *Trop Doct.* 2009;39(3):163-5.
  12. Shivaprakash MR, Rao P, Mandal J, Biswal M, Gupta S, Ray P, et al. Nocardiosis in a tertiary care hospital in North India and review of patients reported from India. *Mycopathologia.* 2007;163(5):267-74.
  13. Yildiz O, Doganay M. Actinomycoses and *Nocardia* pulmonary infections. *Curr Opin Pulm Med.* 2006;12(3):228-34.
  14. Kancharla R, Ramanathan RP, Appalaraju B, Rajagopala S. Pulmonary Nocardiosis presenting as exacerbation of chronic pulmonary disease. *Indian J Crit Care Med.* 2019;23(10):467-74.
  15. Liu C, Feng M, Zhu J, Tao Y, Kang M, Chen L. Severe pneumonia due to *Nocardia otitidiscaviarum* identified by mass spectroscopy in a cotton farmer: A case report and literature review. *Medicine.* 2017;96(13):e6526.