World Journal of Oral and Maxillofacial Surgery

Short Communication
Published: 21 May, 2018

Pterygoid Dental Implants: An Alternative Solution for Treatment of Posterior Atrophic Maxilla. Clinical Report on a Series of 20 Patients

Leon Ardekian[1]*, Leah Levit[2], Rafael Ishabaiv[1] and Michael Levit[3]

[1]*Department of Oral and Maxillofacial Surgery, Smile4 You Clinic, Israel*

[2]*Department of Lipid, Hadassah Medical Center, Israel*

[3]*Department of Prosthodontics, Hebrew University - Hadassah School of Dental Medicine, Israel*

Abstract

Posterior atrophic maxilla is very challenging to every surgeon to limit the implant placement. There are many surgical techniques are described for the reconstruction. In that sinus floor augmentation, alveolar distraction, guided bone regeneration, zygomatic implants and the use of pterygoid, pterygo-maxillary or ptyrego-tubrosity implants.

Introduction

The posterior maxilla has challenged surgeons by posing many limitations to implant placement [1,2]. Low bone quality and quantity, pneumatization of the maxillary sinus and poor accessibility to the area, are among the main reasons that make placement of dental implants difficult [3]. Furthermore, low bone density at implantation site reduces implant success due to impairment of primary stability [4-6].

Many surgical techniques have been described for reconstruction of the posterior maxilla, including sinus floor augmentation, alveolar distraction, guided bone regeneration, zygomatic implants and the use of pterygoid, pterygo-maxillary or ptyrego-tubrosity implants [7-11]. Among all the techniques mentioned above, the most popular one is the sinus floor augmentation, which has gained popularity over the last three decades [10,12]. However, it has its own drawbacks. The most described complications of sinus augmentation are sinus membrane perforation, bone graft infection and sinusitis [10-16]. This extensive surgical intervention could be avoided by utilizing a simpler method, such as pterygoid implants (Figures 1 and 2).

Materials and Methods

Twenty patients (10 men, 10 women) with a mean age of 55 years (range, 44 years to 71 years) were treated with pterygoid implants (Bioline Dental Implants, Frankfurt, Germany) at a private practice facility from 2015 to 2016. Fifteen patients had bilateral pterygoid implants, and five patients had a unilateral implant. The total number of implants was 35. A Cone Beam Computed Tomography (CBCT) was performed in each case, in order to evaluate the proximity to the sinus and to assess the pterygoid area. Risks, benefits, and alternatives of the pterygoid implants were described to the patients, and a written informed consent was obtained from each patient. Ethical approval was not applicable for this study, due to the retrospective nature of data analysis.

A full mucoperiosteal flap was raised, and the pterygomaxillary fissure was identified and probed (Figure 1). Implant site preparation began with marking the alveolar ridge by a small round bar in the site previously occupied by the first or second molar tooth. A pilot drill was used in order to establish the initial direction of the pterygoid implant, then the implant bed was enlarged by a sequence of drills and osteotoms with increasing diameter, according to the original technique described by Valero and Valero [17-21]. Pterygoid implants were diagonally inserted superiorly, posteriorly and distally, towards the pterygopalatine fossa of the sphenoid bone (Figure 2). The distal angulation of the pterygoid implants varied between 35 degrees to 55 degrees, in relation to the sagittal plane. This angle size was determined by the maxillary sinus floor and by the tuberosity height [18-20,22]. All implants were submerged for a healing period of 4 months to10 months. Complete absence of any noticeable mobility of the implant at stage II surgery was considered as

OPEN ACCESS

Correspondence:
Leon Ardekain, Department of Oral and Maxillofacial Surgery, Smile4 You Clinic, Reshon Le Zion, Specialist in Oral Maxillofacial Surgeon, Consultant Medical Investment, Nazareth Israel, Israel,
E-mail: surgery@gmail.com

Received Date: *01 Apr 2018*
Accepted Date*: 18 May 2018*
Published Date*: 21 May 2018*

Citation:
Ardekian L, Levit L, Ishabaiv R, Levit M. Pterygoid Dental Implants: An Alternative Solution for Treatment of Posterior Atrophic Maxilla. Clinical Report on a Series of 20 Patients. World J Oral Maxillofac Surg. 2018; 1(2): 1007.

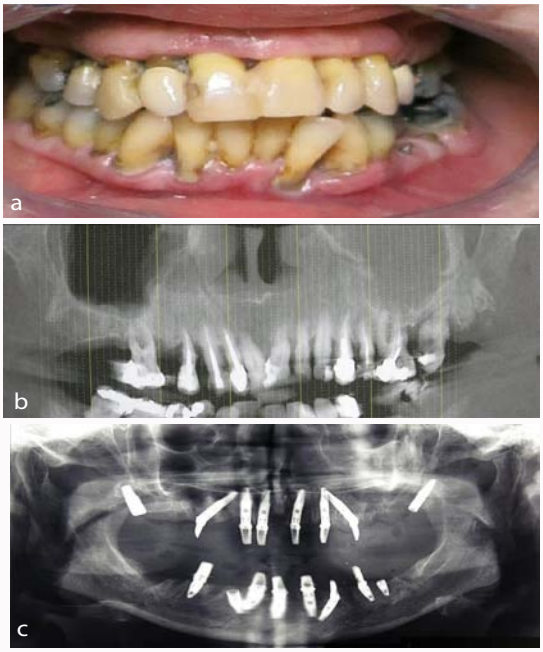

Figure 1: (a) Preoperative clinical photograph of a 54 years female patient before full mouth implant rehabilitation. The dentition was involved in severe periodontal disease, grade 3 mobility and failing restorations. (b) Preoperative Cone beam CT. The posterior maxillae were highly pneumatized, with residual bone height of 4 mm or less. Left sinus appeared to be obliterated. (c) Bilateral pterygoid implants were successfully inserted, together with six conventional implants in the anterior maxilla, bypassing both sinuses. The anterior implants were immediately loaded and the patient was provided with temporary full arch acrylic bridge at the end of the surgery.

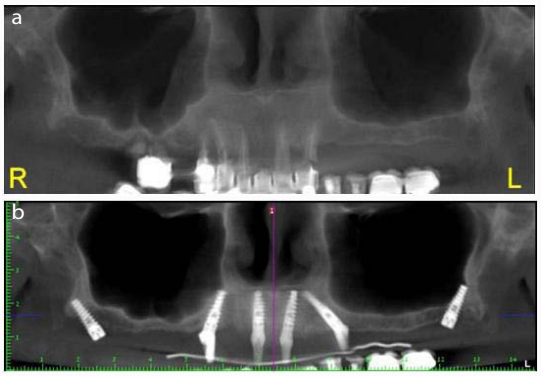

Figure 2: (a) Very extensive maxillary sinus, bilateral. The sinuses occupy the entire body of the maxillae and extend anteromedialy to the premaxilla, posterolateraly into the infratemporal regions and superolaterally into the zygomatic process of maxilla. The residual height of the alveolar ridges is 4 mm or less. (b) Postoperative CBCT scan showing bilateral pterygoid implants. The four conventional implants in the premaxilla were immediately loaded and the patient was provided with temporary acrylic bridge with shortened span.

success and osseointegration. If the implant was mobile to any extent, it was noted as failure. The implant lengths were 16 mm, 18 mm, 20 mm and 22 mm.

Results

Thirty two of 35 pterygoid implants successfully osseointegrated, yielding a survival rate of 91.4%. The average follow up period after stage I surgery was 11 month (range 7-16). The failed implants were detected only at stage II surgery. No failures were detected after prosthetic loading within the follow up period. No bleeding or other intraoperative or postoperative adverse events were observed.

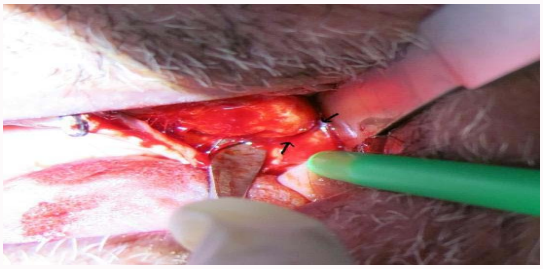

Figure 3: Identification of the pterygomaxillary fissure (marked with arrows) and the maxillary tuberosity before implant bed preparation.

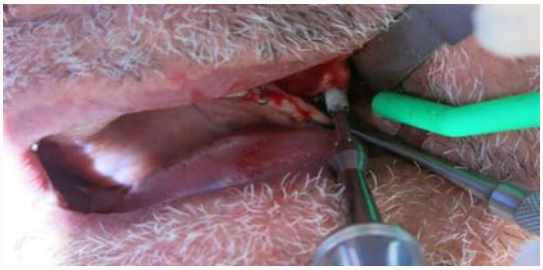

Figure 4: Insertion of the pterygoid implant. Note the angle between the path of insertion to the palate and the maxillary tuberosity.

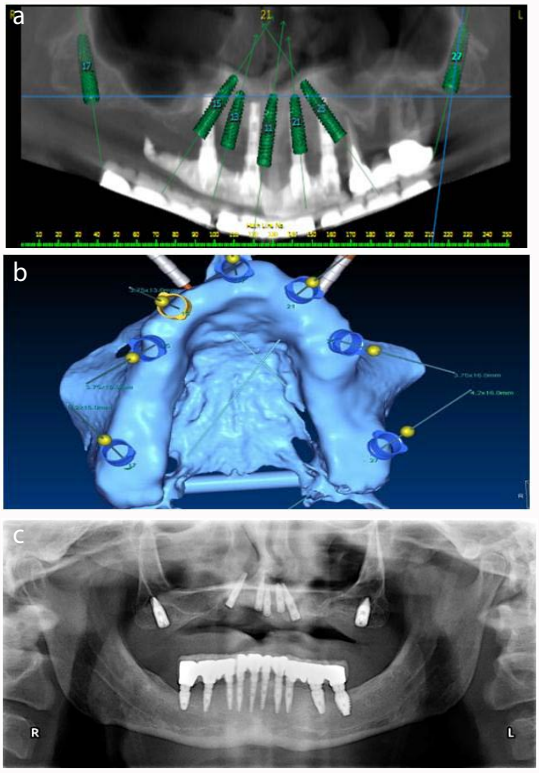

Figure 5: (a) Computer aided design of upper jaw implantation utilizing bilateral pterygoid implants with five anterior conventional implants. The path of insertion of the new implants is drawn and superimposed over the existing failing implants and teeth of the patient. (b)Hard tissue supported surgical guided. Note the two anterior screws that fixate the guide to the maxillary basal bone during the implantation. (c) Postoperative panoramic X-ray showing implants in place.

Discussion

The aim of the present study was to evaluate the survival rate of the pterygoid implants in a short to moderate time period. The reported survival rates of pterygoid implants reported in this study are in the range reported in the litherature to date. Balshi et al. [19-21,23] reported three clinical series of pterygoid implants. In 1995, they made a preliminary study in which 51 pterygoid implants with machined surface were placed in 41 patients, with a follow-up period of 1month to 63 months. The success rate was 86.3%. In 1999, they increased the sample to 356 implants, obtaining a cumulative success rate of 88.2%, after a mean loading period of 56 month. Of note, most implants (41) failed at stage II surgery before loading, and only one implant failed after loading. In 2005, they placed 164 pterygoid implants with titanium oxide surfaces. After 54 month of follow-up, the success rate was statistically significantly higher than in previous studies (96.3%). The authors related this additional 8.1% percentage points gain in implant survival to the change of implant surface from machined to titanium oxide. Vrielinck et al. [24] placed 14 pterygomaxillary implants and had a success rate of 71%, after an average follow-up of 6 months to 24 months. The failures occurred because the implants did not follow the direction of the prepared implant bed and were, therefore, out of place. Ridell et al. [25] reported a 100% success rate after placing 22 implants in the maxillary tuberosity area and after follow-up of 12 years.

Pterygoid implants are anchored in the junction of three different bone structures: The pyramidal process of the palatal bone, the pterygoid process of the sphenoid bone and the maxillary tuberosity. This insertion into three different anatomic structures may often lead to improper terminology usage when relating to pterygoid implants. There is a significant difference between pterygoid and tuberosity implants. Pterygoid implants are engaged in the dense cortical part of the pterygoid bone and the palatal bone, while tuberosity implants are directed and engaged in cancellous maxillary bone of poor quality [14,15,17]. Placement of dental implants in the pterygo-maxillary region provides posterior bone support for the prosthesis, without sinus floor augmentation, and can achieve better distribution of masticatory forces in comparison to conventional maxillary implants. This benefit allows rehabilitating patients with satisfactory full arch fixed maxillary prosthesis, which usually spanned from second molar to second molar (Figure3) [17,19,20].

Due to the special architectural features of the pterygo-maxillary area, placement of dental implants in this area is technically more difficult in comparison to other regions of the maxilla. Computer Aided Design - Computer Aided Manufacturing (CAD-CAM) is of great value in planning and placing pterygoid implants, as well as other implants that bypass the maxillary sinus. The surgical guide enables the clinician to determine the exact direction of drilling and the correct length of pterygoid implants (Figure 4). Despite the complexity of this surgical procedure, the risk of complications is very low [14-16]. A possible major complication that may occur during the surgery is massive bleeding from the maxillary artery or its branches, which are situated 1 cm superiorly to the pterigomaxillary suture [17,21,26]. This complication is rare and has not been mentioned in the literature, according to the best knowledge of the authors. Regardless of the surgical technique used, care must be taken to avoid damaging either the maxillary artery or its branches within the pterygopalatine fossa. However, the distance from the inferior end of the pterygomaxillary suture to the maxillary artery is 25 millimeters, which makes this area safe for working. Valero´n and Valero´n [27] described a minor venous bleeding, caused by over-insertion of the drill a few millimeters into the venous plexus in the retropterygoid area. The bleeding was stopped with local hemostatic methods. Krekmanov reported difficulties when anchoring the implants into the pterygoid process [28]. An implant was lost during placement due to over-drilling beyond the pterygoid process. Vrielinck et al. [24] lost 4 of 6 implants due to problems in placing them in the initially drilled implant bed. The repeated attempts to drill in different directions, in order to improve the design of the implant bed, resulted in insufficient bone anchorage, which jeopardized primary stability of the pterygoid implant (Figure 5).

Conclusion

Pterygoid implants have a high success rate, minor and infrequent complications and similar bone loss in comparison to conventional implants.

Pterygoid implants are considered as a good alternative for extensive augmentation procedure in patients with atrophic maxilla.

References

1. Javed F, Romanos GE. Role of implant diameter on long-term survival of dental implants placed in posterior maxilla: a systematic review. Clin Oral Investig. 2015;19(1):1-10.
2. Song HY, Huh YH, Park CJ, Cho LR. A two-short-implant-supported molar restoration in atrophic posterior maxilla: A finite element analysis. J Adv Prosthodont. 2016;8(4):304-12.
3. Jinfeng L, Jinsheng D, Xiaohui W, Yanjun W, Ningyu W. The Pneumatization and Adjacent Structure of the Posterior Superior Maxillary Sinus and Its Effect on Nasal Cavity Morphology. Med Sci Monit. 2017;23:4166-74.
4. Zita Gomes R, de Vasconcelos MR, Lopes Guerra IM, de Almeida RAB, de Campos Felino AC. Implant Stability in the Posterior Maxilla: A Controlled Clinical Trial. Biomed Res Int. 2017;2017:6825213.
5. Ko YC, Huang HL, Shen YW, Cai JY, Fuh LJ, Hsu JT. Variations in crestal cortical bone thickness at dental implant sites in different regions of the jawbone. Clin Implant Dent Relat Res. 2017;19(3):440-6.
6. Kim YH, Choi NR, Kim YD. The factors that influence postoperative stability of the dental implants in posterior edentulous maxilla. Maxillofac Plast Reconstr Surg. 2017;39(1):2.
7. Degidi M, Daprile G, Piattelli A. Influence of Stepped Osteotomy on Primary Stability of Implants Inserted in Low-Density Bone Sites: An In Vitro Study. Int J Oral Maxillofac Implants. 2017;32(1):37-41.
8. Degidi M, Daprile G, Piattelli A. Influence of underpreparation on primary stability of implants inserted in poor quality bone sites: an in vitro study. J Oral Maxillofac Surg. 2015;73(6):1084-8.
9. Parra M, Olate S, Cantín M. Clinical and biological analysis in graftless maxillary sinus lift. J Korean Assoc Oral Maxillofac Surg. 2017;43(4):214-20.
10. Rodríguez X, Lucas-Taulé E, Elnayef B, Altuna P, Gargallo-Albiol J, Peñarrocha Diago M, et al. Anatomical and radiological approach to pterygoid implants: a cross-sectional study of 202 cone beam computed tomography examinations. Int J Oral Maxillofac Surg. 2016;45(5):636-40.
11. Butterworth CJ, Rogers SN. The zygomatic implant perforated (ZIP) flap: a new technique for combined surgical reconstruction and rapid fixed dental rehabilitation following low-level maxillectomy. Int J Implant Dent. 2017;3(1):37.
12. Cara-Fuentes M, Machuca-Ariza J, Ruiz-Martos A, Ramos-Robles MC, Martínez-Lara I. Long-term outcome of dental implants after maxillary

augmentation with and without bone grafting. Med Oral Patol Oral Cir Bucal. 2016;21(2):e229-35.

13. Ardekian L, Oved-Peleg E, Mactei EE, Peled M. The clinical significance of sinus membrane perforation during augmentation of the maxillary sinus. J Oral Maxillofac Surg. 2006;64(2):277-82.
14. Morand M1, Irinakis T. The challenge of implant therapy in the posterior maxilla: providing a rationale for the use of short implants. J Oral Implantol. 2007;33(5):257-66.
15. Pabst AM, Walter C, Ehbauer S, Zwiener I, Ziebart T, Al-Nawas B, et al. Analysis of implant-failure predictors in the posterior maxilla: a retrospective study of 1395implants. J Craniomaxillofac Surg. 2015;43(3):414-20.
16. Curi MM, Cardoso CL, Ribeiro Kde C. Retrospective study of pterygoid implants in the atrophic posterior maxilla: implant and prosthesis survival rates up to 3 years. Int J Oral Maxillofac Implants. 2015;30(2):378-83.
17. Peñarrocha M1, Carrillo C, Boronat A, Peñarrocha M. Retrospective study of 68 implants placed in the pterygomaxillary region using drills and osteotomes. Int J Oral Maxillofac Implants. 2009;24(4):720-6.
18. Nocini PF1, Albanese M, Fior A, De Santis D. Implant placement in the maxillary tuberosity: the Summers' technique performed with modified osteotomes. Clin Oral Implants Res. 2000;11(3):273-8.
19. Balshi TJ1, Lee HY, Hernandez RE. The use of pterygomaxillary implants in the partially edentulous patient: a preliminary report. Int J Oral Maxillofac Implants. 1995;10(1):89-98.
20. Balshi TJ, Wolfinger G, Balshi S 2nd. Analysis of 356 pterygomaxillary implants in edentulous arches for fixed prosthesis anchorage. Int J Oral Maxillofac Implants. 1999;14(3):398-406.
21. Fernandez-Valeron J, Fernandez-Velazquez J. Placement of screw-type implants in the pterygomaxillary pyramidal region: Surgical procedure and preliminary results. Int J Oral Maxillofac Implants. 1997;12(6):814-9.
22. Rehabilitation of the atrophic posterior maxilla with pterygoid implants: a review. Candel E, Peñarrocha D, Peñarrocha M. J Oral Implantol. 2012;38(Sp No):461-6.
23. Balshi SF, Wolfinger GJ, Balshi TJ. Analysis of 164 titanium oxide-surface implants in completely edentulous arches for fixed prosthesis anchorage using the pterygomaxillary region. Int J Oral Maxillofac Implants. 2005;20(6):946-52.
24. Vrielinck L, Politis C, Schepers S, Pauwels M, Naert I. Image-based planning and clinical validation of zygoma and pterygoid implant placement in patients with severe bone atrophy using customized drill guides. Preliminary results from a prospective clinical follow-up study. Int J Oral Maxillofac Surg. 2003;32(1):7-14.
25. Ridell A, Gröndahl K, Sennerby L. Placement of Brânemark implants in the maxillary tuber region: anatomical considerations, surgical technique and long-term results. Clin Oral Implants Res. 2009;20(1):94-8.
26. Mateos L, García-Calderón M, Gonzalez-Martin M, Gallego D, Cabezas J. Inserción de implantes dentales en la apófisis pterigoides: una alternativa en el tratamiento rehabilitador el maxilar posterior atrófico. Av Periodon Implantol. 2002;14(l):37-45.
27. Valerón JF1, Valerón PF. Long-term results in placement of screw-type implants in the pterygomaxillary-pyramidal region. Int J Oral Maxillofac Implants. 2007;22(2):195-200.
28. Krekmanov L. Placement of posterior mandibular and maxillary implants in patients with severe bone deficiency: a clinical report of procedure. Int J Oral Maxillofac Implants. 2000;15(5):722-30.