World Journal of Oral and Maxillofacial Surgery

Case Report
Published: 30 Apr, 2018

Pseudoaneurysm as a Complication of Orthognathic Surgery: A Case Report

Constantinos Laskarides[1]* and Adel M. Malek[2]

[1]Department of Oral & Maxillofacial Surgery, Tufts University, USA

[2]Department of Neurosurgery, Tufts Medical Center, USA

Abstract

The LeFort I osteotomy surgery is a well-established method of manipulating the position of the maxilla in all three planes of space. It may be used alone or in combination with mandibular surgery to aid in correction of dentofacial deformities. As with all surgery, orthognathic surgery is not without risks and complications. Vascular injuries in LeFort I osteotomies are commonly associated with damage of the Descending Palatine (DP) or Sphenopalatine Arteries (SPA) which are in close approximation to the pterygomaxillary junction. This junction is separated to allow for down fracture of the maxillae. In respect to orthognathic surgery to the maxillae, it has been long the surgeon's concern for increased bleeding during LeFort osteotomy procedures.

An exceedingly rare complication from orthognathic surgery is traumatic aneurysm to the external carotid and its attributaries. Vessel wall trauma leading to sub adventitial dissection (between the tunica media and adventitia) results in the formation of aneurysmal dilatation of the vessel. Dissecting psuedoaneurysm develops when the true arterial lumen communicates with the dissecting cavity.

The small caliber of the tributaries of the external carotid makes a pseudoaneurysm uncommon as a complete transection of the vessel is more likely to occur. The surgical correction of the aneurysm is indicated as soon as possible to decrease the risk of complications, including hemorrhage from rupture, thrombosis, infection, or neurologic dysfunction caused by continued expansion. In this case report we describe an unusual case of a pseudoaneurysm after LeFort I osteotomy, for impaction and advancement of the maxilla.

OPEN ACCESS

****Correspondence:***
Constantinos Laskarides, Department of Oral & Maxillofacial Surgery, Advanced Specialty Program Director, Tufts University, One Kneel and street, Boston, MA 02111, USA, Tel: 1-617-636-6515; Fax: 1-617-636-6809; E-mail: constantinos.laskarides@tufts.edu

Received Date: *03 Apr 2018*
Accepted Date*: 27 Apr 2018*
Published Date*: 30 Apr 2018*

Citation:
Laskarides C, Malek AM. Pseudoaneurysm as a Complication of Orthognathic Surgery: A Case Report. World J Oral Maxillofac Surg. 2018; 1(1): 1003.

Introduction

LeFort I osteotomy surgery is a well-established method of manipulating the position of the maxillae in all three planes of space. Pioneered by Dr. Cheever in 1864, to access nasopharyngeal masses, the surgical technique has been refined over time and is now the workhorse of orthognathic maxillary surgery. It may be used alone or in combination with mandibular surgery to aid in correction of dentofacial deformities.

As with all surgery, orthognathic surgery is not without risks and complications. Vascular injuries in LeFort I osteotomies are commonly associated with damage of the Descending Palatine (DP) or Sphenopalatine Arteries (SPA) which are in close approximation to the pterygomaxillary junction. This junction is separated to allow for down fracture of the maxillae [1]. In respect to orthognathic surgery to the maxillae, it has been long the surgeon's concern for increased bleeding during LeFort osteotomy procedures. Many maneuvers have been devised to reduce bleeding due to the rich vascularity surrounding the maxillae. It is not uncommon for the surgeon to utilize reverse Trendelenburg position or hypotensive anesthesia. Some surgeons have also advocated the use of tranexamic acid to reduce blood loss [2]. It is some surgeon's preference, in fact, to ligate the descending palatine arteries during a Le Fort I osteotomy to avoid post-operative bleeding.

An exceedingly rare complication from orthognathic surgery is traumatic aneurysm to the external carotid and its attributaries. In a survey, among oral and maxillofacial surgeons, there was a reported case incidence of 0.75% following orthognathic surgery [3]. Vessel wall trauma leading to subadventitial dissection (between the tunica media and adventitia) results in the formation of aneurysmal dilatation of the vessel. Dissecting psuedoaneurysm develops when the true arterial lumen communicates with the dissecting cavity [4].

The small caliber of the tributaries of the external carotid makes a pseudoaneurysm uncommon

Figure 1: A and B are pre operative showing retrognathia, microgenia and vertical maxillary excess. C and D shows the patient 6 months post-operatively.

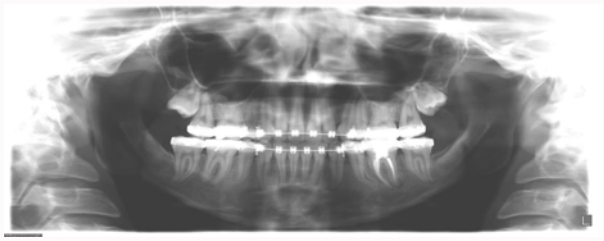

Figure 2: Pre Operative orthopantogram. Teeth 1 and 16 are impacted.

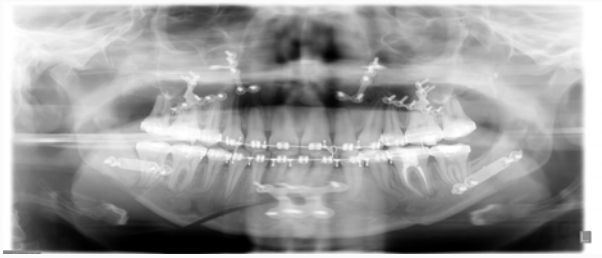

Figure 3: Post operative orthopantogram.

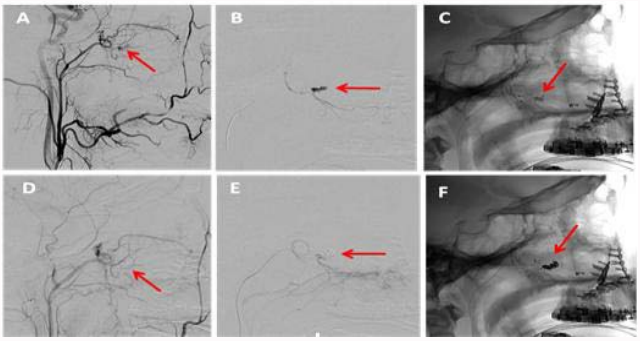

Figure 4: Top row: A: Lateral external carotid artery injection demonstrates a psuedoaneurysm (arrow) of the sphenopalatine artery, B: Lateral view of superselective injection of distal internal maxillary artery demonstrating pseudoaneurysm, C: Lateral view of unsubtracted images of the same.
Bottom row: D: Lateral view of external carotid artery injection, E: Superselective distal internal maxillary artery followed by F: Unsubtracted view of the same after coil embolization of the pseudoaneurysm.

as a complete transection of the vessel is more likely to occur. In addition, their protective deep locations also make this complication rare [5-7]. The surgical correction of the aneurysm is indicated as soon as possible to decrease the risk of complications, including hemorrhage from rupture, thrombosis, infection, or neurologic dysfunction caused by continued expansion. In this case report we describe an unusual case of a pseudoaneurysm after LeFort I osteotomy, for impaction and advancement of the maxilla.

Case Report

A 22-year-old healthy female was referred to the Oral and Maxillofacial surgery department for evaluation and surgical correction of Class II skeletal discrepancy. The patients' chief complaints were functional difficulty with chewing and biting, malocclusion, speech impediment, temporomandibular joint-associated discomfort and discontent with physical appearance and facial harmony. She was diagnosed with maxillary vertical excess, mandibular hypoplasia, microgenia, dental midline discrepancy and impacted 3rd molars (Figures 1 and 2). During the pre-operative phase, she underwent orthodontic preparation and removal of impacted teeth #17 and 32. Due to the high level of impaction teeth #1 and 16 where scheduled to be removed at the time of her orthognathic surgery. After a thorough evaluation and model surgery the patient was planned for:

1. LeFort I osteotomy for maxillary impaction of 6 mm and advancement of 2 mm.

2. Bilateral sagittal split osteotomy for mandibular advancement of 5 mm and rotation 3 mm to the left.

3. Advancement genioplasty of 4 mm.

4. Removal of impacted maxillary third molars through the maxillary down-fracture.

There were no intraoperative complications. The LeFort I osteotomy was completed without difficulty and was stabilized with four 1.7 mm plates. The mandibular osteotomy was completed and secured with 2 mm BSSO plates and the genioplasty was completed and secured with a 2.0 mm genioplasty plate (Figure 3). The total blood loss was estimated to be less than 150 cc. The patient followed a conventional hospital course with discharge to home in 2 days.

Approximately two weeks postoperatively, patient developed recurrent episodes of epistaxis that were self-resolving. The patient described a worsening headache and sense of ascending pulsating pressure with eventual release prior to her nasal bleeds. She had attempted to keep her nasal passages moist with normal saline rinses and humidified air. The episodic bleeds continued and began to increase in severity. One episode had been severe enough to require services of the emergency department where a nasal tamponade device was inserted with good effect. The tamponade device was removed 72 hours later uneventfully. She was asymptomatic for 4 days after the nasal device was removed.

The suspicion for a pseudoaneurysm was entertained as she continued to experience episodes of epistaxis. A head and neck magnetic resonance angiogram study showed no evidence of acute abnormality but was limited due to artifact. Diagnostic cerebral angiography followed and revealed a late filling of a 6.05 mm × 4.75 mm pseudoaneurysm in the distal portion of the right SPA branch of the Maxillary Artery (MA) (Figure 4A,B and C). Patient underwent

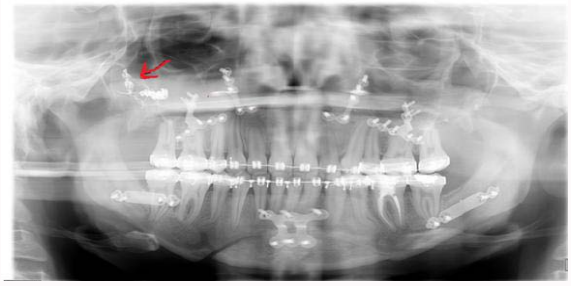

Figure 5: Post Coiling Orthopantogram.

coiling of the pseudoaneurysm sac followed by successful onyx® mediated embolization of the parent vessel (Figure 4D,E,F and 5). She had an uncomplicated post-operative course and was discharged on hospital day two. After one year of follow up the patient has not had a recurrence of epistaxis and continues to be satisfied with her occlusion and facial appearance.

Discussion

Maxillary osteotomies, for orthognathic surgery, have the potential for severe bleeding complications. They may present immediately as an intraoperative hemorrhage or as post-operative hematoma or epistaxis. The Maxillary Artery (MA) and its branches are located in the pterygopalatine fossa and are amenable to injury when the maxillary tuberosity is separated from the pterygoid plates, separation of the lateral nasal or during down fracture of maxillae. The course of MA and its branches in relation with the LeFort I osteotomy has been extensively studied. The two most commonly injured branches of the MA are the SPA and the DP arteries with the DP being the most commonly injured. Choi *et al.* [8] using human cadavers measured the branching distance of the DP from the maxillary artery using the most inferior edge of the Pteryg Mandibular Junction (PMJ) and found on average the branching distance was 24.8 mm +/- 2.8 mm. They further suggest the osteotomy should be less than 20 mm above the most inferior edge of the PMJ to avoid damage to the DPA in addition to angling the osteotomy from the zygomatico-maxillary crest.

The SPA, a major blood vessel of the nasal mucosa, exits from the sphenopalatine foramen and supplies the turbinates located on the lateral nasal wall and the nasal septum. Lee *et al.* studied the course of the SPA and found that in 90% of the cases, the foramen was located within the superior meatus, between the middle turbinate and the posterior horizontal end of the lamella of the superior turbinate, attaching to the lateral nasal wall. In 10% of cases, the foramen extended superiorly beyond the posterior horizontal portion of the lamella of the superior turbinate. They did not report any cases of the foramen extending inferiorly beyond the middle turbinate. They found that the foramen was 59.4 mm +/- 2 mm from the nasal sill.

Aneurysms are very rare after orthognathic surgery. To this day there are only 19 reported cases; the sphenopalatine branch of the MA was involved in 6 out of the 19 cases [7,9,10]. Initial presentation of a false aneurysm is a recurrent or persistent unilateral epistaxis refractory to anterior and posterior nasal packing with the possible addition of pain and persistent edema [7,11]. Most patients will not demonstrate marked intraoperative hemorrhage [11]. In some cases, such as the one presented here, patients will note a pulsation that matches the heartbeat. A pseudoaneurysm can present anywhere from two to eight weeks postoperatively but has been reported as far out as eight months [6,7,11].

The optimal treatment for a pseudoaneurysm of the MA is angiography with embolization [11]. The main advantage of angiographic embolization it requires less manipulation in the area of the osteotomy sites, encouraging bony healing. Additionally, it allows for identification if the contralateral arterial tree is contributing to the problem if actively bleeding.

The first successful use for treatment of refractory epistaxis via embolization of the maxillary artery was described in the 1930s [12]. Simply embolization of the MA may not adequately treat the problem. If embolization is to be successful, it must be done in conjunction with all the accessory feedings vessels of the pseudoaneurysm and as close to the pseudoaneurysm as possible. This is of great importance, especially shortly after orthognathic surgery where the limited maxillary blood supply may be critically compromised with subsequent development of potential devastating aseptic necrosis of the maxillae [6]. Since described by Sokoloff, there have been many advances to allow more accurate treatment while sparing proximal vessels including the use of variable stiffness microcatheters for super selective injections, flow control techniques, and an array of embolization materials. The greatest complication of embolization of the IMA includes stroke and blindness secondary to reflux of embolization material outside the intended vessel.

Conclusion

Pseudoaneurysms associated with orthognathic surgery are exceedingly rare but should be suspected with presentation of persistent epistaxis 2 weeks, or more, post orthognathic surgery or acute facial swelling beyond the perioperative period. A traditional work up including stabilization of the patient should be completed, including ruling out coagulopathies. Appropriate imaging including MRA and angiography are required. Treatment involves multidisciplinary team of specialists including a neurovascular surgeon. Early diagnosis and treatment of a pseudoaneurysm is essential to minimize morbidity and mortality.

References

1. Li KK, Meara JG, Alexander A. Location of the descending palatine artery in relation to the Le Fort I osteotomy. J Oral Maxillofac Surg. 1996;54(7):822-5.
2. Song G, Yang P, Hu J, Zhu S, Li Y, Wang Q. The effect of tranexamic acid on blood loss in orthognathic surgery: a meta-analysis of randomized controlled trials. Oral Surg Oral Med Oral Pathol Oral Radiol. 2013:115(5):595-600.
3. Chepla KJ, Totonchi A, Hsu DP, Gosain AK. Maxillary Artery Pseudoaneurysm After Le Fort I Osteotomy: treatment using transcatheter arterial embolization. J Craniofacl Surg. 2010;21(4):1079-81.
4. Anson J, Crowell RM. Cervicocranial arterial dissection. Neurosurgery. 1991;29(1):89-96.
5. Lanigan DT, Hey JH, West RA. Major vascular complications of orthognathic surgery: false aneurysms and arteriovenous fistulas following orthognathic surgery. J Oral Maxillofac Surg. 1991;49(6):571-7.
6. Bradley JP, Elahi M, Kawamoto HK. Delayed presentation of pseudoaneurysm after Le Fort I osteotomy. J Craniofac Surg. 2002;13(6):746-50.
7. Avelar RL, Goelzer JG, Becker OE, de Oliveira RB, Raupp EF, de Magalhães PS. Embolization of Pseudoaneurysm of the Internal Maxillary Artery

After Orthognathic Surgery. J Craniofac Surg. 2010;21(6):1764-8.

8. Choi J, Park HS. The clinical anatomy of the maxillary artery in the pterygopalatine fossa. J Oral Maxillofac Surg. 2003;61(1):72-7.

9. Procopio O, Fusetti S, Liessi G, Ferronato G. False aneurysm of the sphenopalatine artery after a Le Fort I osteotomy: report of 2 cases. J Oral Maxillofac Surg. 2003;61(4):520-4.

10. Bays RA, Bouloux GF. Complications of orthognathic surgery. Oral and Maxillofac Surg Clin North Am. 2003;15(2):229-42.

11. Krempl GA, Noorily AD. Pseudoaneurysm of the descending palatine artery presenting as epistaxis. Otolaryngol Head Neck Surg. 1996;114(3):453-6.

12. Sokoloff J, Wickbom I, McDonald D, Brahme F, Goergen TC, Goldberger LE. Therapeutic percutaneous embolization in intractable epistaxis. Radiology. 1974;111(2):285-7.