



## Primary Histiocytic Sarcoma of Parotid Gland: A Case Report and Review of Literature

Marwa T Hussien\*

Department of Oncologic Pathology, South Egypt Cancer Institute, Assiut University, Egypt

### Abstract

A case of female patient 55 years old, presented with painful right cheek mass, diagnosed as primary histiocytic sarcoma of parotid gland, immune confirmed. There is no lymph nodal involvement by lymphoma or metastatic disease at initial presentation.

### Introduction

Histiocytic Sarcoma (HS) is a very rare neoplasm of hematopoietic origin. It accounts less than 1% of all malignancies of the hematopoietic system [1]. It formed of proliferation of malignant cells showing morphologic and immunophenotypic features similar to those of mature tissue histiocytes [2]. It can arise as a *de novo* primary malignancy or, less commonly, a secondary malignancy. There are multiple reports of presumed trans-differentiation from low-grade B-cell lymphoma to histiocytic sarcoma; this accounts for approximately one-fourth of cases [3]. The most frequent extranodal sites of histiocytic are the skin, spleen and gastrointestinal tract [4-6]. Histologically it is composed of a diffuse proliferation of large; round too void pleomorphic cells [7].

### Materials and Methods

#### Clinical history

A 55 years old South Egyptian woman was admitted to the surgical oncology department at South Egypt Cancer Institute, Assiut University with a complaint of painful right cheek swelling. The medical and familial history was unremarkable.

Ultrasonography revealed ill-defined hyperechoic nodule in right parotid gland measured 8.5 cm × 6.5 cm. Contrast-enhanced axial CT image shows a solitary solid mass with ill-defined margins in the right parotid gland. The patient diagnosed as basaloid neoplasm by fine needle aspiration cytology.

At our institute, the patient underwent parotidectomy with safety margin. Postoperative CT pelvis revealed no residual lesion at tumor bed. Patient was referred to the medical oncology department. Metastatic work up was done and CT Chest revealed no metastatic deposits. Patient treatment plan was parotidectomy with safety margin.

Parotidectomy specimen was referred to our pathology department and dissected according to dataset guidelines of the Royal College of Pathologists.

#### Immunohistochemistry

Four-micron-thick sections were cut from the paraffin blocks, which were evaluated for immunohistochemistry. Immunostaining was performed using an automated staining machine (Dako Autostainer Link 48). The following primary antibodies were used: CK (AE1/AE3), LCA (CD 45), Vimentin, P63, S100, CD138 (MI15), CD117, CD34, CD68, ki67 (MIB1) and P53. Markers were ready to use provided from Dako. Antigen retrieval was done in PT link using Dako system (Target Retrieval Solution, High pH, concentrated 50x Dako). Blocking of endogenous peroxidase activity was performed using Dako peroxidase blocking reagent. Slides were incubated with the primary antibody and then with a universal staining kit Horseradish Peroxidase (HRP). The slides were visualized with Diaminobenzidine (DAP solution) and subjected to haematoxylin counterstaining. Images and measurements were captured using Toup-Cam (XCAM Full HD Camera, model number: XCAM1080PHB).

### OPEN ACCESS

#### \*Correspondence:

Marwa T Hussien, Department of Oncologic Pathology, South Egypt Cancer Institute, Assiut University, Assiut, Egypt,  
E-mail: dr.marwa\_hussien@yahoo.com

Received Date: 05 Nov 2019

Accepted Date: 28 Nov 2019

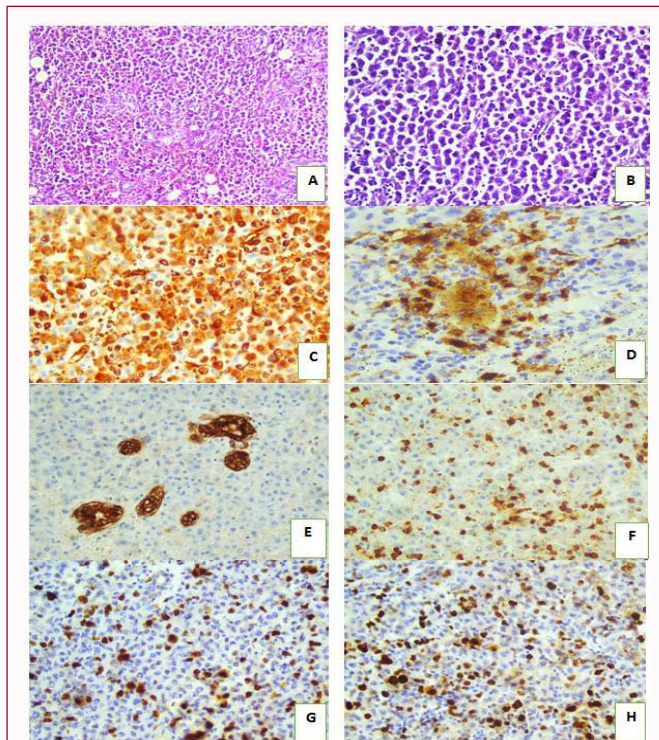
Published Date: 02 Dec 2019

#### Citation:

Hussien MT. Primary Histiocytic Sarcoma of Parotid Gland: A Case Report and Review of Literature. *Surg Oncol Clin Pract J.* 2019; 2(2): 1011.

Copyright © 2019 Marwa T

Hussien. This is an open access article distributed under the Creative Commons Attribution License, which permits unrestricted use, distribution, and reproduction in any medium, provided the original work is properly cited.



**Figure 1:** Microscopic picture and immunohistochemistry of parotid histiocytic sarcoma:

A: low power examination (x10) showed diffuse infiltration by sheets of large discohesive cells B: High power examination (x40) exhibit tumor cells with variable degree of pleomorphism, ample eosinophilic cytoplasm and large irregular nuclei. C: Tumor cells stained positively for both vimentin and D: CD68. E: Tumor cells were negative for CK; CK stained residual parotid acini (internal positive control). F: Tumor cells were negative for LCA, LCA stained tumor-infiltrating lymphocytes. G: Ki67 was high in reaching 40% (in hot spot). H: p53 strongly expressed in 50% of tumor cells.

## Results

### Pathological findings

**Gross findings:** Sections from the parotidectomy specimen showed an ill-defined large indurated tumor mass, replacing the normal parotid tissue. Serial sections showed heterogeneous grey white cut section with rubbery consistency, measuring 9 cm × 7 cm × 4.5 cm. It located 3 mm away from the surrounding labeled margins grossly.

**Microscopic findings:** Microscopically, the parotid tissue was diffusely infiltrated by sheets of large discohesive cells (Figure A). Tumor cells showed variable degree of pleomorphism with ample eosinophilic cytoplasm, large irregular nuclei, clumped chromatin, single and multiple conspicuous nucleoli as well as scattered multinucleated giant cells (Figure B). Tumor was confined to the parotid gland, and touched the inked margins all around, Tumor cells was immuno-confirmed, stained positively for both vimentin (Figure C) and CD68 (Figure D). Tumor cells were negative for CK (Figure E), LCA (Figure F), P63, S100, CD138, CD117 and CD34. Ki67 was high in reaching 40% (in hot spots) (Figure G) and p53 strongly expressed in 50% of tumor cells.

The diagnosis was primary histiocytic sarcoma of parotid gland. No associated histiocytic sarcoma in regional and non-regional lymph nodes. The patient was staged as pT3N0M0, according to.

## Discussion

Histiocytic Sarcoma (HS) is an extremely rare malignant neoplasm showing morphologic and immunophenotypic evidence of histiocytic differentiation. The vast majority of previously reported histiocytosarcomas are now generally recognized to be misdiagnosed examples of non-Hodgkin lymphomas, predominantly diffuse large B-cell lymphoma or anaplastic large cell lymphoma [8]. The extranodal histiocytic sarcomas were reported in head and neck [2], thyroid [9], duodenum and small intestine [6,10], colon [5,11], urinary bladder [12], spleen [4,13,14], leptomeninges [7,15].

Our discussion highlights a rare case of extranodal primary histiocytic sarcoma. We report a unique histiocytic sarcoma in parotid gland not associated with regional and non-regional lymph nodes histiocytic sarcoma or lymphoma. To our knowledge, this is second case of primary histiocytic sarcoma of parotid gland in literature. The first one diagnosed by Akiba et al. [16]. Our case was challenging and we set various differential diagnoses based upon the histopathologic morphology and excluded by immunohistochemistry. These differential diagnoses include undifferentiated carcinoma, lymphoma, myoepithelial carcinoma, myeloid sarcoma and lastly histiocytic sarcoma. The negativity for pancytokeratin exclude the undifferentiated carcinoma, the negativity for LCA (CD45) exclude lymphoma, the negativity for P63 and S100 exclude myoepithelial carcinoma, while negativity for both CD117 and CD34 exclude myeloid sarcoma. So, the only positivity for vimentin, CD68, P53 and Ki-67 that about 40%, confirm the diagnosis of histiocytic sarcoma.

## Conclusion

Histiocytic sarcoma is a rare neoplasm. It must take in consideration in case with separate cells has abundant eosinophilic cytoplasm, with negative for epithelial lymphoid marker and positive for histiocytic marker.

## References

- Machado ES, de Miranda AC, Escopelli T, Caron R, Escopelli AC. Histiocytic sarcoma. *Rev Bras Hematol Hemoter.* 2011;33(2):155-7.
- Alexiev BA, Sailey CJ, McClure SA, Ord RA, Zhao XF, Papadimitriou JC. Primary histiocytic sarcoma arising in the head and neck with predominant spindle cell component. *Diagn Pathol.* 2007;2:7.
- Skala SL, Lucas DR, Dewar R. Histiocytic Sarcoma: Review, Discussion of Transformation from B-Cell Lymphoma, and Differential Diagnosis. *Arch Pathol Lab Med.* 2018;142(11):1322-9.
- Kobayashi S, Kimura F, Hama Y, Ogura K, Torikai H, Kobayashi A, et al. Histiocytic sarcoma of the spleen: case report of asymptomatic onset of thrombocytopenia and complex imaging features. *Int J Hematol.* 2008;87(1):83-7.
- Mitra S, Jhunjhunwala A, Mukherjee P. Extranodal histiocytic sarcoma mimicking colorectal lymphoma: Case report and review of literature. *Indian J Pathol Microbiol.* 2019;62(3):467-9.
- Akishima Y, Akasaka Y, Yih-Chang G, Ito K, Ishikawa Y, Lijun Z, et al. Histiocytic sarcoma with fatal duodenal ulcers. *Pathol Res Pract.* 2004;200(6):473-8.
- Zanelli M, Ragazzi M, Marchetti G, Bisagni A, Principi M, Fanni D, et al. Primary histiocytic sarcoma presenting as diffuse leptomeningeal disease: Case description and review of the literature. *Neuropathology.* 2017;37(6):517-25.
- Takahashi E, Nakamura S. Histiocytic sarcoma: an updated literature review based on the 2008 WHO classification. *J Clin Exp Hematop.*

- 2013;53(1):1-8.
9. Yu L, Yang SJ. A case of primary histiocytic sarcoma arising from thyroid gland. *Pathol Oncol Res.* 2010;16(1):127-32.
  10. Aviles-Salas A, Pena-Torres Mde L, Molina-Cruz A, Rivas-Vera S. Histiocytic sarcoma of the small intestine: Report of one case. *Rev Med Chil.* 2009;137(2):269-74.
  11. Chin NW, Gangi M, Fani K, De Soto-La Paix F, Papandreou C, Surapaneni RK, et al. Colonic histiocytic neoplasm mimicking malignant histiocytosis and presenting as intussusception. *Hum Pathol.* 1995;26(6):682-7.
  12. Fernandez-Acenero MJ, Perez Alonso P, Diaz Del Arco C. Histiocytic sarcoma with bladder involvement: Case report and literature review. *Rev Esp Patol.* 2018;51(1):23-6.
  13. Audouin J, Vercelli-Retta J, Le Tourneau A, Adida C, Camilleri-Broet S, Molina T, et al. Primary histiocytic sarcoma of the spleen associated with erythrophagocytic histiocytosis. *Pathol Res Pract.* 2003;199(2):107-12.
  14. Yamada S, Tasaki T, Satoh N, Nabeshima A, Kitada S, Noguchi H, et al. Primary splenic histiocytic sarcoma complicated with prolonged idiopathic thrombocytopenia and secondary bone marrow involvement: a unique surgical case presenting with splenomegaly but non-nodular lesions. *Diagn Pathol.* 2012;7:143.
  15. Patnaik A, Mishra SS, Senapati SB. A rare case of primary extranodal, extradural histiocytic sarcoma of the thoracic spine and review of literature. *Surg Neurol Int.* 2012;3:96.
  16. Akiba J, Harada H, Kawahara A, Arakawa F, Mihashi H, Mihashi R, et al. Histiocytic sarcoma of the parotid gland region. *Pathol Int.* 2011;61(6):373-6.