



Post Myocardial Injury Syndrome Following PCI

Gurunath Parale*

Department of Medicine, Parale Health Care and Research Center Private Limited, India

Abstract

Post-Cardiac Injury Syndrome (PCIS) is term for inflammatory pericardial conditions including postmyocardial infarction pericarditis (Dressler's syndrome), Postpericardiotomy Syndrome (PPS), and post-traumatic pericarditis.

A 76 yr old lady was admitted with ACS. Her ECG showed ST T changes in anterior leads. She was subjected for coronary angiogram which revealed a complex tight proximal LAD lesion with mild calcification and chronic total occlusion of RCA. Pericardial effusion immediate after complex PCI may raise suspicion of coronary rupture however fever, raised inflammatory markers will lead to diagnose this relatively benign totally treatable condition.

Keywords: Post-cardiac injury syndrome; Percutaneous coronary intervention; Postpericardiotomy syndrome

Introduction

Post-Cardiac Injury Syndrome (PCIS) is term for inflammatory pericardial conditions including postmyocardial infarction pericarditis (Dressler's syndrome), Postpericardiotomy Syndrome (PPS), and post-traumatic pericarditis [1,2]. PCIS after open-heart surgery is common with an incidence of 10% to 50% [3]. However, the incidence of PCIS after Percutaneous Coronary Intervention (PCI) is rare [4,5].

Case Presentation

A 76 yr old lady was admitted with ACS. Her ECG showed ST T changes in anterior leads. She was subjected for coronary angiogram which revealed a complex tight proximal LAD lesion with mild calcification and chronic total occlusion of RCA. She underwent successful angioplasty of both lesions with implantation of 2 drug eluting stents. In view of complexity of lesions the procedure was prolonged lasting over 3 hrs. 3 hours later she had fever and complained of left sided chest pain aggravating with postural change. Her ECG did not reveal any fresh changes. She was managed symptomatically initially and moved out of ICU couple of days later. However she was not comfortable having intermittent fever, dyspnoea and atypical chest pain. This prompted detail investigative work up. Her chest X-ray revealed cardiomegaly and left pleural effusion (Figure1). Ultrasound chest revealed moderate left pleural effusion and 2 D echocardiogram showed moderate pericardial effusion (Figure 2). She had leukocytosis with total count of 14200/cc and ESR was 140.

Diagnostic pleural fluid aspirate was exudative (proteins 4.6 gms%, ADA 14.4 IU/L, cytology showed 495 cells/cmm predominantly lymphocytes). The diagnosis of tuberculosis was briefly entertained and empiric anti tubercular treatment contemplated. However acuteness of history favoured against the diagnosis of tuberculosis. This led to search on the internet for possible etiology. There were stray case reports with near identical features with the diagnosis of post myocardial injury syndrome which is usually seen after myocardial infarction and cardiac surgery.

She was started on steroids to which she dramatically responded symptomatically and both pleural and pericardial fluid nearly completely resolved in 5 days (Figure 3 and 4).

Discussion

Post-Cardiac Injury Syndrome (PCIS) is term for inflammatory pericardial conditions including postmyocardial infarction pericarditis (Dressler's syndrome), Postpericardiotomy Syndrome (PPS), and post-traumatic pericarditis [1,2]. PCIS after open-heart surgery is common with an incidence of 10% to 50% [3]. However, the incidence of PCIS after Percutaneous Coronary Intervention (PCI) is rare [4,5]. The etiopathology of PMIS is not fully understood. The post-cardiac injury syndrome, including post-traumatic pericarditis, appears to start by the combination of damage to

OPEN ACCESS

*Correspondence:

Gurunath Parale, Department of Medicine, Parale Health Care and Research Center Private Limited, R/10, 952 B adarash Nagar, Solapur, Maharashtra, India, Tel: 912172313969;

E-mail: parale8@yahoo.com

Received Date: 15 Jul 2019

Accepted Date: 29 Jul 2019

Published Date: 01 Aug 2019

Citation:

Parale G. Post Myocardial Injury Syndrome Following PCI. *Ann Cardiol Cardiovasc Med.* 2019; 3(2): 1025.

Copyright © 2019 Gurunath Parale.

This is an open access article distributed under the Creative Commons Attribution License, which permits unrestricted use, distribution, and reproduction in any medium, provided the original work is properly cited.

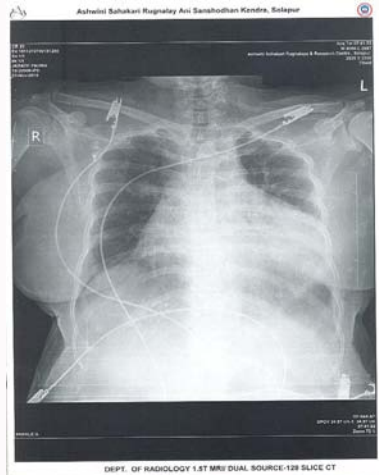


Figure 1: Chest X-ray showing cardiomegaly and left pleural effusion.

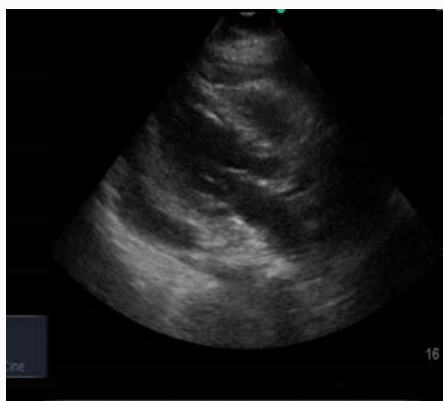

Figure 2: 2 D echocardiogram showing moderate pericardial effusion.

mesothelial pericardial cells and blood in the pericardial space [2,6]. The initial injury is thought to release cardiac antigens and stimulate an immune response. The immune complexes that are generated are then deposited in the pericardium, pleura, and lungs, eliciting an inflammatory response [6]. This theory finds support with following observations:

- The discrete latent period from cardiac injury to the clinical onset of post-cardiac injury syndrome.
- Coexistent pleural effusion and/or pulmonary infiltrates in some cases.
- Studies in patients undergoing cardiac surgery have found a statistically significant correlation between the postoperative to preoperative ratios of anti actin and antimyosin antibodies and the clinical occurrence of post-cardiac injury syndrome [7,8].
- The generally excellent response to anti-inflammatory therapy, and occasional relapses after steroid withdrawal [6].

Support for anti heart antibodies being an epiphenomenon comes from a prospective study of 20 surgical patients in whom serum was sampled for antiheart antibodies before and periodically after elective coronary artery bypass surgery [9]. Antiheart antibodies were absent in all patients on the day before surgery. Three patients developed post-pericardiotomy syndrome. All were seronegative at the time of diagnosis, but they became seropositive within the ensuing 14 days.

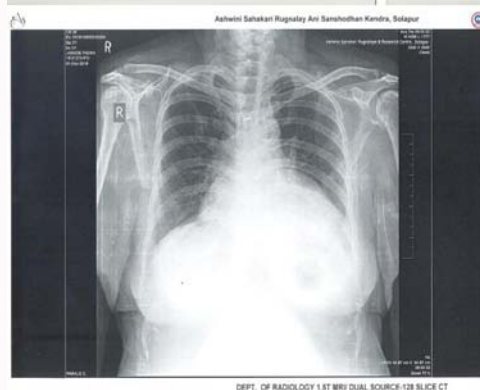

Figure 3: Chest X-ray showing regression of cardiomegaly and left pleural effusion.

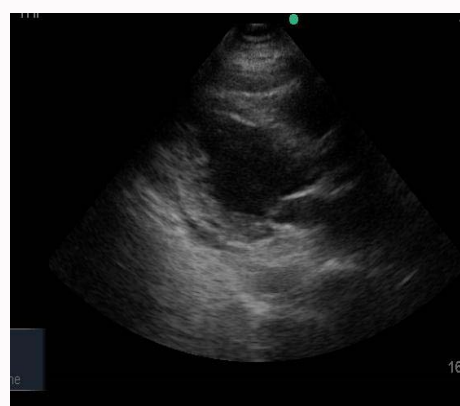

Figure 4: 2D echocardiogram showing regression of pericardial effusion.

The difference between the present case and classical PMIS after cardiac injury is early onset in the present case as early as 3 hrs as against couple of weeks in classical PMIS.

Another case of rapid onset (4 hours) of PCIS symptoms after PCI was reported by Setoyama et al. [5]. The authors explained that this rapid onset of PCIS was due to stimulation of the immune system by a recent myocardial injury prior to the PCI. Present patient had NSTEMI and chest pain for 2 weeks prior which could have caused cardiac injury triggering immune mechanism. The other possible explanation could be micro perforation of coronary as it was a complex procedure needing multiple wires including stiffer ones, micro catheter etc. However that does not explain such a rapid onset. Extensive internet search failed to find similar Indian case report.

Learning point: Pericardial effusion immediate after complex PCI may raise suspicion of coronary rupture however fevers, raised inflammatory markers will lead to diagnose this relatively benign totally treatable condition.

References

1. Adler Y, Charron P, Imazio M, Badano L, Baron-Esquivias G, Bogaert J, et al. 2015 ESC Guidelines for the diagnosis and management of pericardial diseases: The task force for the diagnosis and management of pericardial diseases of the european society of cardiology (ESC) endorsed by: The European Association for Cardio-Thoracic Surgery (EACTS). *Eur Heart J*. 2015;36(42):2921-64.
2. Imazio M, Hoit BD. Post-cardiac injury syndrome. An emerging cause of pericardial diseases. *Int J Cardiol*. 2013;168(2):648-52.

3. Miller RH, Horneffer PJ, Gardner TJ, Rykiel MF, Pearson TA. The epidemiology of the postpericardiotomy syndrome: A common complication of cardiac surgery. *Am Heart J.* 1988;116(5 Pt 1):1323-9.
4. Troughton RW, Asher CR, Klein AL. Pericarditis. *Lancet.* 2004;363(9410):717-27.
5. Setoyama T, Furukawa Y, Abe M, Nakagawa Y, Kita T, Kimura T. Acute pleuropericarditis after coronary stenting: a case report. *Circ J.* 2006;70(3):358-61.
6. Khan AH. The postcardiac injury syndromes. *Clin Cardiol.* 1992;15(2):67-72.
7. De Scheerder I, De Buyzere M, Robbrecht J, De Lange M, Delanghe J, Bogaert AM, et al. Postoperative immunological response against contractile proteins after coronary bypass surgery. *Br Heart J.* 1986;56(4):440-4.
8. Nomura Y, Yoshinaga M, Haraguchi T, Oku S, Noda T, Miyata K, et al. Relationship between the degree of injury at operation and the change in antimyosin antibody titer in the postpericardiotomy syndrome. *Pediatr Cardiol.* 1994;15(3):116-20.
9. Hoffman M, Fried M, Jabareen F, Vardinon N, Turner D, Burke M, et al. Anti-heart antibodies in postpericardiotomy syndrome: Cause or epiphenomenon? A prospective, longitudinal pilot study. *Autoimmunity.* 2002;35(4):241-5.