Annals of Cardiology and Cardiovascular Medicine

Case Report
Published: 14 Jun, 2018

Incessant Ectopic Atrial Tachycardia in the Pediatric Age: Clinical Presentation and Therapeutic Options

Abraham Benatar* and Wendy Dewals

Department of Pediatric Cardiology, University Hospital Brussels, Belgium

Abstract

Ectopic Atrial Tachycardia (EAT) is a comparatively common cause of incessant pediatric supra ventricular tachycardia and is more likely to lead to tachycardia-induced cardiomyopathy in this age group. Spontaneous resolution is frequent among the younger children, while EAT in older children is frequently refractory to Antiarrhythmic drugs and amenable to catheter ablation. We report two cases and review the therapeutic options.

Keywords: Cardiomyopathy; Ectoptic atrial tachycardia; Antiarrhythmic drug

Introduction

Reentrant Supraventricular Tachycardia (SVT) is the commonest tachyarrhythmias encountered in children where the basic substrate is the use of dual Atrioventricular (AV) node physiology or an accessory pathway [1]. This form of Paroxysmal SVT (PSVT) is initiated by the occurrence of critically timed Premature Atrial Contractions (PAC) or Premature Ventricular Contractions (PVC). Tachycardia episodes in these children tend to be short lived and easily terminated with adenosine. As critically timed PACs and PVCs do not occur so often, most children with PSVT have infrequent episodes and once tachycardia is terminated there may be a long interval before another episode is initiated [1].

Ectopic atrial tachycardia is a common cause of chronic supraventricular tachycardia in children (prevalence of 0.34% to 0.46% in young individuals) and is due to rapid discharges from an automatic atrial focus distinct from the sinus node [2-4]. The natural history of EAT includes possible progression to congestive heart failure and represents one of the few reversible etiologies of cardiomyopathy [1-5]. In contrast to reentrant SVT a critically timed extra systole is not required for tachycardia initiation and is consequently more often incessant. EAT rate is often slower than typical PSVT and is often at first misdiagnosed as sinus tachycardia. EAT and permanent junctional reciprocating tachycardia represents a smaller percentage of the encountered forms of SVT, yet they account for the large proportion of Tachycardia Induced Cardiomyopathy (TIC) encountered in children and infants [6]. Ectopic Atrial tachycardias are the most common cause of Tachycardiomyopathy (TCMP) in children [7].

We report two cases, an infant and an adolescent, to demonstrate the spectrum of clinical presentation encountered and review the treatment options.

Case Presentation

Case report 1

Conceived by *in vitro* fertilization this male neonate was born by caesarean section at 34 weeks of gestation, the first of non-identical twins. Birth weight was 1,900 grams. Neither ventilatory support nor oxygen therapy was required. From the outset, the parents had observed a higher heart rate on the neonatal unit monitor as compared to the twin brother, however dismissed by the neonatologists. At two months of age, he was hospitalised for 3 weeks in another hospital on account of a tachycardia noticed by the paediatrician on routine follow up examination. A tachycardia considered to be an ectopic atrial tachycardia was diagnosed though there were no signs of heart failure. Arrhythmia control was achieved by combination therapy of Digoxin and Amiodarone. Aged 15 months, on maintenance Antiarrhythmic therapy (weight 10 kilograms, he was hospitalised for a viral gastroenteritis. A break through recurrence of AET with no signs of heart failure was diagnosed (electrocardiogram Figure 1A and 1B). Initial therapeutic step was substitution of Digoxin with Sotalol and later the Amiodarone dose increased whilst monitoring the

OPEN ACCESS

****Correspondence:***
Abraham Benatar, Department of Pediatric Cardiology, University Hospital Brussels, Avenue du Laerbeek 101, 1090 Jette, Belgium, Tel: 3224775763; E-mail: Abraham.benatar@uzbrussel.be

Received Date: *04 Apr 2018*
Accepted Date*: 04 Jun 2018*
Published Date*: 14 Jun 2018*

Citation:
Benatar A, Dewals W. Incessant Ectopic Atrial Tachycardia in the Pediatric Age: Clinical Presentation and Therapeutic Options. Ann Cardiol Cardiovasc Med. 2018; 2(2): 1016.

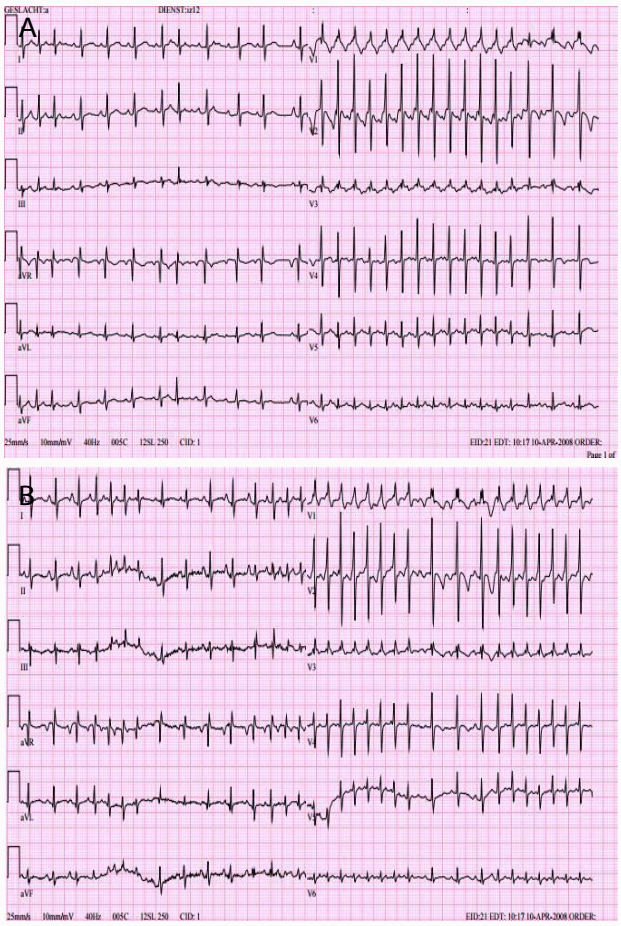

Figure 1A and 1B: Twelve lead electrocardiograms recorded from case 1. Note the small QRS complex tachycardia preceded by normal axis P wave. Note the 'warm up' rhythm acceleration characteristic of ectopic atrial tachycardia.

QTc interval. The tachycardia persisted despite adequate amiodarone loading. Amiodarone was discontinued on account of potential toxicity (QTc prolongation 480 milliseconds). The combination of Amiodarone and Sotalol has the potential to prolong QT interval and may be proarrhythmic (Both drugs block cardiac ionic channels, Sotalol is a beta blocker and inhibits efflux of K+ ions from cardiac cells). This drug combination was judiciously dosed whilst monitoring serum electrolytes, QTc interval, and continuous ECG monitoring. The different therapeutic options were discussed with the parents who strongly favoured the catheter ablation option. An electrophysiological study was undertaken utilizing a femoral venous approach. A single 5 French catheter localised the site of earliest activation (ectopic focus) in the superior right atrial appendage. A radio frequency ablation was performed (two applications of thirty seconds at 55°C). The tachycardia instantaneously ceased and sinus rhythm restored. No recurrences of atrial ectopic tachycardia have since been documented on routine ten year follow up and regular post procedural Holter monitoring.

Case report 2

A 13-year-oldgirl felt persistent rapid neck pulsations for 3 months before referral despite which she continued her regular circus acrobatic activities. Personal and family history was non-contributory. On physical examination weight (37 kg) and height (149 cm) were normal for age, normal peripheral perfusion, capillary filling time

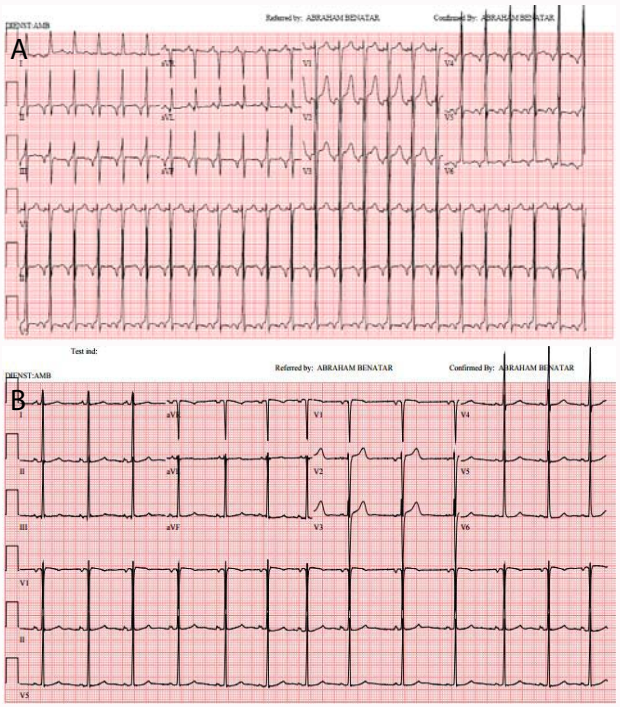

Figure 2: A: Twelve lead electrocardiograms recorded from case 2 on admission. Note the inverted P waves in leads II, III, avF and V2-V6. **B:** Twelve lead recorded from case 2 after conversion to sinus rhythm.

<3 seconds, no pitting edema. A tachycardia was present (heart rate 140/minute) blood pressure 110/70 mm Hg. Jugular venous pressure not elevated. No giant 'a' waves. No gallop rhythm or heart murmur. Chest auscultation was clear and no visceromegaly. A 12-lead Electrocardiogram (ECG) showed a regular and sustained small QRS complex tachycardia (mean heart rate: 140 beats/min; QRS duration of 80 milliseconds, normal QRS axis and tall inverted P waves in the inferior leads (P wave axis-80°) (Figure 2A). The heart was enlarged on chest X-ray (cardiothoracic ratio >60%), no upper lobe diversion. Two-dimensional and Doppler echocardiography showed a normal situs, levocardia and normal atrioventricular and ventriculo-arterial connections. Left Ventricular (LV) and left atrial dilatation was striking with severe global hypokinesis, mild mitral regurgitation (grade 1 over 4), and transmitral Doppler flow showed a pseudo normal pattern (decreased E deceleration). Left ventricular end diastolic dimension ≥ 6.9 cm/m^2, ejection fraction <30% and left atrial volume >48 mL/m^2. Tissue Doppler Imaging (TDI) annular e' velocity: Septal e' 3 cm/sec, lateral e' 4 cm/sec, average E/e' ratio 17. Peak pulmonary arterial pressure was estimated at 24 mm Hg from small tricuspid regurgitant jet. Features were in keeping with a severe TIC either secondary to AET or PJRT was considered in the differential diagnosis. Serum electrolytes, acid-base status, anion gap, inflammatory biomarkers (sedimentation rate, protein C) cardiac enzymes and troponin I, full blood count with white cell and differential count were all normal. Cultures for bacterial disease including Lyme and Rickettsia disease were performed. Viral workup, culture and serology was performed (serum, stool, nasopharyngeal aspirate) for RNA viruses: Coxsackie viruses A and B, echoviruses, polioviruses, influenza A and B, respiratory syncytial, mumps, measles rubella, hepatitis C; for DNA viruses: Adenoviruses, herpes viruses (cytomegalovirus, Epstein Barr virus, HHV 6), echovirus and parvovirus B19 and were all negative as was the metabolic workup. Genetic panel probes for dilated

cardiomyopathy failed to identify mutations. Cardiac magnetic resonance imaging confirmed the echocardiograph findings and no areas of sub epicardial late gadolinium enhancement typical of myocarditis were seen. Initial treatment with intravenous adenosine bolus had no effect on the tachycardia favouring EAT rather than PJRT. Treatment with Amiodarone, Dobutamine infusion, diuretics (Furosemide and Aldactone intravenously), fluid restriction, low salt diet was commenced. Over the ensuing days Lisinopril was added and later carvedilol per os. Riboflavin, thiamine, and Coenzyme Q 10 substitution were added. Within 56 hours of therapy conversion to sinus rhythm ensued (Figure 2B). It required one year of maintenance oral therapy with amiodarone, carvedilol and diuretics for left ventricular contractility and cardiac chamber size to normalize before gradual weaning from all therapy. Within three weeks AET or PJRT recurrence was diagnosed on routine ECG and confirmed on 24 Holter monitoring. Holter monitoring showed frequent episodes of tachycardia with 'warm up', occurring day and night and >80 percent of the time. An electrophysiological study was performed *via* a femoral venous approach. A regular atrial tachycardia with cycle length 440 milliseconds was induced with the earliest activation arising from the coronary sinus ostium. Radio frequency energy delivered to this area mounting up to 50 W instantaneously restored sinus rhythm. The ectopic atrial tachycardia has not recurred since (six months follow up).

Discussion and Conclusion

We report two cases of Ectopic Atrial Tachycardia (EAT) arising from the right atrial appendage in an infant and from the mouth of the coronary sinus in an adolescent girl. Infant EAT is distinct from adult EAT. In infants it is thought to arise from immature cardiac cells with enhanced automaticity. The incessant nature of the tachycardia may lead to ventricular dysfunction and cardiomyopathy in a substantial proportion of patients [4-7]. EAT is characterized by a persistent atrial tachycardia, a heart rate inappropriate for age [1,8,9], which varies from minute to minute and from hour to hour. There is typically a warm-up phase dependent on endogenous or exogenous catecholamine levels. The P wave configuration on ECG of the first beat of tachycardia is identical to that of the subsequent beats of the tachycardia (Figure 1). The PR interval is frequently prolonged when compared to the corresponding PR interval during sinus tachycardia at the same rate. Atrioventricular block may be seen during EAT. EAT P wave morphology is distinctly different from the sinus P morphology and spontaneous tachycardia termination is usually with a QRS complex and not with AV block. EATs originating from the right atrial appendage or close to the sinus node may be indistinguishable from sinus tachycardia, particularly if there is no sinus P wave for comparison. In such cases pointed P waves with slight prolongation of the PR interval ought to raise suspicion for EAT. Distinctive from reentrant SVT, vagal maneuvers or adenosine do not permanently terminate EAT. Adenosine administration may be a useful diagnostic maneuver. By blocking the AV node, it may isolate the P waves from the QRS and T waves and it may slow down the EAT automaticity thereby slowing the ectopic atrial rate and on occasion slow enough to allow the normal sinus rate to appear with its P wave morphology. This may be useful for comparison purposes and diagnosis.

Permanent Junctional Reciprocating Tachycardia (PJRT), another cause of incessant tachycardia, is a form of orthodromic reciprocating tachycardia that uses the AV node as the antegrade limb and a unique concealed atrioventricular accessory pathway as the retrograde limb. First described by Coumel in 1967, PJRT pathways differ from typical accessory pathways by having slow conduction, decremental properties, and sensitivity to adenosine and vagal maneuvers. Adenosine administration may terminate the tachycardia. Usually, prompt reinitiation of tachycardia occurs within seconds as the adenosine wears off [1]. Adenosine may aid differentiate EAT from PJRT.

Older children with incessant EAT rarely complain of palpitations as their heart rate is persistently rapid and perceived as normal as in case report 2. The arrhythmia is usually discovered on routine checkup.

EAT patients who develop TCMP frequently present with symptoms of Heart Failure (HF) once dilated cardiomyopathy with ventricular dysfunction sets in, as in case 2. The mechanisms of TCMP include subclinical ischaemia, abnormalities in energy metabolism, redox stress in patients who previously had TI [10,11]. After 3 months of successful treatment of tachycardia whether by rhythm or rate control, nearly complete recovery of symptoms and LV contractility is generally observed [12,13]. However, recent studies have not established such significant improvements in New York Heart Association class or objective measures of cardiac function [12,14]. In others, despite normalization of Ejection Fraction (EF), persistent LV remodelling has been demonstrated with elevated LV dimensions and volumes [15]. This provides strong evidence to continue heart failure therapy even once EF has recovered. Recurrent tachycardia in patients, who have previously had TCMP, may result in a faster and more severe onset of TCMP than the initial presentation. In a study of 24 patients with TCMP, 5 had recurrent tachycardia associated with a rapid drop in EF and symptoms of clinical heart failure occurring within 6 months [16], other small case series have reported similar finding [17,18]. This suggests that some structural cardiac abnormalities persist after an apparent recovery in function. Maintenance of a HF treatment regimen after normalization of EF, and continued monitoring of patients for recurrence of arrhythmia is a judicious strategy [19].

The clinical progression of EAT in infants is different from older children. Studies have confirmed that infants and children aged <3 years with EAT are more like to respond to pharmacological therapy and undergo spontaneous resolution. Primary medical therapy is consequently the favored therapeutic option in this group [1,13,20]. In older children spontaneous resolution of EAT is uncommon. In a multicentre study including 249 children, 74% of children with EAT diagnosed in the first year of life achieved spontaneous resolution. This may be an under estimate as some children undergo early ablation therapy thereby altering the natural history of spontaneous resolution [21]. A decade earlier Salerno et al. [20] compared outcomes of 22 infants with 46 older children and found that EAT in infants was more likely to respond to Antiarrhythmic therapy and more likely to resolve spontaneously. Antiarrhythmic drug therapy was successful in 91% of the younger children yet only 37% of older children [20].

The goal of medical therapy is to reduce the overall arrhythmia burden and/or achieve rate control to limit symptoms and reverse TIC. Studies have established β-blockers and class 1c Antiarrhythmic medications to be the most beneficial for EAT management [21,22]. The data favors β-blockers as the best first line agents. A significant percentage of children will require second line drugs such as Flecainide, Propafenone (class 1c Antiarrhythmic agents)

or Amiodarone and Sotalol [1,21,22]. The major limitation of these studies is the lack of standard dosing or criteria for medication failure. Significantly, medication choices depend on physician preference and empirical trials [21]. In therefore mentioned study 22 different medication combinations were effective for EAT suppression [21]. EAT may be challenging to treat and may require multiple medication combinations, even though >70% of medically treated patients eventually achieve control [21]. Ongoing EAT after withdrawal of medication will require subsequent medical or catheter ablation therapy (RFA) as in case 2. Flecainide (a class Ic Antiarrhythmic) is reported to be particularly effective for infants with refractory EAT. In this subset of patients slowing or complete elimination of EAT (dose of 90 mg/m^2/day to 150 mg/m^2/day) is attained in many [23]. When mono-therapy fails combination therapy with Flecainide and Sotalol or Flecainide and Amiodarone may be safe and effective [24,25]. A sustained period of EAT control is important in preventing or reversing the functional changes associated with tachycardia-induced cardiomyopathy.

Digoxin alone does not suppress EAT [26], however, Digoxin loading can be accomplished quickly and safely to produce AV block and achieve ventricular rate control and increase contractility in patients presenting with TIC.

The choice of Amiodarone as Antiarrhythmic for case 2, with an underlying TCMP, was on account of its minimal negative inotropic effect.

The significant age difference in EAT pharmacological therapy response observed in infants when compared to older children suggests different underlying mechanism and substrates for EAT. Studied EAT mechanisms include the three putative mechanisms, automaticity [27-31], triggered activity, and micro re-entry. The atrial substrates in younger children are thought to be immature cardiac cells with abnormal automaticity which degenerate with time, alternatively a transient inflammatory process that subsequently heals. In older children the focus may be scarring or inflammation from myocarditis which does not regress and therefore exhibits poor response to medical treatment [32].

In older children spontaneous EAT resolution is uncommon, and RFA is useful for this group. It is unquestionably indicated for incessant tachycardia, tachycardia induced cardiomyopathy, or paroxysmal tachycardia failing to respond to medication. Successful primary ablation therapy is reported to be effective as definitive therapy in 80% of all EAT patients [21]. Experience with catheter ablation of EAT in younger children is limited. Initial studies of RFA in young or small children reported lower success and higher complication rates [27], other studies have found similar success and complication rates for catheter ablation of EAT in children aged <1.5 years and older children [33]. Electroanatomic mapping opposed to conventional mapping for catheter ablation improves outcomes in pediatric EAT. Toyohara et al. [8] reported a series of 35 pediatric EAT patients who had 100% acute success and 11% recurrence with RFA using the CARTO Navigation System (Biosense Webster Inc, Diamond Bar, CA). Three dimensional electroanatomic mapping has improved ablation success and recurrence rates compared to conventional mapping techniques [31]. Expectedly, this technique has reduced fluoroscopy time and improved catheter ablation of pediatric arrhythmias particularly with complex substrates [34,35]. Even so, many institutions do not routinely provide RFA for children aged <3 years or with weight <25 kg [1,13,21,30,36,37].

EAT anatomic locations differ when comparing infants with older children [8]. For infants under 3 years of age, the right atrial appendage is the source of tachycardia in 50% compared to only 13% for older children. In the young, EAT rarely originate from the crista terminalis. In the older children common anatomical locations include the crista terminalis, atrial appendages, and pulmonary veins [8].

In conclusion, EAT is responsible for a considerable portion of incessant tachycardias in children. Improved understanding of natural progression, mechanism of arrhythmia, appropriate Antiarrhythmic drug use and modern technologies has meant that the youngest of children can be successfully treated medically, or where ablation can be accomplished safely and effectively. Tachycardiomyopathy remains an important complication and EAT ought to be actively excluded in children presenting with heart failure.

Acknowledgment

We wish to thank our adult electro physiologists for their support and assistance in the management of these two reported cases.

References

1. Bonney WJ, Shah MJ. Incessant SVT in children: Ectopic atrial tachycardia and permanent junctional reciprocating tachycardia. Progress in Pediatric Cardiol. 2013;35(1):33-40.
2. Gillette PC, Smith RT, Garson Jr A, Mullins CE, Gutgesell HP, Goh TH, et al. Chronic supraventricular tachycardia. Acurable cause of congestive cardiomyopathy. JAMA. 1985;253(3):391-2.
3. Fishberger SB, Colan SD, Saul JP, Mayer Jr JE, Walsh EP. Myocardial mechanics beforeand after ablation of chronic tachycardia. Pacing Clin Electrophysiol. 1996;19(1):42-9.
4. Houmsse M, Tyler J, Kalbfleisch S. Supraventricular tachycardia causing heart failure. Curr Opin Cardiol. 2011;26(3):261-9.
5. Salerno J, Seslar S, Chun T, Vafaeezadeh M, Parrish A, Permut L. Predictors of ECMO support in infants with tachycardia-induced cardiomyopathy. Pediatr Cardiol. 2011;32(6):754-8.
6. Walsh EP. Automatic atrial and junctional tachycardias. In: Walsh EP, Saul JP, Triedman JK, editors. Cardiac arrhythmias in children and young adults with congenital heart disease. Philadelphia: Lippincott Williams & Wilkins. 2001. p. 11-123.
7. Martin CA, Lambiase PD. Pathophysiology, diagnosis and treatment of tachycardiomyopathy. Heart. 2017;103(19):1543-52.
8. Toyohara K, Fukuhara H, Yoshimoto J, Ozaki N, Nakamura Y. Electrophysiologicstudies and radiofrequency catheter ablation of ectopic atrial tachycardia in children. Pediatr Cardiol. 2011;32(1):40-6.
9. Mehta AV, Sanchez GR, Sacks EJ, Casta A, Dunn JM, Donner RM. Ectopic automaticatrial tachycardia in children: Clinical characteristics, management and follow-up. J Am Coll Cardiol. 1988;11(2):379-85.
10. Shinbane JS, Wood MA, Jensen DN, Ellenbogen KA, Fitzpatrick AP, Scheinman MM. Tachycardia-induced cardiomyopathy: A review of animal models and clinical studies. J Am Coll Cardiol. 1997;29(4):709-15.
11. Bhushan M, Asirvatham SJ. The conundrum of ventricular arrhythmia and cardiomyopathy: Which abnormality came first? Curr Heart Fail Rep. 2009;6(1):7-13.
12. Jeong YH, Choi KJ, Song JM, Hwang ES, Park KM, Nam GB, et al. Diagnostic approach and treatment strategy in tachycardia-induced cardiomyopathy. Clin Cardiol. 2008;31(4):172-8.
13. Kay GN, Ellenbogen KA, Giudici M, Redfield MM, Jenkins LS, Mianulli M, et al. The Ablate and pace trial: A prospective study of catheter ablation

of the AV conduction system and permanent pacemaker implantation for treatment of atrial fibrillation. APT investigators. J Interv Card Electrophysiol. 1998;2(2):121-35.

14. Drago F, Silvetti MS, Mazza A, Anaclerio S, Pino AD, Grutter G, et al. Permanent junctional reciprocating tachycardiain infants and children: Effectiveness of medical and non-medical treatment. Ital Heart J. 2001;2(6):456-61.

15. Dandamudi G, Rampurwala AY, Mahenthiran J, Miller JM, Das MK. Persistent left ventricular dilatation in tachycardia-induced cardiomyopathy patients after appropriate treatment and normalization of ejection fraction. Heart Rhythm. 2008;5(8):1111-4.

16. Nerheim P, Birger-Botkin S, Piracha L, Olshansky B. Heart failure and sudden death in patients with tachycardia-induced cardiomyopathy and recurrent tachycardia. Circulation. 2004;110:247-52.

17. Watanabe H, Okamura K, Chinushi M, Furushima H, Tanabe Y, Kodama M, et al. Clinical characteristics, treatment, and outcome of tachycardia induced cardiomyopathy. Int Heart J. 2008;49(1):39-47.

18. Kieny JR, Sacrez A, Facello A, Arbogast R, Bareiss P, Roul G, et al. Increase in radionuclide left ventricular ejection fraction after cardio version of chronic atrial fibrillation in idiopathic dilated cardiomyopathy. Eur Heart J. 1992;13(9):1290-5.

19. Ponikowski P, Voors AA, Anker SD, Bueno H, Cleland JGF, Coats AJS, et al. 2016 ESC guidelines for the diagnosis and treatment of acute and chronic heart failure: The task force for the diagnosis and treatment of acute and chronic heart failure of the European society of cardiology (ESC) developed with the special contribution of the heart failure association (HFA) of the ESC. Eur Heart J. 2016;37:2129-200.

20. Salerno JC, Kertesz NJ, Friedman RA, Fenrich AL Jr. Clinical course of atrial ectopic tachycardia is age-dependent: Results and treatment in children <3 or >or =3 years of age. J Am Coll Cardiol. 2004;43(3):438-44.

21. Kang KT, Etheridge SP, Kantoch MJ, Tisma-Dupanovic S, Bradley DJ, Balaji S, et al. Current management of focal atrial tachycardia in children: A multicenter experience. Circ Arrhythm Electrophysiol. 2014;7(4):664-70.

22. Ge H, Li X, Liu H, Jiang H. Predictors of pharmacological therapy of ectopic atrial tachycardia in children. Pediatr Cardiol. 2017;38(2):289-95.

23. Perry JC, Mc Quinn RL, Smith Jr RT, Gothing C, Fredell P, Garson Jr A. Flecainide acetate for resistant arrhythmias in the young: Efficacy and pharmacokinetics. J Am Coll Cardiol. 1989;14(1):185-91.

24. Price JF, Kertesz NJ, Snyder CS, Friedman RA, Fenrich AL. Flecainide and sotalol: A new combination therapy for refractory supraventricular tachycardia in children <1 year of age. J Am Coll Cardiol. 2002;39(3):517-20.

25. Fenrich Jr AL, Perry JC, Friedman RA. Flecainide and amiodarone: Combined therapy for refractory tachyarrhythmias in infancy. J Am Coll Cardiol. 1995;25(5):1195-8.

26. Gillette PC, Garson Jr A. Electrophysiologic and pharmacologic characteristics of automatic ectopic atrial tachycardia. Circulation. 1977;56(4 Pt 1):571-5.

27. Walsh EP, Saul JP, Hulse JE, Rhodes LA, Hordof AJ, Mayer JE, et al. Transcatheter ablation of ectopic atrial tachycardia in young patients using radiofrequency current. Circulation. 1992;86(4):1138-46.

28. Kugler JD, Danford DA, Deal BJ, Gillette PC, Perry JC, Silka MJ, et al. Radiofrequency catheter ablation for tachyarrhythmias in children and adolescents. The pediatric electrophysiology society. N Engl J Med. 1994;330(21):1481-7.

29. Campbell RM, Strieper MJ, Frias PA, Danford DA, Kugler JD. Current status of radio frequency ablation for common pediatric supra ventricular tachycardias. J Pediatr. 2002;140(2):150-5.

30. Saul JP, Hulse JE, Papagiannis J, Van Praagh R, Walsh EP. Late enlargement of radiofrequency lesions in infant lambs. Implications for ablation procedures in small children. Circulation. 1994;90(1):492-9.

31. Cummings RM, Mahle WT, Strieper MJ, Campbell RM, Costello L, Balfour V, et al. Outcomes following electroanatomic mapping and ablation for the treatment of ectopic atrial tachycardia in the pediatric population. Pediatr Cardiol. 2008;29(2):393-7.

32. Klersy C, Chimienti M, Marangoni E, Comelli M, Salerno JA. Factors that predict spontaneous remission of ectopicatrial tachycardia. Eur Heart J. 1993;14:1654-6.

33. Blaufox AD, Felix GL, Saul JP. Pediatric catheter ablation registry. Radiofrequency catheter ablation in infants </= 18 months old: When is it done and how do they fare? Short-term data from the pediatric ablation registry. Circulation. 2001;104(23):2803-8.

34. Kwong W, Neilson AL, Chiu CC, Gross GJ, Hamilton RM, Soucie L. The effect of NavX on fluoroscopy times in pediatriccatheter ablation. J Interv Card Electrophysiol. 2012;33:123-6.

35. Smith G, Clark JM. Elimination of fluoroscopy use in a pediatric electrophysiology laboratory utilizing three-dimensional mapping. Pacing Clin Electrophysiol. 2007;30(4):510-8.

36. Kugler JD, Danford DA, Houston K, Felix G. Members of the pediatric EP society, radiofrequency catheter ablation registry. Radiofrequency catheterablation for paroxysmal supra ventricular tachycardia in children and adolescents without structural heart disease. Am J Cardiol. 1997;80(11):1438-43.

37. Wang Y, Li D, Zhang J, Han Z, Wang Y, Ren X, et al. Focal atrial tachycardia originating from the septal mitral annulus: Electrocardiographic and electrophysiological characteristics and radio frequency ablation. Europace. 2016;18(7):1061-8.