



Photodynamic Therapy Associated with Surgical Treatment of Severe Peri-Implantitis: 5-Year Follow-Up Clinical Report

Juliana Marotti^{1*}, Lauren Bohner², Pedro Tortamano² and Dieter Weingart³

¹Department of Prosthodontics and Biomaterials, University Hospital RWTH Aachen, Germany

²Department of Prosthodontics, University of São Paulo, Brazil

³Department of Oral and Maxillofacial Surgery, Katharinen Hospital, Germany

Abstract

Objective: This clinical report describes a case of severe peri-implantitis in the anterior region of the maxilla successfully managed with the association of photodynamic therapy and conventional surgical treatment.

Background Data: In implant dentistry, several treatment modalities have been presented to treat peri-implantitis and regenerate the bone, however, no protocol has yet been established and defined as effective. Adjunct approaches, such as photodynamic therapy (PDT), may be able to improve the success of conventional treatments.

Methods: A 59-year-old man was diagnosed with severe peri-implantitis in implants 11, 13, 21 and 23. After open debridement and implantoplasty, PDT was performed by applying the photosensitizer methylene blue over the implant surface for 5 min. Laser irradiation was performed with a GaAlAs low-level diode laser, with a wavelength of 660 nm, energy density 100 J/cm², and output power of 100 mW. The treatment was complemented with bone regeneration and free soft tissue graft.

Results: One year after the treatment, no bleeding-on-probing was observed and peri-implant pocket depths were reduced to 1 mm to 3 mm; this was maintained after 5 years of follow-up.

Conclusion: The treatment protocol, combined with support treatment, allowed the reduction of pathogenic bacteria and promoted the health of peri-implant tissues for a period of up to 5 years of follow-up.

Introduction

Peri-implantitis is an irreversible inflammatory disease that leads to marginal bone resorption around the implant and implant failure [1-4]. Although several treatment modalities have been presented, no protocol has been established, because it is not always possible to completely eliminate pathogenic microbial flora [5]. According to the severity of disease, non-surgical approaches may not be sufficient, and in this case, surgical therapies are required. Furthermore, adjunct approaches, such as laser treatment may be used in association with the conventional therapy to increase the success of treatment [6-9].

The antimicrobial photodynamic therapy (PDT) has emerged in the field of dentistry, and studies have shown its use and effectiveness for treating oral infections [9-20]. PDT involves the combination of a non-toxic photosensitizer and light that leads to the release of a highly-reactive oxygen agent with bactericidal effect. As this treatment modality has no effect on mammalian cells, it is considered harmless, an apparent advantage compared with antibiotics and chemical solutions [21]. However, in the case of peri-implantitis disease, it is not yet known whether photodynamic therapy is capable of improving the result of conventional therapy. Furthermore, clinical reports evaluating the effect of PDT in peri-implantitis have not shown a long term result, as the follow-up periods ranged from 4 to 12 months. Hence, the aim of this clinical report is to describe a case of severe peri-implantitis, in which the use of PDT associated with conventional surgical treatment showed successful results in a follow-up period of 5 years.

OPEN ACCESS

*Correspondence:

Juliana Marotti, Department of Prosthodontics and Biomaterials, Centre for Implantology, University Hospital RWTH Aachen, Pauwelsstrasse 30, 52074 Aachen, Germany, Tel: +49-241-80-88241; Fax: +49-241-80-82410;

E-mail: jmarotti@ukaachen.de

Received Date: 11 May 2017

Accepted Date: 20 Jun 2017

Published Date: 27 Jun 2017

Citation:

Marotti J, Bohner L, Tortamano P, Weingart D. Photodynamic Therapy Associated with Surgical Treatment of Severe Peri-Implantitis: 5-Year Follow-Up Clinical Report. *J Dent Oral Biol.* 2017; 2(8): 1059.

ISSN: 2475-5680

Copyright © 2017 Juliana Marotti. This is an open access article distributed under the Creative Commons Attribution License, which permits unrestricted use, distribution, and reproduction in any medium, provided the original work is properly cited.

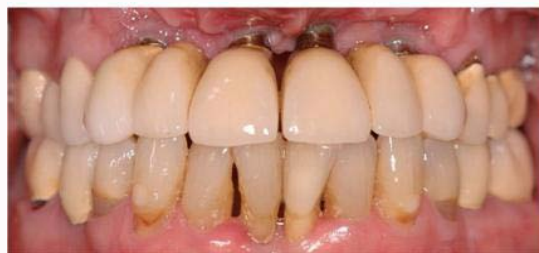

Figure 1: Initial intra-oral exam showing the absence of keratinized mucosa, and clinical signs of inflammation.

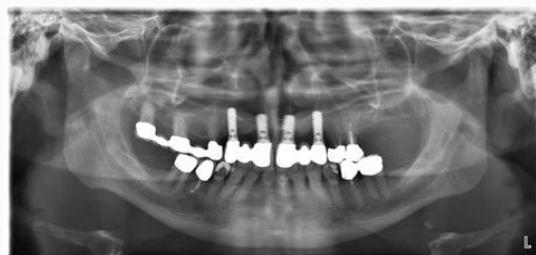


Figure 2: Pre-operative radiographic exam showing the bone loss around implants.

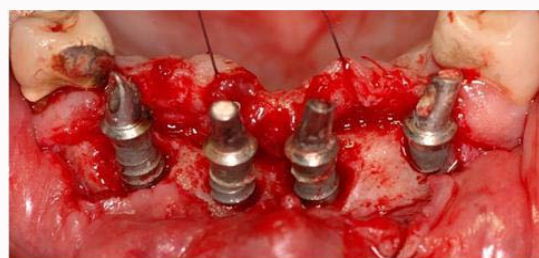


Figure 3: Flap elevation, showing the peri implant defects.

Case Presentation

The patient, a 59-year-old man was referred to the Maxillofacial Surgery Clinic at the Katharinen Hospital, Stuttgart, Germany, complaining of pain in the anterior region of the maxilla. The patient's medical history showed that he had been treated at the hospital 10 years before, when he presented a case of severe peri-implantitis that resulted in the loss of 4 implants located in the anterior maxilla. After regeneration of periodontal health, the bone defect was reconstructed with an autogenous bone block obtained from the iliac crest, and the implants were reinserted. The infection reappeared 5 years later, and a treatment with a combination of surgical debridement, irrigation with chlorhexidine and antibiotic therapy was performed. Subsequently, maintenance care was performed by a private dentist for the next 5 years.

During anamnesis, the patient revealed allergy to penicillin and clindamycin, absence of smoking habits, medical risk for dental surgeries or systemic diseases. Laboratory examinations were requested and no abnormalities, including glucose, cardiovascular and thyroid hormone abnormalities were shown.

Clinical and radiographic exams

Clinical examination showed normal oral mucosa and absence of oral lesions or dental infections, however, the presence of biofilm and a poor oral hygiene was observed. The patient presented four

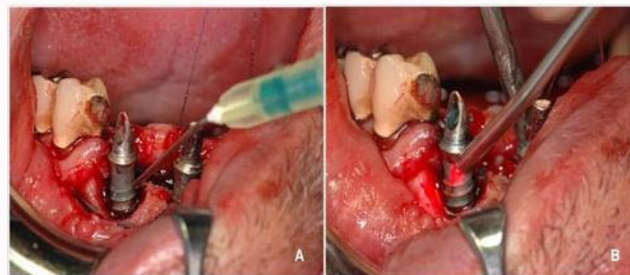

Figure 4: Photodynamic therapy. (A) Application of methylene blue 0.01% and (B) irradiation with diode laser.

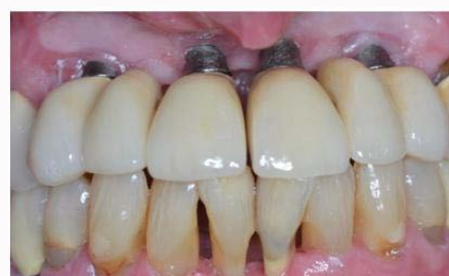

Figure 5: Intra-oral evaluation after 3 years of follow-up, showing periodontal health and absence of clinical signs of inflammation.

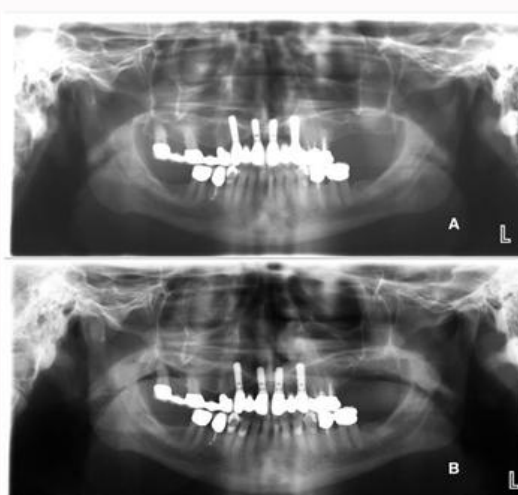


Figure 6: Radiographic exam after (A) 3 and (B) 5 years of follow-up, showing maintenance of bone level.

implants in the anterior maxilla (teeth in positions 11, 13, 21, 23) supporting an implant-supported dental prosthesis. Occlusion was balanced, without excessive overload of the implants.

Redness and swelling of peri-implant soft tissues associated with bleeding on probing (BOP), deep peri-implant pockets (DPP) >9 mm, and suppuration were observed. In the same region, the absence of keratinized mucosa was detected (Figure 1). Radiographic exam showed circumferential bone defects around implants, as shown in Figure 2.

Diagnosis and treatment planning

The association between clinical and radiographic exams confirmed the diagnostic of severe peri-implantitis in implants 11, 13, 21 and 23, including absence of keratinized gingiva. The treatment plan was defined in order to eliminate the pathogenic bacteria,

reduce the depth of peri-implant pockets and prevent the clinical signs of inflammation. Hence, a non-surgical treatment based on decontamination with mechanical debridement and irrigation with chlorhexidine was initially performed to reduce the inflammation. After a follow-up of 3 months, as the disease persisted, a surgical approach complemented with adjunct therapies was considered. According to a cause-related concept, a protocol involving open debridement followed by decontamination with laser therapy and chlorhexidine, associated with implantoplasty, bone regeneration and free soft tissue graft was planned.

Peri-implantitis treatment

The first stage of surgical therapy was performed as follows: local anesthesia (Xylocaine 2% with epinephrine 1:100,000) was applied and an incision was made in the crest of the ridge, followed by flap elevation to gain access to the peri-implant defects (Figure 3). Mechanical debridement and removal of granulation was performed by using curettes; and the implant surfaces were planed and smoothed with a diamond bur. Subsequently, the region was irrigated with Chlorhexidine 0.2% (Chlorhexamed, Hamburg, Germany) and sterile saline solution. After this, PDT was performed by applying the photosensitizer methylene blue 0.01% (m/V) (Chimiolum-Hypofarma, Brazil) over the entire implant surface and surrounding tissues for 5 min. Afterwards, the excess photosensitizer was removed and laser irradiation was performed with a GaAlAs low-level diode laser (Thera Lase, DMC, São Carlos, Brazil), at a wavelength of 660 nm, energy density 100 J/cm², output power of 100 mW, 28 s per point (Figure 4). Irradiation was performed in contact mode perpendicular over the entire exposed surface of the implants. After PDT treatment, the implants were irrigated with sterile saline solution.

The bone defect was filled with Emdogain (Straumann, Basel, Switzerland) in accordance with the manufacturer's instructions and the flap was sutured (Vicryl 4.0). After a period of maintenance care of 6 months, a reduction was observed in the clinical signs of inflammation, and a free gingival graft and vestibuloplasty were performed to increase the keratinized mucosa thickness. Maintenance care treatment was performed monthly and consisted of supra-gingival plaque control, irrigation with chlorhexidine 0.2% and professional prophylaxis with the aid of bristle brush and abrasive paste.

Results

One year after the surgical approach combined with PDT therapy, no BOP was observed and peri-implant pocket depths were reduced to 1 mm to 3 mm; this was maintained after 3 and 5 years of follow-up. The support treatment was maintained throughout a period of 5 years, with improvement in the bone level (Figure 5) and maintenance of periodontal health (Figure 6).

Discussion

The basis of peri-implantitis treatment must include a cause-related therapy and maintenance care of the patient, with the aim of reducing the bacterial load in the peri-implant pocket [22]. If complete elimination of pathogens is not achieved, the disease may recur [23]. In cases of severe peri-implantitis, conventional treatment may not be sufficient to access the contaminated surface, and the use of PDT appears to be an option to achieve more extensive eradication of microorganisms and improve the clinical results of treatment [24-27]. In the present report, the protocol with PDT was considered

successful in eliminating the pathogenic bacteria, taking into account that even after a long period of follow-up, there was no recurrence of the disease. Bombeccari et al. [8] evaluated the effect of PDT added to the conventional treatment: open debridement, curettage and irrigation with chlorhexidine. Photodynamic therapy reduced a higher percentage of bacterial biofilm compared with conventional treatment, although the results were not statistically significant. The major advantage in using PDT was considered the reduction of bleeding scores and inflammatory exudates. These results are in agreement with those found in the present case, because a reduction in PPDs and clinical signs of inflammation were achieved after debridement and PDT.

Moreover, risk factors must also be analyzed during the treatment planning, as several patient and non-patient related factors may increase the susceptibility to developing peri-implantitis. It has been suggested that the keratinized mucosa may play an important role in soft tissue hygiene and health conditions [28]. In the present report, the patient presented absence of keratinized mucosa, considered the main factor related to the evolution of peri-implantitis. Hence, a free tissue graft associated with a vestibuloplasty was essential to enable periodontal health and avoid recurrence of the infection. Areas lacking attached mucosa are susceptible to plaque accumulation [29], bleeding and recession [30]. Thus, an increase in keratinized mucosa may prevent bone loss and promote soft-tissue health.

Another key role for the maintenance of treatment was the post-operative care and oral hygiene education of patient [31]. Frisch recommends the development of supportive post-implant therapy with a recall every three months to prevent the occurrence of peri-implant diseases. In this report, an essential stage of the treatment was the monthly support therapy, and the patient's cooperation with the treatment.

Briefly, although clinical studies have been conducted to evaluate the benefits of conventional peri-implantitis treatment associated with PDT in patients followed-up for periods up to 12 months, the improvement in clinical outcomes by using this protocol when compared with conventional treatment alone is still controversial [32]. The main clinical significance of this report is to demonstrate a satisfactory result obtained with treatment in which PDT used in association with the conventional surgical therapy and support treatment allowed the maintenance of periodontal health for a period of 5 years.

Conclusion

A case of severe peri-implantitis was successfully managed with a treatment protocol involving the combination between conventional surgical treatment and antimicrobial photodynamic therapy for a period of up to 5 years of follow-up.

References

1. Smeets R, Henningsen A, Jung O, Heiland M, Hammächer C, Stein JM. Definition, etiology, prevention and treatment of peri-implantitis - A review. *Head Face Med*. 2014;10:34.
2. Kutlu HB, Genc T, Tozum TF. Treatment of refractory apical peri-implantitis: A case report. *J Oral Implantol*. 2016;42(1):104-9.
3. Aguirre-Zorzano LA, Estefanía-Fresco R, Telletxea O, Bravo M. Prevalence of peri-implant inflammatory disease in patients with a history of periodontal disease who receive supportive periodontal therapy. *Clin Oral Implants Res*. 2015;26(11):1338-44.

4. Singh P. Understanding peri-implantitis: a strategic review. *J Oral Implantol*. 2011;37(5):622-6.
5. Heitz-Mayfield LJ, Mombelli A. The therapy of peri-implantitis: a systematic review. *Int J Oral Maxillofac Implants*. 2014;29:325-45.
6. Renvert S, Polyzos I, Claffey N. Surgical therapy for the control of peri-implantitis. *Clin Oral Implants Res*. 2012;23:84-94.
7. Bassetti M, Schär D, Wicki B, Eick S, Ramseier CA, Arweiler NB, et al. Anti-infective therapy of peri-implantitis with adjunctive local drug delivery or photodynamic therapy: 12-month outcomes of a randomized controlled clinical trial. *Clin Oral Implants Res*. 2014;25(3):279-87.
8. Bombeccari GP, Guzzi G, Gualini F, Gualini S, Santoro F, Spadari F. Photodynamic therapy to treat periimplantitis. *Implant Dent*. 2013;22(6):631-8.
9. García-Morales JM, Tortamano-Neto P, Todescan FF, de Andrade Jr JC, Marotti J, Zezell DM. Stability of dental implants after irradiation with an 830-nm low-level laser: a double-blind randomized clinical study. *Lasers Med Sci*. 2012;27(4):703-11.
10. Romanos GE, Gupta B, Yunker M, Romanos EB, Malmstrom H. Lasers use in dental implantology. *Implant Dent*. 2013;22(3):282-8.
11. Trindade AC, De Figueiredo JA, Steier L, Weber JB. Photodynamic therapy in endodontics: a literature review. *Photomed Laser Surg*. 2015;33(3):175-82.
12. Marotti J, Tortamano P, Cai S, Ribeiro MS, Franco JE, de Campos TT. Decontamination of dental implant surfaces by means of photodynamic therapy. *Lasers Med Sci*. 2013;28(1):303-9.
13. Sperandio FF, Marotti J, Aranha AC, Eduardo CP. Photodynamic therapy for the treatment of recurrent herpes labialis: preliminary results. *Gen Dent*. 2009;57(4):415-9.
14. Moreira MSNA, de Freitas Archilla JR, Lascala CA, Ramalho KM, Gutknecht N, Marques MM. Post treatment apical periodontitis successfully treated with antimicrobial photodynamic therapy via sinus tract and laser phototherapy: Report of two cases. *Photomed Laser Surg*. 2015;33(10):524-8.
15. Leite DP, Paolillo FR, Parmesan TN, Fontana CR, Bagnato VS. Effects of photodynamic therapy with blue light and curcumin as mouth rinse for oral disinfection: A randomized controlled trial. *Photomed Laser Surg*. 2014;32(11):627-32.
16. Melo MA. Photodynamic antimicrobial chemotherapy as a strategy for dental caries: Building a more conservative therapy in restorative dentistry. *Photomed Laser Surg*. 2014;32(11):589-91.
17. Zand V, Milani AS, Amini M, Barhaghi MH, Lofti M, Rikhtegaran S, et al. Antimicrobial efficacy of photodynamic therapy and sodium hypochlorite on monoculture biofilms of *Enterococcus faecalis* at different stages of development. *Photomed Laser Surg*. 2014;32(5):245-51.
18. Marotti J, Sperandio FF, Fregnani ER, Aranha ACC, Eduardo CP. High-intensity laser and photodynamic therapy as a treatment for recurrent herpes labialis. *Photomed Laser Surg*. 2010;28(3):439-44.
19. Marotti J, Aranha AC, Eduardo Cde P, Ribeiro MS. Photodynamic therapy can be effective as a treatment for herpes simplex labialis. *Photomed Laser Surg*. 2009;27(2):357-63.
20. Marotti J, Tortamano P, Campos TT, Aranha ACC, Weingart D, Wolfart S, et al. Recent patents of lasers in implant dentistry. *Recent Patents Biomed Eng*. 2011;4(2):103-9.
21. Esposito M, Gruvosin MG, De Angelis N, Camurati A, Campailla M, Felice P. The adjunctive use of light-activated disinfection (LAD) with FotoSan is ineffective in the treatment of peri-implantitis: 1-year results from a multicentre pragmatic randomised controlled trial. *Eur J Oral Implantol*. 2013;6(2):109-19.
22. Frisch E, Ziebolz D, Vach K, Ratka-Krüger P. Supportive post-implant therapy: patient compliance rates and impacting factors: 3-year follow-up. *J Clin Periodontol*. 2014;41(10):1007-14.
23. Gianelli M, Formigli L, Lorenzini L, Bani D. Efficacy of combined photoablative-photodynamic diode laser therapy adjunctive to scaling and root planing in periodontitis: Randomized split-mouth trial with 4-year follow-up. *Photomed Laser Surg*. 2015;33(9):473-80.
24. Roncati M, Lucchese A, Carinci F. Non-surgical treatment of peri-implantitis with the adjunctive use of an 810-nm diode laser. *J Indian Soc Periodontol*. 2013;17(6):812-5.
25. Takasaki AA, Aoki A, Mizutani K, Schwarz F, Sculean A, Wang CY, et al. Application of antimicrobial photodynamic therapy in periodontal and peri-implant diseases. *Periodontol 2000*. 2009;51:109-40.
26. Sculean A, Aoki A, Romanos G, Schwarz F, Miron RJ, Cosgarea R. Is photodynamic therapy an effective treatment for periodontal and peri-implant infections? *Dent Clin N Am*. 2015;59(4):831-58.
27. Schär D, Ramseier C a, Eick S, Arweiler NB, Sculean A, Salvi GE. Anti-infective therapy of peri-implantitis with adjunctive local drug delivery or photodynamic therapy: six-month outcomes of a prospective randomized clinical trial. *Clin Oral Implants Res*. 2013;24(1):104-10.
28. Charalampakis G, Rabe P, Leonhardt A, Dahlén G. A follow-up study of peri-implantitis cases after treatment. *J Clin Periodontol*. 2011;38(9):864-71.
29. Adibrad M, Shahabuei M, Sahabi M. Significance of the width of keratinized mucosa on the health status of the supporting tissue around implants supporting overdentures. *J Oral Implantol*. 2009;35(5):232-7.
30. Schrott AR, Jimenez M, Hwang JW, Fiorellini J, Weber HP. Five-year evaluation of the influence of keratinized mucosa on peri-implant soft-tissue health and stability around implants supporting full-arch mandibular fixed prostheses. *Clin Oral Implants Res*. 2009;20(10):1170-7.
31. Serino G, Turri A, Lang NP. Maintenance therapy in patients following the surgical treatment of peri-implantitis: a 5-year follow-up study. *Clin Oral Implants Res*. 2015;26(8):950-6.
32. De Angelis N, Felice P, Grusovin MG, Camurati A, Esposito M. The effectiveness of adjunctive light - activated disinfection (LAD) in the treatment of periimplantitis: 4-month results from a multicentre pragmatic randomized controlled trial. *Eur J Oral Implantol*. 2012;5(4):321-31.