



Grey-Turner's Sign Associated with Psoas Muscle Hematoma

Stamatis Karakonstantis*, Ifigeneia Kassotaki and Charalampos Lydakis

2nd Department of Internal Medicine, General Hospital of Heraklion "Venizeleio-Pananeio", Greece

Clinical Image

A 75-year-old patient was hospitalized for a respiratory tract infection associated with severe hyponatremia (108 meq/l) and rhabdomyolysis (CPK up to 12741 IU/l). Due to a new-onset atrial fibrillation the patient was started on enoxaparin 6000 units twice daily. Despite significant improvement of the patient's condition, on the fifth day of hospital stay the hematocrit dropped to 27.5% from 39%. The patient reported stools of normal color, and the digital rectal examination was normal. No epistaxis was reported. Serum bilirubin was normal (0.88 mg/dl). LDH was slightly elevated =478. On physical examination, bruising of the right flank was noted (Figure 1). An abdominal CT was performed, revealing a large psoas hematoma (Figure 2). Enoxaparin was discontinued. The patient was managed conservatively with blood transfusions as needed. The patient was discharged 4 days later. Although typically associated with hemorrhagic pancreatitis, Grey-Turner sign (bruising of the flanks) may be seen with any cause of retroperitoneal hemorrhage. Bruising of the right flank (Figure 1) as a result of a hematoma of the right psoas muscle as demonstrated by an abdominal computed tomography (Figure 2).

OPEN ACCESS

*Correspondence:

Stamatis Karakonstantis, 2nd
Department of Internal Medicine,
General Hospital of Heraklion
"Venizeleio-Pananeio", Heraklion,
Crete, Greece,
E-mail: stamkar2003@gmail.com

Received Date: 13 Jul 2018

Accepted Date: 18 Jul 2018

Published Date: 20 Jul 2018

Citation:

Karakonstantis S, Kassotaki I, Lydakis C. Grey-Turner's Sign Associated with Psoas Muscle Hematoma. *Int J Intern Emerg Med.* 2018; 1(1): 1009.

Copyright © 2018 Stamatis Karakonstantis. This is an open access article distributed under the Creative Commons Attribution License, which permits unrestricted use, distribution, and reproduction in any medium, provided the original work is properly cited.

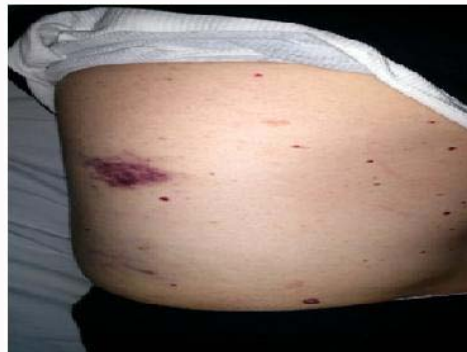

Figure 1:

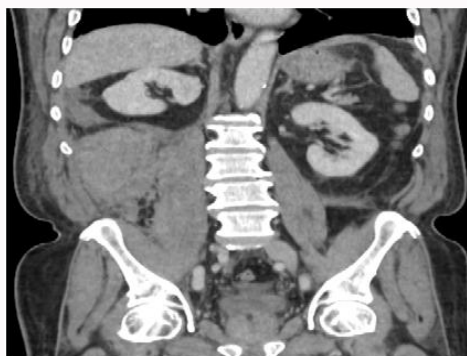


Figure 2: