



Fibrocalculous Pancreatic Diabetes (FCPD): Two Case Reports of FCPD Running in the Same Family. Can FCPD be Inherited?

Jaganmohan B^{1*}, Bairagi LJ¹, Rehman F¹, Silas MM¹, Jacinth M¹ and Ashok Jaiswal²

¹Department of Diabetology, Apollo Sugar Clinic, India

²Zydus Healthcare, India

Abstract

Background: Diabetes Mellitus (DM) is a global health burden leading to significant morbidity and mortality in both young as well as elderly individuals all over the world and there is a significant health care expenditure associated due to the complications caused by the disease. Although, Type-1 and Type-2 DM is the commonest forms of all diabetes, DM due to secondary causes has also been encountered in clinical settings. Fibrocalculous Pancreatic Diabetes (FCPD) is one of the unique and rare varieties of DM, secondary to chronic calcific pancreatitis. Chronic calculi resulting in inflammatory changes can affect both exocrine and endocrine part of pancreas which eventually results in FCPD. However the case studies available till date are mostly documenting individual case reports on FCPD without any evidence of genetic preponderance. But we would like to report two case studies of a middle aged man and his young adult daughter who are both affected by FCPD, probably indicating genetic role.

Case Presentation

Case 1: A 51 year old non-alcoholic South Indian Male presented with a history of chronic calcific pancreatitis 6 years ago. He later developed insulin dependent diabetes. Imaging of the abdomen, history and his clinical presentation corroborates with the criteria for diagnosing FCPD.

Case 2: A 20 year old non-alcoholic girl, who is the daughter of the first case, also had a clinical presentation suggestive of FCPD and imaging of the abdomen revealed calculi in the pancreas which helped clinched the diagnosis.

OPEN ACCESS

*Correspondence:

Jaganmohan B, Apollo Sugar Clinic,
Padmanabhanagar, Bangalore, 560070,
India, Tel: 9916756906;

E-mail: balajii81@gmail.com

Received Date: 12 Apr 2019

Accepted Date: 02 May 2019

Published Date: 08 May 2019

Citation:

Jaganmohan B, Bairagi LJ, Rehman F, Silas MM, Jacinth M, Jaiswal A. Fibrocalculous Pancreatic Diabetes (FCPD): Two Case Reports of FCPD Running in the Same Family. Can FCPD be Inherited?. *Ann Clin Diabetes Endocrinol.* 2019; 2(1): 1009.

Copyright © 2019 Jaganmohan B. This is an open access article distributed under the Creative Commons Attribution License, which permits unrestricted use, distribution, and reproduction in any medium, provided the original work is properly cited.

Abbreviations

FCPD: Fibrocalculous Pancreatic Diabetes; ERCP: Endoscopic Retrograde Cholangiopancreatography; SGLT2I: Sodium Glucose Co-Transporter 2 Inhibitor; NEFA: Non-Esterified Fatty Acid; BMI: Body Mass Index; USG: Ultra Sonography; CT: Computed Tomography; SPINK 1: Serine Protease Inhibitor Kojal Type 1; MPD: Main Pancreatic Duct

Introduction

Different terminologies have been put forward for FCPD by different authors, which include tropical calcific pancreatitis, tropical chronic pancreatitis, tropical pancreatic diabetes, nutritional pancreatitis, endemic pancreatic syndrome etc. But for the ease of global acceptance as well as global uniformity WHO had reported the term FCPD.

FCPD is one of the rarest varieties of diabetes, secondary to chronic non-alcoholic calcific pancreatitis. The lodged calculi in the ducts of pancreas attract inflammation which initially brings about destruction of acini of the exocrine pancreas [1]. As the disease progresses; there is widespread fibrosis which in the later stage of the disease begins to destroy pancreatic islets, thereby affecting insulin release resulting in secondary diabetes.

It is mostly seen in tropical, developing countries. In India FCPD is more common in South than in the North. One survey done in endemic areas of Kerala had shown a prevalence of FCPD of 125/100000 population [2]. Though the young candidates are more affected, some of the middle aged individuals are also known to have acquired the disease [3]. Lin Y et al. in Japan, had shown a prevalence of chronic pancreatitis to be 45.4/100000 population [4]. There is no recent data on

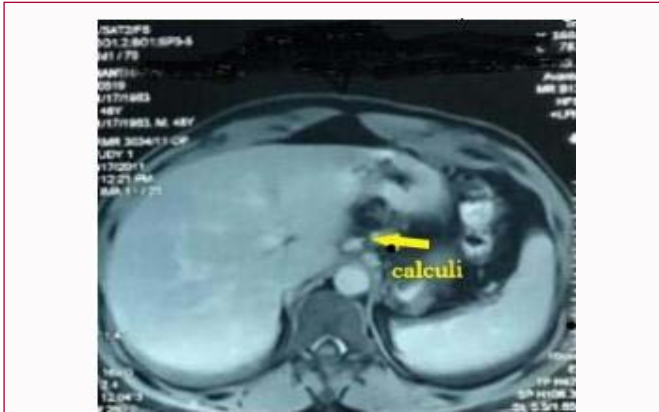

Figure 1: Case 1: CT Abdomen Picture Showing Stones in the Head of Pancreas.

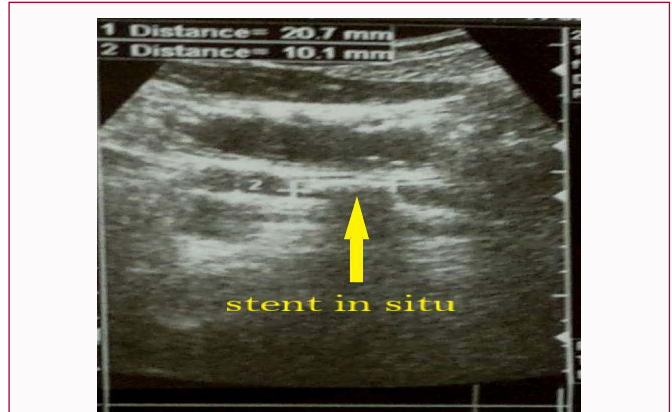

Figure 4: Case 1: Postoperative USG abdomen showing stent in situ after sphincteroplasty with stent in MPD (main pancreatic duct).

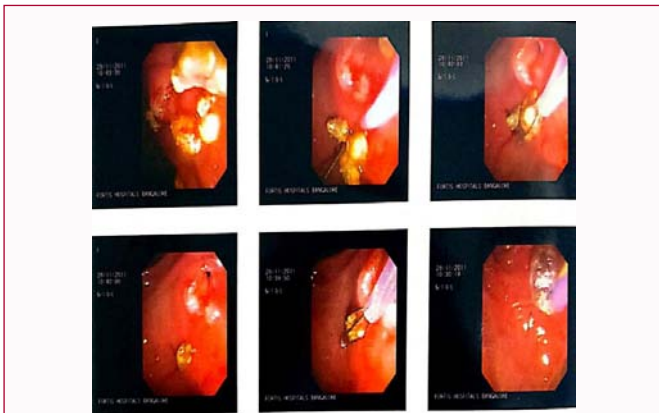


Figure 2: Case 1: Pancreatic Sphincterotomy with Stone Extraction/ Sphincteroplasty with Stenting Done.

childhood H/O recurrent abdominal pain with passage of oily stools (steatorrhea). He was diagnosed in the year 2011 as a case of chronic calcific pancreatitis with stones in the head of Pancreas, evidenced by Abdominal Ultrasonography, CT Abdomen and Endoscopic Retrograde Cholangiopancreatography (ERCP) reports. He was managed with pancreatic sphincterotomy with stone extraction followed by sphincteroplasty with stenting in MPD. He further underwent pancreatic stone extraction procedure again in the year 2012 for similar event of calcific pancreatitis.

We suspected him to be a case of FCPD and on further assessment, the Lab. Investigations revealed relatively low fasting C-Peptide level (1.49 ng/ml), high Amylase (106.8 U/L), and normal Lipase, LFT, Urea and S. Creatinine values. His previous medications namely glimepiride 4 mg BD, Vildagliptin 50 mg BD (contraindicated in Pancreatitis) and Metformin 500 mg BD were stopped. He was put on Gliclazide 60 mg OD along with insulin Glargine at bed time and insulin Glulisine TID (Basal-bolus), enzyme replacement therapy and Vitamin D Supplementation. He was also advised to have low calorie diet, physical exercise and to self-monitor his blood glucose.

He has been under our treatment since last 3 years and his glycaemic control has been relatively good (HbA1C 7% to 8%). During the course of these three years, owing to his corporate life style and frequent travel and hence omission of his afternoon rapid acting insulin dose, we also added Glipizide 5 mg in the afternoon and Canagliflozin 100 mg OD (started 1 & ½ years ago).

His recent Lab. Investigation reports revealed FBS 108 mg/dl, PPBS 128 mg/dl, HbA1c 7.4, T. Cholesterol 185 mg/dl, Triglyceride 190 mg/dl, D 100 mg/dl, S. creatinine 1.1 mg/dl.

Case 2

A 20 year old lean (BMI 20.2 Kg/m²) non-alcoholic girl, daughter

prevalence of FCPD available. Balaji who studied a population of 28,507 in Kerala, found that 1 in 1020 subjects had Chronic Calcific Pancreatitis (0.09%) [5]. Based on the work of Mohan V and Premalatha, who maintained a ‘Pancreatitis Registry’ in their centres, it is seen that out of 484 patients of chronic pancreatitis, 393 were eventually diagnosed as FCPD and Pre FCPD (81.2%) [1].

Case Presentation

Case 1

A 51 year old non-alcoholic South Indian Male with a diabetes duration of 8 years and diagnosed elsewhere to be a case of T2DM and treated with high doses of Glimepiride, Metformin and Vildagliptin, presented to our clinic on October 30, 2014 with an FBS of 121 mg/dl, PPBS of 242 mg/dl and HbA1c of 7.1%. He was lean with a BMI of 19.2 kg/m². On further probing he revealed that he had




Figure 3: Case Presentation 1: Stent is placed in MPD.

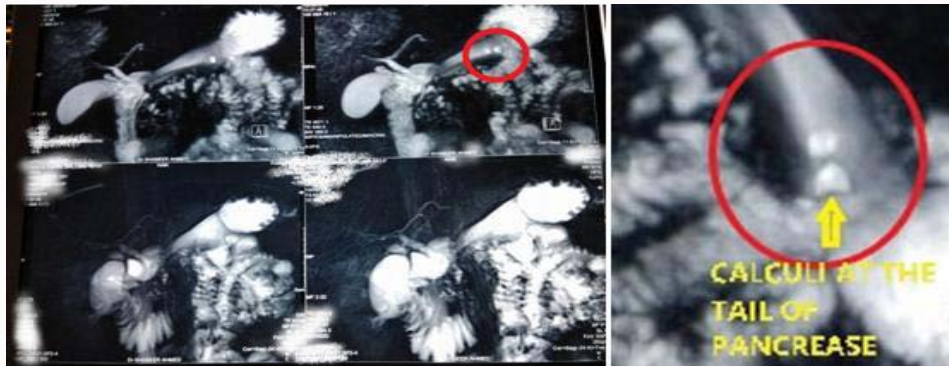

Figure 5: Case 2: ERCP image showing calculi in the tail of pancreas.

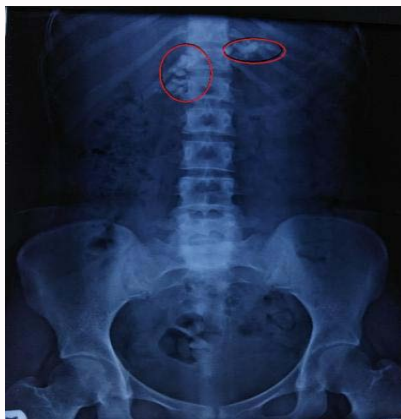

Figure 6: Case 2: X-ray Supine Abdomen Shows Calcification in T12 and L1 Vertebra S/O Pancreatic Calcification.

of the first case, also presented with recurrent abdominal pain since childhood similar to her father. She had complains of steatorrhea and occasional vomiting. She was then advised to do X-ray abdomen which revealed multiple calculi in the pancreas. Her laboratory reports were as follows:

FBS 114 mg/dl, PPBS 192 mg/dl, HbA1c 7.5%, S. Creatinine 0.8 mg/dl, Amylase 58 U/L, Lipase 37 U/L and negative ketonuria.

Based on her clinical presentation and imaging results, she was labelled as a case of FCPD and was put on low dose sulfonylurea (Gliclazide 30 mg once daily).

Discussion

Owing to the rare occurrence of FCPD, the etiopathogenesis, the course and possibility of genetic transmission of the disease is poorly understood. In this case report we have seen that a middle aged non-alcoholic man having H/O recurrent abdominal pain since childhood, with pancreatic calculi, steatorrhea and hyperglycemia was diagnosed as a case of FCPD and few years later his non-alcoholic young adult daughter having complains of epigastric pain, vomiting, steatorrhea and pancreatic calculi with hyperglycemia was also diagnosed as FCPD. The occurrence of the rarest and unique form of diabetes in first degree relatives clearly point towards the possibility of genetic preponderance of the disease nature.

Some studies have mentioned about Familial aggregation of FCPD amounting about 8% of total FCPD cases [6]. In some families' vertical transmissions was also reported like our cases and in some

horizontal transmission among siblings was also seen [7].

However recent studies have suggested an association of SPINK 1 gene and occurrence of FCPD [8-11]. Serine protease inhibitor acts as first line protection against early activation of trypsinogen within the pancreas. So its mutation may be one of the predisposing factors of chronic pancreatitis and FCPD particularly.

In case of severe intractable, recurrent pain due to FCPD, surgery is the only means of relief. In case 1, pancreatic sphincterotomy with stone extraction followed by sphincteroplasty with stenting in MPD was done in an effort to ameliorate his pain when it became severe. Similarly the patient in the case report of Ralapanawa et al. [3] had undergone annual ERCP and stenting procedure to get relieved of its pain.

In our case report, the father has fair Beta cell reserve as documented by his intermediate C-peptide level; hence he is managed on small doses of basal bolus insulin. This has been mentioned in other case reports where patients too have residual beta cell function and require small doses of insulin [3].

Case report of Ralapanawa et al. [3] has mentioned about ketosis resistance nature of the patient with FCPD. Similarly in our case study both father and the daughter had no ketonuria in their urine samples which could be attributed to the fair beta cell reserve [12] in their pancreas. There are some other causes behind ketosis resistance apart from partial beta cell reserve like decreased glucagon reserve [12], reduced supply of NEFA (source of ketogenesis) due to loss of subcutaneous fat, resistance to subcutaneous adipose tissue lipolysis by epinephrine, carnitine deficiency impairing transfer of NEFA across mitochondrial membrane [13-15].

In the case of the father, apart from basal-bolus insulin, gliclazide and glipzide are used for the management of diabetes. He has also been kept on SGLT2i, namely Canagliflozin for the last 6 months which is quite unconventional to the routine management of FCPD. We have not cited other case report where SGLT2i have been used for the management of FCPD.

Conclusion

This occurrence of Fibrocalculous pancreatic diabetes running in the same family opens up a new dimension of the disease nature, there by warranting further research and possibly genetic studies in FCPD.

References

1. Mohan V, Nagalotimath SJ, Yajnik CS, Tripathy BB. Fibrocalculous

- Pancreatic Diabetes. *Diabetes Metab Rev.* 1998;14(2):153-70.
2. Balaji LN, Tandon RK, Tandon BN, Banks PA. Prevalence and clinical features of Chronic Pancreatitis in Southern India. *Int J Pancreatol.* 1994;15(1):29-34.
 3. Ralapanawa DM, Jayawickreme KP, Ekanayake EM. Fibrocalculous pancreatic diabetes: a case report. *BMC Res Notes.* 2015;8:175.
 4. Lin Y, Tamakoshi A, Matsuno S, Takeda K, Hayakawa T, Kitagawa M, et al. Nationwide epidemiological survey of chronic pancreatitis in Japan. *J Gastroenterol.* 2000;35(2):136-41.
 5. Balaji LN. The problem of chronic calcific pancreatitis. New Delhi: PhD Thesis, All India Institute of Medical Sciences. 1988.
 6. Mohan V, Chari ST, Hitman GA, Suresh S, Madanagopalan N, Ramachandran A, et al. Familial aggregation in tropical fibrocalculous pancreatic diabetes. *Pancreas.* 1989;4:690-3.
 7. Barman KK, Premalatha G, Mohan V. Tropical chronic pancreatitis. *Postgrad Med J.* 2003;79(937):606-15.
 8. Hassan Z, Mohan V, Ali L, Allotey R, Barakat K, Deepa R, et al. SPINK1 is a major gene for susceptibility to fibrocalculous pancreatic diabetes in subjects from Southern Indian sub-continent. *Am J Hum Genet.* 2002;71(4):964-8.
 9. Chandak GR, Idris MM, Reddy DN, Bhaskar S, Sriram PV, Singh L. Mutations in the pancreatic secretory trypsin inhibitor gene [PSTI/SPINK1] rather than the cationic trypsinogen gene [PRSS1] are significantly associated with tropical calcific pancreatitis. *J Med Genet.* 2002;39(5):347-51.
 10. Schneider A, Suman A, Rossi L, Barmada MM, Beglinger C, Parvin S, et al. SPINK1/PSTI mutations are associated with tropical pancreatitis and type II diabetes mellitus in Bangladesh. *Gastroenterology.* 2002;123(4):1026-30.
 11. Bhatia E, Choudhuri G, Sikora SS, Landt O, Kage A, Becker M, et al. Tropical calcific pancreatitis: strong association with SPINK1 trypsin inhibitor mutation. *Gastroenterology.* 2002;123(4):1020-25.
 12. Mohan V, Snehalatha C, Ramachandran A, Jayashree R, Viswanatham M. Pancreatic beta cell function in tropical pancreatic diabetes. *Metabolism.* 1983;32(12):1091-2.
 13. Mohan V, Snehalatha C, Ramachandran A, Chari S, Madanagopalan N, Viswanathan M. Plasma glucagon responses in tropical fibrocalculous pancreatic diabetes. *Diabetes Res Clin Practices.* 1990;9(1):97-101.
 14. Yajnik CS, Shelgikar KM, Naik SS, Kanitkar SV, Orskov H, Alberti KG, et al. The ketosis resistance in fibrocalculous pancreatic diabetes: clinical observations and endocrine metabolic measurements during oral glucose tolerance test. *Diabetes Res Clin Practices.* 1992;15(2):149-56.
 15. Chari ST, Jayanthi V, Mohan V, Malathi S, Madanagopalan N, Viswanathan M. Radiological appearance of pancreatic calculi in tropical versus alcoholic chronic pancreatitis. *J Gastroenterol Hepatol.* 1992;7(1):42-4.