



Pericecal Hernia Presenting as Acute Appendicitis: A Case Report

Anupam Gupta¹, Michael Kucharik^{1*}, Arye Lavin¹ and Miguel Lopez-Viego²

¹Department of Medicine, Florida Atlantic University, USA

²Department of General & Vascular Surgery, Bethesda Hospital East, USA

Abstract

We would like to report an unusual case of a pericecal hernia in a 93 years old female. The patient did not report a history of previous abdominal surgery and presented with acute abdominal pain, obstipation, nausea, and vomiting. Diagnosis was made with computerized tomography and laparoscopy was performed, which was significant for loops of small bowel in the pericecal region in a defect of peritoneum. The small bowel loops were mobilized back in the intraperitoneal location and the defect was closed to prevent further herniation. Our case is an extremely rare presentation of a rare condition, as there have only been five reported cases of pericecal hernias that required immediate surgical intervention and outlined explicit details of the surgical procedure. This case highlights the importance of suspecting strangulated internal hernias in patients with signs and symptoms of acute appendicitis to prevent significant morbidity and mortality.

Introduction

Hernias can be broadly categorized as internal and external hernia. Internal hernia is the protrusion of visceral contents through a congenital or acquired opening within the peritoneal cavity, whereas external hernia occurs through an opening in the abdominal wall [1]. Internal hernias comprise less than 1% of all hernias, but constitute up to 5.8% of all cases of small bowel obstructions [2]. If left untreated, internal hernias are associated with a mortality rate that exceeds 50% [2]. Among the subsets of internal hernias, pericecal hernias comprise approximately 13% of all cases [2]. Early diagnosis of this rare condition can aid in laparoscopic management and prevent significant morbidity and mortality [3].

Case Presentation

We would like to report a 93 years old female with no previous abdominal surgery, presenting with acute pain in abdomen, obstipation, nausea and vomiting of 1-day history. Her past medical history was significant for hyperlipidemia and gastroesophageal reflux disease. She had no previous surgeries and her medication list included simvastatin and ranitidine. On arrival patient's vital signs showed a heart rate of 98 beats per minute, blood pressure 110/90 mm of Hg and on room air she had saturation of more than 95%, however patient continued to complain of pain in the right lower quadrant of the abdomen and nausea. Clinically, abdomen was soft, but distended with tenderness on palpation of right lower quadrant with sluggish bowel sounds. Her routine blood work was significant for an elevated white count to 12,000/ml with neutrophilia. Hemoglobin 12.9 g/dl, hematocrit of 30%, platelet count of 150000/ml and basic electrolyte profile showed sodium of 140 mEq/ml, potassium of 3.7 mEq/ml, Blood urea nitrogen 37 and creatinine of 1.1. A non-contrast Computed Tomography (CT) scan of the abdomen and pelvis was performed. This revealed small bowel loops in the right lower quadrant lateral to the ascending colon. The loop of bowel appeared distended and was associated with some mesenteric fat stranding (Figure 1 and 2). After fluid resuscitation and bowel rest, the patient was considered for surgery as she continued to complain of increasing pain in right lower quadrant, which was not relieved with ketorolac. Patient was taken to the operating room and a diagnostic laparoscopy was performed using a 10/mm video port at the umbilicus. An additional midline 5 mm port was placed in the suprapubic region. Loops of small bowel were visualized in the pericecal region in a defect of peritoneum. The small bowel loops were mobilized back in the intraperitoneal location using a grasper and blunt dissection. The peritoneal defect was identified (Figure 3) and this natural orifice was subsequently overlapped with the surrounding peritoneum and closed with vicryl trackers to prevent further herniation. The bowel loop appeared congested and edematous, however were viable in nature so no resection

OPEN ACCESS

*Correspondence:

Michael Kucharik, Department of
Medicine, Florida Atlantic University,
USA,

E-mail: mkucharik2016@health.fau.edu

Received Date: 02 Dec 2019

Accepted Date: 20 Jan 2020

Published Date: 27 Jan 2020

Citation:

Gupta A, Kucharik M, Lavin A, Lopez-Viego M. Pericecal Hernia Presenting as Acute Appendicitis: A Case Report. *Ann Surg Case Rep.* 2020; 3(1): 1024.

Copyright © 2020 Michael Kucharik.

This is an open access article distributed under the Creative Commons Attribution License, which permits unrestricted use, distribution, and reproduction in any medium, provided the original work is properly cited.

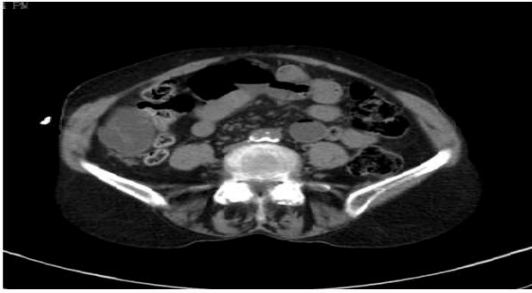

Figure 1: Dilated small bowel loop lateral to cecum in the right paracolic gutter.

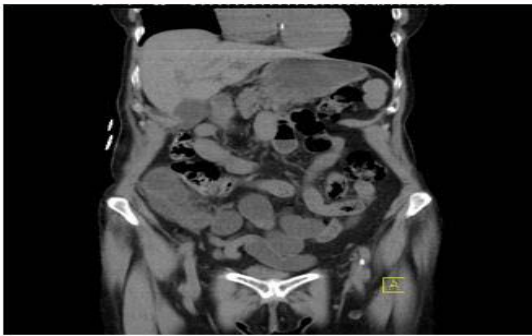

Figure 2: Small bowel loop lateral to cecum.

anastomosis was performed. Patient withstood the procedure well and had a normal postoperative course. The patient was tolerating diet on postoperative day 1 and subsequently discharged on postoperative day 2.

Discussion

Hernias can be internal or external. Internal hernias constitute less than 1% of hernias occur through abnormal opening through the peritoneum or the mesentery [2]. Internal hernias can result from natural orifices or those made from procedures, such as Roux-en-Y gastric bypass [2]. Most common natural orifices include paraduodenal (53%), pericecal (13%), foramen of Winslow (8%), transmesenteric (8%), and intersigmoid (6%) [3,4]. Pericecal hernias are uncommon and mimic acute appendicitis in initial stages with pain and nausea followed by small bowel obstruction in the later stages [2]. The pericecal recesses are formed around the fifth month of gestation when the bowel loops return to the abdominal cavity [3]. There are four defined pericecal recesses: superior ileocecal, inferior ileocecal, retrocecal, and paracolic sulci [2]. When obstructed, patients complain of obstipation and right lower quadrant tenderness [4]. Radiograph imaging, specifically non-contrast CT scans, reveals loops of bowel, usually posterolateral to the cecum and right paracolic gutter. Also present can be signs of small bowel obstruction, such as air fluid levels, dilated loops of small bowel, and a transition point [3]. Early diagnosis and use of laparoscopy can help reduce the hernia and minimize morbidity [3]. A literature review on PubMed including the terms “pericecal hernia” and “pericecal hernia” yielded 27 and 24 matches, respectively. Articles that did not provide surgical details or utilize urgent surgical intervention were excluded from our literature review. Among the remaining 13 cases, the demographics included a mean age of 69 years, with 8 female and 5 male patients. Only three patients had prior surgical history, two of which underwent appendectomy near the pericecal region. Eight of these patients

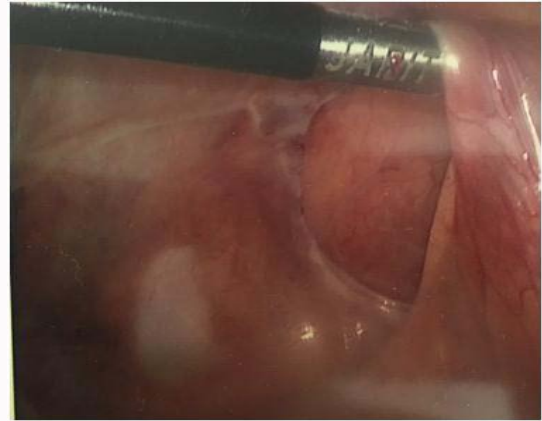


Figure 3: Intraoperative picture showing the pericecal defect which was subsequently closed with vicryl trackers.

were managed by exploratory laparotomy, while five were managed laparoscopically. One manuscript reported three cases of pericecal hernia in a series of 533 cases of small bowel obstruction [5-16].

Conclusion

A Pericecal hernia is an unusual occurrence and is seen to occur in more frequently in older women. The clinical signs and symptoms often mimic acute appendicitis and there is delay in diagnosis. Clinical findings are often insufficient to make a diagnosis. Early diagnosis can be made with imaging like computed tomography. In patients early laparoscopy can help confirm diagnosis and reduce the internal hernia. The internal hernia orifice should be closed or enlarged to prevent further herniation. Delay in diagnosis can result in hernia getting complicated needing an exploratory laparotomy and prolonged morbidity.

Drawbacks

In our literature search we had to eliminate data from many radiological journals which mention more number of cases however fail to provide surgical information. There were a few journals which didn't provide complete information and so the impression this paper gives that pericecal hernia manifests at an older age.

References

- Lassandro F, Iasiello F, Pizza NL, Valente T, Mangoni di Santo Stefano ML, Grassi R, et al. Abdominal hernias: Radiological features. *World J Gastrointest Endosc.* 2011;3(6):110-17.
- Martin LC, Merkle EM, Thompson WM. Review of Internal Hernias: Radiographic and Clinical Findings. *Am J Roentgenol.* 2006;186(3):703-17.
- Ogami T, Honjo H, Kusanagi H. Pericecal Hernia Manifesting as a Small Bowel Obstruction Successfully Treated with Laparoscopic Surgery. *J Surg Case Rep.* 2016;2016(3).
- Osadchy A, Keidar A, Zissin R. Small bowel obstruction due to a paracecal hernia: computerized tomography diagnosis. *Emerg Radiol.* 2005;11(4):239-41.
- Sciaccia P, Bertolini R, Borrello M, Bargigli R, Marcarone Palmieri R. [Intestinal obstruction caused by paracecal hernia. 3 case reports and review of the literature]. *Minerva Chir.* 1997;52(7-8):983-8.
- Hirokawa T, Hayakawa T, Tanaka M, Okada Y, Sawai H, Takeyama H, et al. Laparoscopic Surgery for Diagnosis and Treatment of Bowel Obstruction: Case Report of Paracecal Hernia. *Med Sci Monit.* 2007;13(7):79-82.

7. Jang EJ, Cho SH, Kim DD. A Case of Small Bowel Obstruction due to a Paracecal. *Hernia J Korean Soc Coloproctol.* 2011;27(1):41-3.
8. Kabashima A, Ueda N, Yonemura Y, Mashino K, Fujii K, Ikeda T, et al. Laparoscopic Surgery for the Diagnosis and Treatment of a Paracecal Hernia Repair: Report of a Case. *Surg Today.* 2010;40(4):373-5.
9. Kleyman S, Ashraf S, Daniel S, Ananthan D, Sanni A, Khan F. Pericecal hernia: A rare form of internal hernias. *J Surg Case Rep.* 2013;2013(2).
10. Lu HC, Wang J, Tsang YM, Tseng HS, Li YW. Pericecal Hernia: A Report of Two Cases and Survey of the Literature. *Clin Radiol.* 2002;57(9):855-8.
11. Molto Aguado M, Gonzalez Valverde FM, Barreras Mateos JA, Vázquez Rojas JL. Small Intestinal Strangulation due to a Primary Internal Paracecal Hernia. *Hernia.* 2007;11(5):457-8.
12. Nishi T, Tanaka Y, Kure T. A Case of Pericecal Hernia with a Hernial Orifice Located on the Lateral Side of the Cecum. *Tokai J Exp Clin Med.* 2011;36(3):71-4.
13. Omori H, Asahi H, Inoue Y, Irinoda T, Saito K. Laparoscopic Paracecal Hernia Repair. *J Laparoendosc Adv Surg Tech A.* 2003;13(1):55-7.
14. Kumar S, Dikshit P, Bhaduri S, Sattavan S. Gangrenous Appendicitis: A Rare Presentation of Pericecal Hernia; Case Report and Review of the Literature. *Bull Emerg Trauma.* 2015;3(4):144-7.
15. Sasaki K, Kawasaki H, Abe H, Nagai H, Yoshimi F. Retrocecal Hernia Successfully Treated with Laparoscopic Surgery: A Case Report and Literature Review of 15 Cases in Japan. *Int J Surg Case Rep.* 2016;18:45-7.
16. Shibuya H, Ishihara S, Akahane T, Shimada R, Horiuchi A, Aoyagi Y, et al. A Case of Paracecal Hernia. *Int Surg.* 2010;95(3):277-80.