



## Penetrating Neck Injury with Aspiration of the Missile: A Case Report

Azeem Mohiyuddin SM\*, Shreeharsha Maruvala, Kouser Mohammadi, Induvarsha G, Harshitha N and Sumanth KR

Department of ENT & Head and Neck Surgery, Sri Devaraj Urs Medical College, India

### Abstract

Small high velocity flying objects often cause penetrating injuries. Such injuries to neck are an emergency and may present with vascular injuries, bleeding or edema in the airway and damage to laryngeal or tracheal cartilages. We are reporting a case of missile (high velocity metallic flying object) injury to neck, where the thyroid cartilage was penetrated and patient had aspirated the missile into right bronchus. The patient had hoarseness of voice due to submucosal hematoma in larynx and blood stained spittoons. The foreign body in right bronchus at the opening of middle lobe medial segment was removed by rigid bronchoscopy and the penetrating injury in the neck was explored. Hemostasis secured and the wound was sutured after povidone iodine irrigation. The patient had uneventful recovery and the hoarseness of voice improved. This case report highlights that penetrating neck injuries by small missiles can be misleading as the entry wound is often small. A nonmetallic foreign body can be missed, leading to complications later. In these patients injury to blood vessels and airway framework should always be ruled out. A missing foreign body in such cases must be looked for in the airway. This case was unusual as the metallic foreign body had penetrated the larynx and was aspirated into the right bronchus without any history of choking at the time of injury.

### Introduction

Missile injuries resulting in penetrating wounds in the neck are encountered occasionally among adult male patients, particularly workers in metal industries, construction workers and soldiers in combat. However a penetrating neck injury presenting with aspiration of the missile is rare and only a few cases has been reported in literature [1-4].

We are reporting an interesting case of penetrating neck injury in an onlooker close to a blacksmith which resulted in penetration through upper part of thyroid cartilage and aspiration of the metallic missile into the right main bronchus at the middle lobe medial segmental opening. The patient was managed by rigid bronchoscopy and foreign body removal along with neck exploration.

We are reporting this case to highlight that penetrating neck injuries should always arouse suspicion of vascular injury, aspiration or airway compromise.

### Case Report

A 32 years old, well-built man presented with history of injury to the front aspect of neck by a high velocity metallic object while standing close to a blacksmith at work. This was followed by bleeding from the site of injury, hemoptysis and change in voice. He had no breathlessness or choking. He gave no past history of neck injury or other comorbidities and was not on any medication.

On examination the patient was clinically stable and had no respiratory distress. However the voice was hoarse but intelligible. He had cough with blood tinged spittoons. There was a 6 mm laceration just below the thyroid notch. The patient had minimal surgical emphysema in the neck and there was bleeding through the entry wound whenever the patient coughed. Auscultation of the chest was normal.

X-ray of the neck and chest revealed a radio opaque foreign body in the right main bronchus near the medial aspect of middle lobe (Figure 1). Rest of the lung fields and airway were clear. The patient was taken up for rigid bronchoscopy and neck exploration under general anesthesia which was induced with Propofol, Fentanyl and Succinyl choline, and a 6 mm internal diameter Storz rigid ventilating bronchoscope was introduced trans-orally into larynx. There was a hematoma in the

### OPEN ACCESS

#### \*Correspondence:

S M Azeem Mohiyuddin, Department of ENT & Head and Neck Surgery, Sri Devaraj Urs Medical College, Tamaka, Kolar, 563101, India, Tel: 9845373279; E-mail: azeem\_hn@yahoo.co.in

Received Date: 01 Feb 2018

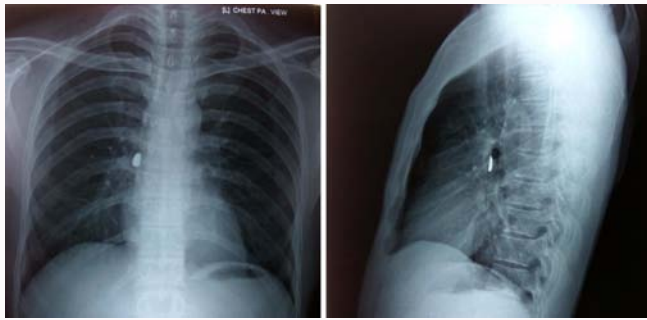
Accepted Date: 16 Apr 2018

Published Date: 23 Apr 2018

#### Citation:

Azeem Mohiyuddin SM, Maruvala S, Mohammadi K, Induvarsha G, Harshitha N, Sumanth KR. Penetrating Neck Injury with Aspiration of the Missile: A Case Report. *Ann Clin Otolaryngol*. 2018; 3(1): 1031.

Copyright © 2018 S M Azeem Mohiyuddin. This is an open access article distributed under the Creative Commons Attribution License, which permits unrestricted use, distribution, and reproduction in any medium, provided the original work is properly cited.



**Figure 1:** Chest Xray (PA and Lateral view) showing radioopaque foreign body in right bronchus at the level of middle lobe.

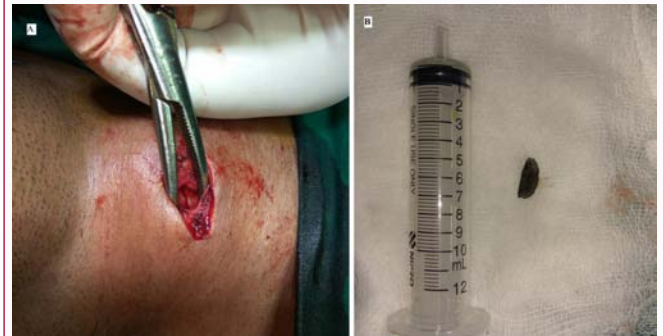right ventricular fold. It was not obstructing the airway and no active bleeding was seen in the airway. The bronchoscope was advanced into right main bronchus and long 0° telescope was passed through it to locate the foreign body and to rule out clots or trauma in the lower airway. General anesthesia was maintained by bolus Propofol and Atracurium injection and patient was ventilated through the lumen of the ventilating bronchoscope. A metallic foreign body with sharp edges measuring 1.5 cm×0.7 cm (Figure 2) was seen near the opening of middle lobe medial segment bronchus in the right main bronchus. Blood clots around the foreign body were sucked out. There was no damage to the trachea and bronchi. The foreign body was removed uneventfully.

The penetrating injury of the neck was explored with a horizontal incision of 3 cm. The foreign body had lacerated the anterior jugular vein and penetrated strap muscles and right ala of thyroid cartilage 1 cm below its upper border (Figure 2). The lacerated anterior jugular vein was ligated. There was no distortion of laryngeal skeleton. The wound was irrigated with povidone iodine and soft tissues over thyroid cartilage laceration and the skin were sutured in layers. Patient was administered injection ceftriaxone 1gm 12<sup>th</sup> hourly for 5 days, and prednisolone 60 mg per day for 7 days which was later tapered over a period of 1 week. The patient was observed for 3 days to rule out complications and later discharged with above medications. The patient had uneventful recovery and hoarseness of voice improved significantly after 2 weeks.

## Discussion

Penetrating injuries to the neck caused by missiles (metallic objects flying with high velocity) are occasionally encountered in ENT practice. Metal industry and construction workers and soldiers in combat are predisposed to such injuries [1-4]. These injuries are challenging as they can cause neurovascular damage, and penetrate or fracture laryngeal or tracheal cartilages. These fractures, hematoma, edema or foreign bodies can cause life threatening airway obstruction. Often the foreign body can be difficult to locate. Therefore preoperative imaging and localization of foreign body are important [2]. The entry wound may be small and misleading regarding severity of injury. Therefore these penetrating injuries must arouse suspicion of neurovascular or airway damage and should be managed by experienced surgeons. Penetrating neck injuries followed by subsequent airway endoscopy can result in complications like pneumothorax, pneumomediastinum, atelectasis etc. [5].

In literature, there are few reports where the penetrating airway foreign body was aspirated [1-4, 6-8]. These foreign bodies include



**Figure 2:** (A) Penetrating wound in the right ala of thyroid cartilage, (B) Metallic foreign body removed from right bronchus middle lobe medial segment opening.

metal pieces, or bullets piercing airway at an angle, or ricocheting or deviating after impact with cartilage and aspiration into bronchus [9]. These patients may not have symptoms of aspiration. Foreign bodies can be missed leading to complications like granuloma, segmental atelectasis, or pneumonia. These foreign bodies can migrate [8].

Imaging of the chest is important to identify, localize and plan treatment. Rigid bronchoscopy is the treatment of choice for removing these foreign bodies. Fiberoptic bronchoscopy can facilitate removal by basketing [10]. A 0° telescope passed through rigid bronchoscope can provide better and magnified view and help removal. It can ensure removal of all fragments of foreign body which can be non-obstructive and forgotten causing late complications [11,12].

Our patient was an onlooker standing close to a blacksmith at work. He had a missile (metal piece) penetrating injury to thyroid cartilage after lacerating anterior jugular vein. The laryngeal skeleton was not distorted. He had hoarseness due to submucosal hematoma in the larynx, but no airway obstruction.

The foreign body was lodged in the right bronchus at the opening of medial segment of middle lobe. There was no other airway injury. The surgical emphysema was due to air leak through the penetration in thyroid cartilage. A similar metallic foreign body aspiration in right lower bronchus has been reported in literature [1]. A metallic foreign body lodged in laryngeal lumen after penetrating the cartilage has been reported from India.

In our patient the foreign body must have been aspirated after penetrating the thyroid cartilage and losing momentum. The patient's reaction to the injury in form of neck extension and deep inhalation (gasp) could have further facilitated aspiration of foreign body into right bronchus. The foreign body was well localized by Chest X-ray and patient was clinically stable. The foreign body was removed by rigid bronchoscopy. A 0° telescope through the rigid bronchoscope facilitated the procedure.

The patient underwent neck exploration at the same sitting to evaluate damage to the laryngeal skeleton, soft tissues of neck and the source of bleeding. A lacerated anterior jugular vein was ligated. The penetrating wound in the soft tissues of neck and thyroid cartilage was irrigated with povidone iodine and sutured. There was no other vascular or neural injury.

As mentioned in similar reports in literature, the patient had uneventful recovery. The hoarseness of voice improved [1-3].

## Conclusion

Penetrating injuries to neck by high velocity flying metallic objects are an emergency and need to be evaluated for neurovascular injury, aspiration or airway compromise. A coordinated team effort by experienced surgeons and anesthesiologists in these challenging cases can ensure a safe removal of foreign body and recovery. Imaging and high index of suspicion can prevent missing these foreign bodies and late complications.

## References

1. Smith DF, Kieliszak CR, Stevens K, Ishman SL, Koch WM. Traumatic gunshot wound to the larynx with subsequent aspiration of the bullet. *Clin Pract.* 2014; 11(2): 149-51.
2. Lohiya TA, Bradoo RA, Shah KD. A Penetrating Neck Foreign Body Presenting in the Airway: a Diagnostic and Therapeutic Challenge. *Bombay Hosp J.* 2015; 57(3): 329-32.
3. O'Connor JV, Haan JM, Wright JL. Spent bullet in the bronchus. *Am Surg.* 2006; 72: 345-46.
4. Choh JH, Adler RH. Penetrating bullet wound of chest with bronchoscopic removal of bullet. *J Thorac Cardiovasc Surg.* 1981; 82(1):150-53.
5. Ono Y, Okubo Y, Hashimoto K, Inokuchi R, Odajima H, Tase C, et al. Massive subcutaneous emphysema, bilateral pneumothorax, pneumomediastinum, pneumoperitoneum, pneumoretroperitoneum, and pneumoscrotum after multiple direct laryngoscopies: an autopsy case report. *J Anesth.* 2015; 29(4):622-6.
6. Kiev J, Shepherd W, Moses L, Zhao X. Removal of an endobronchial bullet with flexible bronchoscopy nine years after injury. *J Trauma.* 2008; 65(3):741.
7. Symbas PN, Hatcher CR Jr, Viasis SE. Bullet wounds of the trachea. *J Thorac Cardiovasc Surg.* 1982; 83(2):235-238.
8. Bertolani MF, Marotti F, Bergamini BM, Pellegrino M, Balli R, Buonauro PLC. Extraction of a rubber bullet from a bronchus after 1 year: complete resolution of chronic pulmonary damage. *Chest.* 1999; 115(4): 1210-1213.
9. Andrews CM, Singh NN, Stewart RW. Bullet aspiration and spontaneous expectoration after gunshot wound to trachea. *Mil Med.* 2010;175(1):72-73.
10. Lax EA, Kiran SH, Lee MW. Bronchoscopic retrieval of a bullet using a Dormia basket: a case report. *J Med Case Rep.* 2014; 358.
11. Mohiyuddin SMA, Prasad KNV, Shivprakash KV, Babu VS, Chandrakala SK. Foreign Body aspiration- How safe are whistles in toys? *Int J Biomed and Healthcare Sci.* 2013; 3(2): 113-118.
12. Fulginiti J 3rd, Dedhia HV, Kizer J, Timberlake G. Retrieval of an aspirated bullet fragment by flexible bronchoscopy in a mechanically ventilated patient. *Chest.* 1993; 103(2):626-627.