



# Pellucid Marginal Degeneration (PMD): A Systematic Review

Georgios Tsokolas\*

Department of Ophthalmology, Royal Derby Hospital, University Hospitals of Derby and Burton NHS Trust, UK

## Abstract

**Purpose:** To describe the clinical features of Pellucid Marginal Degeneration (PMD) and to give an overview of current treatment options.

**Materials and Methods:** Literature review via PubMed, Mendeley, Scopus and Google Scholar.

**Results:** PMD is a rare ectatic disorder of the cornea that may resemble keratoconus especially at the early stages. It mainly affects the inferior cornea and induces against the rule irregular corneal astigmatism. Acute hydrops rarely occurs. PMD patients are at risk of corneal perforation after minimal ocular trauma or even spontaneously. Management of PMD includes the use of contact lenses, spectacles and a wide range of surgical techniques with variable results. To date, there are no large prospective interventional studies to elucidate the optimum surgical approach for advanced PMD, only case reports or case series.

**Conclusion:** Eye care practitioners need to be aware of the clinical and topographic findings of this disease, since laser refractive surgery is a contraindication. At the moment, there is no unanimity with regards to the optimum surgical treatment of PMD and larger prospective studies will be required to form a more robust algorithm for the surgical approach of PMD individuals whose vision cannot be corrected with spectacles or contact lenses.

**Keywords:** Corneal topography; Ectasia; Keratoconus; Keratoglobus; Keratometry; Optical Coherence Tomography (OCT); Pellucid Marginal Degeneration (PMD)

## Introduction

Pellucid Marginal Degeneration (PMD) is a rare form of corneal ectasia [1]. It mainly affects the inferior cornea leading to corresponding steepening and thinning, which explains the manifestation of “against-the-rule” astigmatism [2-5]. Nevertheless, there are other reports of PMD cases, where the other three quadrants of the cornea (superior, nasal and temporal) were affected and not the inferior [5-10]. Acute hydrops and corneal perforation, though rare, may still occur [1].

PMD is usually a condition that affects both eyes [1,2,5], however there are reports describing unilateral cases of PMD [11-14].

The term “pellucid” (meaning clear) was given for the first time by Schlaeppi in 1957 [1,15] to highlight that the cornea remained clear despite the fact that it was getting progressively more ectatic [1,15]. Around the same time, there were also other early publications describing the same condition [16-19].

In this review, the aim is to provide an overview of the clinical features and the management of PMD. This review also aims to highlight this rare form of corneal ectasia to junior ophthalmologists, refractive surgeons and optometrists, as it may be missed in the early stages. Therefore, all relevant professionals need to be able to detect it during the work-up of patients who present as potential candidates for corneal refractive surgery.

## Pathophysiology

To date, there is no unanimity with regards to the underlying pathophysiological mechanism that leads to the manifestation of PMD [1]. It has been postulated by some authorities that PMD along with other corneal ectasias such as keratoconus and keratoglobus are not separate clinical entities but they all represent variations of the same clinical entity [1-4]. Other reports agreeing with the aforementioned hypothesis describe the simultaneous presence of PMD with keratoconus [9,20,21] and simultaneous presence of PMD with keratoglobus [22].

## OPEN ACCESS

### \*Correspondence:

Georgios Tsokolas, Department of Ophthalmology, Royal Derby Hospital, University Hospitals of Derby and Burton NHS Trust, Uttoxeter Road, Derby, DE22 3NE, UK, E-mail: georgetsokolas@yahoo.com

Received Date: 09 Nov 2020

Accepted Date: 25 Nov 2020

Published Date: 14 Dec 2020

### Citation:

Tsokolas G. Pellucid Marginal Degeneration (PMD): A Systematic Review. *J Clin Ophthalmol Eye Disord.* 2020; 4(1): 1031.

Copyright © 2020 Georgios Tsokolas. This is an open access article distributed under the Creative Commons Attribution License, which permits unrestricted use, distribution, and reproduction in any medium, provided the original work is properly cited.

Induction of PMD has been reported after the completion of LASIK refractive surgery [23]. It is proposed that there are inherent weaknesses in the biomechanical features of the corneal stroma that led to the manifestation of corneal ectasia [23-26].

Histology and electron microscopy findings may be able to shed some light into the underlying pathophysiological mechanisms that lead to PMD. In the first histological study performed by Zucchini, it was noted that the Bowman's layer was absent but the corneal epithelium remained intact [16]. Zucchini also reported an increase in the presence of mucopolysaccharides in the corneal stroma and that the Descemet's membrane and corneal endothelium were also unaffected [16]. The presence of an increased concentration of mucopolysaccharides was also described by Francois et al. [17] in their light microscopy. Francois et al. [17] reported that the Bowman's layer was present but exhibited focal breaks. Contrary to Zucchini's report, where the corneal epithelium and Descemet's membrane were unaffected, Francois et al. [17] described epithelial edema and Descemet's membrane folds. The breaks in the Bowman's layer were also confirmed by Pouliquen et al. [27] on electron microscopy. Pouliquen et al. [27] also described the presence of irregularly arranged corneal stroma and granular deposits. Of note, Zucchini, Francois et al and Pouliquen et al. [27] report that in their corneal specimens with PMD, no inflammatory cells were present [16,17,27].

Another electron microscopy report that assessed PMD corneal specimens described the presence of areas of Fibrous Long Spacing (FLS) collagen with a periodicity of 100 nm to 110 nm in the peripherally thinned areas, scattered within regions of mostly normal collagen which had a periodicity of 60 nm to 64 nm [1,28]. The same report mentioned that FLS collagen fibrils were also observed in corneal specimens of patients with advanced keratoconus and corneal scarring [28].

All the above histological data may be in agreement with the postulation proposed by other authorities that there are inherent weaknesses in the biomechanical features of the corneal stroma that may result in the development of PMD [23-26].

## Epidemiology

Due to the rarity of the condition, no large prospective epidemiological studies are currently available. Reports from different authorities report that PMD seems to be less frequently seen compared to keratoconus [2-4], but PMD is more frequent than posterior keratoconus [29] or keratoglobus [29].

With regards to the frequency of PMD between males and females, there is no consensus. Older reports advocate that PMD exhibits no gender predilection [2-4,30], whereas more recent reports describe a slightly increased frequency in males [5,31,32].

There is also no unanimity with regards to the age that the symptoms of PMD start. Krachmer et al., Sridhar et al., Kompella et al., report that PMD starts usually between the second and fifth decade of life. However, Tzelikis et al. [31] postulates an older average age for the manifestation of the initial PMD symptoms. Finally, it appears that PMD affects equally all ethnicities and shows no geographical predilection [2-4,29,30].

## Genetic Background and Other Systemic Associations

Based on an extensive literature search, there is no established

association of PMD with a specific gene [1]. However, there are reports of familial cases of PMD in asymptomatic family members, who exhibited a significant astigmatic error in their refraction [18,22,33-35].

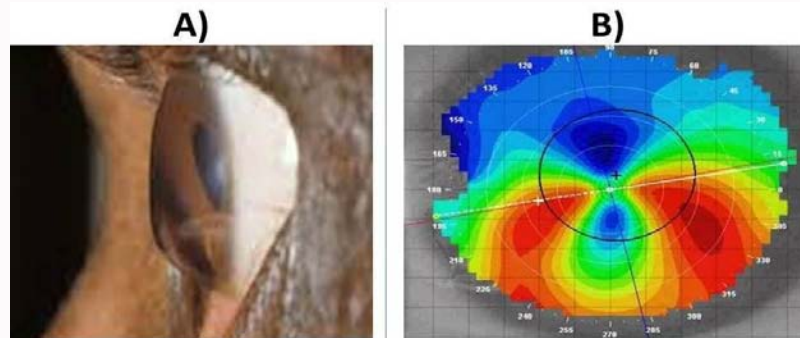
Despite the lack of association with a specific gene, there are numerous reports in the literature, where the authors describe the simultaneous presence of other ocular or systemic clinical conditions in PMD patients including retinitis pigmentosa [32], lattice degeneration [32], primary open angle glaucoma [36], hyperthyroidism [15,37], eczema [17,19], scleroderma [38] and atopic keratoconjunctivitis [39]. Nevertheless, none of the aforementioned conditions has exhibited a clear cut association with PMD.

## Signs and Symptoms

As mentioned previously in the manuscript, PMD is typically a bilateral condition [1,2,5], however unilateral cases have also been described in the literature [11-14]. Another typical clinical sign is the involvement of the inferior cornea in the vast majority of cases [1-5], although there are reports of PMD patients in the literature, where the other three quadrants were affected [5-10]. The inferior corneal thinning follows a crescent pattern and extends from the 4 o'clock to the 8 o'clock position [1]. In addition, the band of corneal thinning is clear with an average width of approximately 1 mm to 2 mm [3-5]. The thinning is severe, leading to a significant stromal tissue loss [1,4]. The limbus is usually spared with a 1 mm to 2 mm zone of clear cornea being present between the limbus and the area of thinning [1,4,28,30]. Another very important detail that needs to be highlighted is that the area of maximal thinning in PMD lies just below the area of maximal corneal protrusion [1]. This is a major difference between PMD and keratoconus; in keratoconus the area of maximal protrusion coincides with the area of maximal corneal thinning [1].

Corneal topography is the cornerstone investigation for the detection and observation of any form of corneal ectasia including PMD. There are different types of instruments to serve this purpose. The first computer-based topographer was the TMS-1 device (Tomey Technology, Waltham, MA, US), which used the Placido rings method [1]. The corneal topography instruments have evolved after the release of TMS-1 with more modern devices being available in the market, such as the Orbscan II (Bausch & Lomb, Rochester, NY, US), the Pentacam (OCULUS, Wetzlar, Germany) and the Visante Omni (Carl Zeiss Meditec, Dublin California, USA). The Orbscan II relies on combination of Placido disks and slit scanning to provide topographic details about the cornea [1]. The Pentacam device uses the Scheimpflug technology to give meticulous details about the corneal topography and thickness [1]. Finally, the Visante device uses a combination of anterior segment Optical Coherence Tomography (OCT) and Placido disks [1]. Given the extensive amount of information provided by these devices, it can be easily assumed that the use of corneal topography is of paramount importance in modern corneal refractive surgery, as it serves as a screening tool for the detection of subclinical or manifest corneal ectasias including forme fruste keratoconus, keratoconus and PMD [1,23,40]. Failure to detect such pathological entities may lead to a progression of the ectasia and compromise the result of corneal refractive surgery [1,23,40].

One of the most striking features of corneal topography is PMD is the flattening of the superior cornea at the 90 degree meridian, which results in the manifestation of "against-the-rule" astigmatism



**Figure 1:** Pellucid Marginal Degeneration. A) Clinical image showing significant thinning of the inferior cornea and the typical “beer-belly” configuration. B) Corneal topography showing the typical “crab claw” configuration of the inferior cornea.

of variable severity [1-4]. In addition, due to the ectatic changes, when viewed from the lateral side, the cornea adopts a “beer-belly” configuration [1,41-44] (Figure 1A). Nevertheless, different authorities iterate that the “beer-belly” configuration on its own is not pathognomonic of PMD and other details including the history, clinical examination and corneal topography must be taken into consideration before diagnosing a patient with PMD [1]. The hallmark pattern in corneal topography is described by different reports with different terms either as “crab claw”, “butterfly” and “kissing doves” [1,5,22,38,44-47] (Figure 1B). However, as with the “beer-belly” configuration, it must be noted that this corneal topographic pattern is not pathognomonic of PMD by itself and other important factors must be taken into account (e.g. clinical examination, pachymetry, clinical history, refraction) in order to achieve an accurate diagnosis of PMD in a patient with some form of corneal ectasia [1,44,48]. The most common symptom of PMD is the gradual worsening of the vision due to the manifestation of significant amount of irregular “against-the-rule” astigmatism [1-4]. Acute hydrops with sudden onset pain, redness and blurring of vision may rarely occur in a similar fashion as with keratoconus [1,49-60]. Hydrops occurs due to breaks in the Descemet’s membrane, which in turn leads to shifting of fluid into the corneal stroma and subsequent corneal haze and edema [1]. Perforation due to an episode of acute hydrops or spontaneously may also occur [1,49-60]. In cases of superior PMD with acute hydrops, the authors describe that the inferior cornea perforated [6,52]. After the resolution of the episode of acute hydrops, corneal scarring with neovascularization may ensue [1].

Unlike keratoconus, no obvious cone or lipid deposition are recognized on clinical examination [1-3]. In addition, Fleischer ring is not seen in PMD [1]. Munson’s sign (V-shaped deformity of the lower eyelid on downgaze) and Rizzuti sign (conical reflection of light at the nasal limbus when a beam of light is cast temporally) are not seen in PMD, but they can be seen quite frequently in keratoconus [1]. Patients with keratoconus may exhibit scissoring of the red reflex on retinoscopy, whereas PMD patients do not typically exhibit such changes in their red reflex [1]. As mentioned previously in the manuscript, the area of maximal thinning and the area of maximal protrusion coincide in keratoconus, whereas in PMD the area of maximal thinning lies just below the area of maximal corneal protrusion [1]. Finally, the “crab-claw” pattern seen in PMD may also be present in keratoconus, but in keratoconus other patterns may be observed : 1) An increased area of corneal power surrounded by concentric areas of decreasing power or 2) Inferior-superior power asymmetry or 3) Skewing of the steepest radial axes above

and below the horizontal meridian [1]. All the above details are very useful in order to distinguish PMD from keratoconus.

### Grading Scale for the Severity of PMD

Due to the rarity of PMD, to date, there is no formal grading system to assess the different stages of its severity. Nevertheless, there are reports describing early [26,42,61], moderate [13,62,63] and advanced [5,64,65]. Progression of one stage to the other may ensue over time [1].

### Differential Diagnosis

There are a wide range of other ocular clinical entities that need to be considered prior to the diagnosis of PMD, as they may share similar signs and symptoms with PMD. The most important ones are keratoconus, keratoglobus, Mooren’s ulcer and Terrien marginal degeneration.

In a previous section of the manuscript, the differences between PMD and keratoconus were briefly discussed. There are also additional important details that may facilitate the distinction between PMD and keratoconus. In moderate cases of PMD, the distinction from keratoconus can be achieved by slit lamp examination due to the very typical location of the corneal thinning [1,66]. However, recognizing early cases of PMD may be challenging because the cornea may look normal and that can trick the examiner [1]. In addition, it is challenging to distinguish advanced PMD from keratoconus, because the thinning is so extensive [1,4]. This is where the corneal topography comes into play, because the two clinical entities usually exhibit different topographic patterns [1,22,45,67]. Usually, keratoconic eyes demonstrate the presence of a cone which is displaced inferiorly with a more profound steepening of the inferior cornea compared to the superior that extends towards the inferior limbus [1,67]. The inferior temporal cornea seems to be more profoundly affected [1,68]. In conjunction with the corneal topography, the use of pachymetry maps has also been advocated [1,48]. In summary, an accurate distinction between PMD and keratoconus is crucial, because this will affect the management and subsequent prognosis [1,69].

Keratoglobus is another important form of corneal ectasia that needs to be distinguished from PMD. Keratoglobus is usually present at birth [44], whereas PMD manifests later in life. In keratoglobus, the cornea adopts a spherical shape (as the name of the entity implies) [70] and the thinning is universal, spreading from limbus to limbus, whereas in PMD usually the thinning is located inferiorly with the typical “beer-belly” appearance. Furthermore, the limbus



is usually spared with a 1 mm to 2 mm zone of clear cornea being present between the limbus and the area of thinning [1,4,28,30]. The classical topographic “crab claw” pattern seen in PMD is not seen in keratoglobus. The typical finding in the corneal topography in a patient with keratoglobus is generalized steepening [44]. The generalized steepening results in very high keratometry values ranging from 60 to 70 diopters [71]. Eyes with keratoglobus may rarely demonstrate clinical features usually seen in keratoconus such as Vogt’s striae, sub-epithelial scarring, Fleischer’s ring, lipid deposition and corneal vascularization [1,71,72]. Corneal neovascularization and scarring may be rarely seen in PMD after an episode of acute hydrops, but the rest of the aforementioned signs are not seen in PMD [1]. Acute hydrops may rarely present in both conditions [1,29].

Another important clinical entity that must be distinguished from PMD is Mooren’s ulcer. This condition represents a type of inflammatory peripheral ulcerative keratitis, which gradually spreads centrally [73]. As the name of the condition implies, there is presence of a variable size epithelial defect with peripheral corneal infiltrates and ulcer [1,73-75]. This is a very striking difference with PMD, which is a non-inflammatory condition, where the epithelium in PMD remains intact [1,16,17,27]. In addition, corneal neovascularization occurs quite frequently in cases of Mooren’s ulcer, whereas in PMD this seldom occurs (usually after an episode of acute hydrops). [1]. To date, the etiology of PMD remains unclear, whereas there are reports suggesting potential association of Mooren’s ulcer with hepatitis C and other factors including surgery, trauma and other infections [76- 84]. Finally, the main similarity of both conditions is the subsequent corneal thinning [1,85]. Nevertheless, the area of thinning in PMD contains intact corneal epithelium without the presence of lipid deposition and new vessels and remains transparent [1,4,66].

Terrien’s marginal degeneration is a bilateral condition with prominent male predilection described in the literature [1,86-89]. On the other hand, the gender predilection of PMD is still controversial with older published reports advocating no gender predilection [2-4,30] and more recent ones suggesting a slight male predilection [5,31,32]. Usually, patients with Terrien’s marginal degeneration are usually younger than PMD ones [1,2,5,31,32,87]. Unlike PMD, the corneal thinning in Terrien’s marginal degeneration starts superiorly and spreads circumferentially [1,4,86-89]. As the disease progresses, a “gutter-like furrow” is formed [1,4,86-89]. There is no epithelial defect in the furrow in a similar fashion to PMD, but there is lipid deposition that renders the cornea opaque, whereas in PMD the affected cornea remains transparent (as the word pellucid implies) [1,4,15,66]. Another clinical feature of Terrien’s marginal degeneration is the development of pseudopterygia adjacent to the area of the furrow, which on the other hand is not a feature of PMD [1,90,91]. The corneal thinning in Terrien’s marginal degeneration may affect the inferior cornea but usually spares the interpalpebral corneal region [1,4]. There are a few cases of central corneal ectasia associated with Terrien’s marginal degeneration [1,92,93]. The corneal topography exhibits flattening of the areas that are becoming thinner and at the same time this induces profound steepening of the meridian located 90 degrees away from the area of thinning [1,92,93]. As a result, significant amount of “against-the-rule” astigmatism will appear causing significant blurring of the vision [1,94]. “Against-the-rule” astigmatism may be a sign of PMD but, unlike PMD, the typical crab claw pattern is not a corneal topographic feature of Terrien’s marginal degeneration. Spontaneous or trauma induced corneal perforation may rarely occur in both conditions [1,4]. Another feature that may facilitate the distinction between PMD and Terrien’s marginal

PMD and Terrien’s marginal degeneration is that PMD is a non-inflammatory corneal ectasia, whereas Terrien’s marginal degeneration may seldom present with eye redness, pain and ocular irritation [1,95,96]. Finally, PMD has not been proven to be associated with a specific systemic condition [1]. On the other hand, there are very few reports in the literature suggesting that Terrien’s marginal degeneration may be associated with other ocular or systemic conditions [91, 97-100]. Table 1 summarizes the clinical features of the three most common corneal ectasias.

## Management of PMD

In chronic cases, the management of PMD can be divided into conservative and surgical. Conservative management mainly focuses on the correction of refractive errors (mainly astigmatism) with spectacles or with contact lenses. Surgical methods are used when the conservative measures have failed. As mentioned previously, PMD can present very rarely with acute hydrops or perforation which must be managed accordingly as well. Below, the management of PMD will be discussed in greater depth.

### Conservative management

In early stages, PMD can be managed with the use of spectacles as an attempt to correct the refractive errors [1, 13, 69, 101, 102].

In addition to spectacles, soft toric contact lenses are an alternative viable option in the early stages of the disease, mainly before the manifestation and progression of irregular astigmatism [1,5,32,103].

Hybrid lenses can also be used to optimize the visual acuity in PMD patients at the early stages of the disease. They are formed by Rigid Gas Permeable lenses (RGPs). In the literature, different brands of hybrid lenses have been described including Saturn II lenses (Pilkington Barnes-Hind Inc., Sunnyvale, CA, US), SoftPerm lenses (Pilkington Barnes-Hind Inc., Sunnyvale, CA, US), SynergEyes lenses (SynergEyes Inc., Carlsbad CA, US) [104-109]. Saturn II lenses were the first generation of hybrid lenses [1] followed by the second generation SoftPerm hybrid lenses [1]. SynergEyes represented the third generation of hybrid lenses [1].

Saturn II hybrid lenses were successful in the optimization of the visual acuity in PMD patients [1,104]. However, they were found to become tighter with prolonged wearing periods. [1,109]. The tightening in combination with the low oxygen permeability of Saturn II lenses ( $Dk=14 \times 10^{-11} \text{ (cm}^2/\text{s) (mlO}_2\text{/ml} \times \text{mmHg)}$ ) led to the manifestation of corneal edema and subsequent neovascularization [1,110].

SoftPerm hybrid lenses were manufactured by the same materials as the first generation of hybrid lenses but there was a modification [1]. The second generation hybrid lenses had a larger diameter with modified edge to avoid the tight fitting of the Saturn II lenses and facilitate the tear circulation [1]. This prevented the complications of corneal ischemia. However, the use of SoftPerm lenses was not free of problems. Two main problems were the fragility at the junction between the soft and the rigid gas permeable lenses and the increased frequency of giant papillary conjunctivitis [1,111-113].

SynergEyes hybrid lenses were the evolution of the previous two generation hybrid lenses and held better properties. The junction between the soft and the RGP lens was more robust. Furthermore, the lens exhibited increased oxygen permeability ( $Dk=100 \text{ (cm}^2/\text{s) (mlO}_2\text{/ml} \times \text{mmHg)}$ ). [1]. Nonetheless, giant papillary conjunctivitis, allergies and fitting issues were reported [1,107,108].

**Table 1:** Summary of the differences between the three most common corneal ectasias.

Clinical Feature	Pellucid Marginal Degeneration	Keratoconus	Keratoglobus
Age of onset	Between 2 <sup>nd</sup> and 5 <sup>th</sup> decade of life	Puberty	Birth
Etiology	Unknown	Unknown	Unknown
Location of maximal thinning	Inferior cornea from 4 to 8 o' clock	Central and Paracentral	Generalized
Location of maximal protrusion	Above the area of maximal thinning	Coincides with area of maximal thinning	Generalized, spherical shaped cornea
Presentation	Blurred vision	Blurred vision	Blurred vision
Scarring	Rarely may occur after hydrops	Common	Rarely may occur
Hydrops	May seldom occur	Common	May seldom occur
Corneal Topography	Typically Crab Claw Appearance	An increased area of corneal power surrounded by concentric areas of decreasing power or inferior–superior power asymmetry or skewing of the steepest radial axes above and below the horizontal meridian)	Generalized Steepening
Corneal Thickness	Usually normal	Reduced	Reduced
Munson Sign	Absent	Present	Absent
Rizzuti Sign	Absent	Present	Absent
Fleischer Ring	Absent	Present	Very rarely present
Scissoring of retinoscopy reflex	Present only in advanced cases	Present in all stages of the disease	Absent
Oil droplet red reflex	Absent	Present	Absent

Table 1 Cumulative table summarizing the clinical features of the three most common corneal ectasias. The table is an amalgamation of the information provided by Jinabhai et al. [1], Krachmer et al. [2], Moshirfar et al. [44] and Romero-Jimenez et al. [101]

When PMD progresses from the mild to the moderate stage, hybrid lenses cannot be used. The changes in the corneal shape prevent the attachment of the soft lens on the corneal surface. Therefore, single cut/spherical RGP lenses alone can be used to optimize the visual acuity. A main issue is the adequate fitting and stability on the corneal surface. This can be addressed by a step by step increase of the diameter of the RGP lens, which in turn facilitates a better fit and simultaneous improvement in the visual acuity as described in some reports in the literature [1,31,32,64,103].

A more evolved type of RGP lenses are known as “bi-toric” RGPs. These lenses contain two different curves, one for the front and the other for the back corneal surface. There are three reports in the literature, which described satisfactory outcomes in the correction of visual acuity and adequate level of tolerance with the use of the “bi-toric” RGPs [1,46,114,115]. The main weakness of these three reports was that they failed to determine a clear wearing duration pattern for these special lenses [1].

Reverse geometry lenses are special lenses, in which the second curve (known as the reverse curve) is steeper than the base curve with the rest of the curves becoming gradually flatter. They are widely used in the field of orthokeratology. Only one case report was found in the literature, where the authors used successfully reverse geometry lens in a male patient of Hispanic origin with early PMD in order to optimize the vision [1,37]. However, reverse geometry lenses are more useful in patients with corneas that exhibit generalized negative eccentricities, whereas in PMD the negative eccentricities are localized mainly at the inferior cornea [1,46]. Therefore, reverse geometry lenses may cause tight binding to the superior cornea affecting the tear distribution causing dry eyes and subsequent compromise of the corneal epithelial integrity [1].

In the advanced stages of PMD, fitting RGP lenses can be very difficult, because the protrusion of the inferior ectatic cornea will pose problems with lens centration and induce an easy dislodging of the lens with blinking [1]. There are reports in the literature describing the use of scleral contact lenses in advanced PMD [1,13,116-119]. Scleral

contact lenses provide numerous advantages. They are supported by the scleral coat and this minimizes lid sensation and also the chance of dislocation upon blinking [1]. They provide good centration and exhibit very small chance of foreign body entrapment [1]. In addition, they form a frame around the affected corneal area achieving the smoothing of the corneal irregularities in order to facilitate a better fitting of the lens [1]. On the other hand, scleral contact lenses exhibit low oxygen permeability and their manufacturing process is very tedious [1]. Moreover, they are more difficult to apply on the eye compared to the conventional corneal RGP lenses [1]. Finally, there are very few experts who know how to fit these special lenses, restricting the potential for wider view [1].

The reviewed literature points out that the majority of PMD patients (approximately 88%) are managed conservatively either with spectacles or with contact lenses [1,32,102]. The rest 12% is managed surgically [1,32,102]. The surgical treatment of PMD will be discussed in greater detail below.

### Surgical treatment

The surgical treatment can be divided into four subcategories: i) Structural/Mechanical interventions, ii) Partial thickness interventions, iii) Full thickness interventions, iv) Toric Intraocular Lens Implantation, v) Combination of the above. All subcategories will be discussed separately below.

**Structural/mechanical interventions:** Intrastromal Corneal Rings (ICRS) are devices made of Polymethylmethacrylate (PMMA) [44]. They are inserted in the mid-peripheral corneal stroma away from the visual axis at approximately two thirds of depth [1,44,120]. The insertion of such a device alters the distance between the collagen bundles within the corneal stroma [1,44,120]. The ring produces an arc shortening which is proportional to the thickness of the ring [1,44,120]. As a result, there is a reconfiguration of the structure of the anterior corneal surface and at the same time, there is also a modification in the positive asphericity (prolate profile) of the cornea. [1]. The insertion of the ring is achieved either by a manual

incision with a keratome on the cornea or by a femtosecond laser assisted incision [44]. The ICRS were originally used for the correction of myopia [1,44,120], but in spite of the original promising results, their use for the correction of shortsightedness was abandoned mainly because of limited range of correction, induced astigmatism, and slow visual recovery [121]. In this modern era of corneal surgery, ICRS still have their role in the treatment of corneal ectasias including keratoconus, PMD and post refractive corneal ectasias [61,62,122-131]. Mularoni et al. [62] suggests that ICRS are a viable option for the treatment of early and moderate PMD. Nevertheless, there are significant shortcomings with the use of ICRS, namely regression over time, unpredictability in the visual outcome and corneal melting [1,44,124-126,132,133]. Another important disadvantage of ICRS is their inability to halt the progression of PMD [1,44,62,127-129].

Another surgical intervention that aims to alter the shape of the ectatic cornea is Collagen Cross Linking (CXL). The principle of CXL is the induction of covalent bonds between the collagen bundles in order to impede the progress of corneal ectasia [44,134]. The procedure is done in theatre under sterile condition after written consent. The epithelium is debrided with the application of alcohol solution and then drops of riboflavin are instilled on the cornea [44]. In other studies, the corneal epithelium was not debrided [44,135]. After the riboflavin instillation, the eyes are exposed to ultraviolet-A light [44,136,137]. The energy used varies between 3 mW/cm<sup>2</sup> to 30 mW/cm<sup>2</sup> and the duration of exposure ranges between 3 min to 30 min [44,136,137].

Based on our literature review, CXL has been used as treatment for PMD only in case reports [138-141]. It must be highlighted that only in one of these reports CXL was used as treatment modality on its own [138], whereas in the rest CXL was combined with other surgical treatments [139-141]. One important weakness of this treatment modality is the restricted improvement in visual acuity and corneal topography [44,136,142]. Another significant issue is the potential limbal stem cell deficiency induced by ultraviolet-A light [44,134] and this becomes even more significant in PMD due to the proximity of the limbus with the area of corneal thinning [44]. Therefore, more studies should be conducted in order to elucidate the safety and efficacy of CXL in PMD.

**Partial thickness interventions:** Deep Anterior Lamellar Keratoplasty (DALK) is a form of surgical intervention, in which the diseased cornea is replaced by healthy donor but the corneal endothelium is spared [44,143]. It is a widely accepted surgical technique for the management of keratoconus provided there is no history of previous episodes of hydrops and it is considered a viable alternative to Penetrating Keratoplasty (PK) [144-149]. The main advantages of DALK vs. PK are shorter time to suture removal, shorter course of topical steroid treatment, reduced endothelial cell loss and fewer postoperative complications [44,150]. Other advantages, though the data is limited, are reduced rates of rejection and reduced refractive astigmatism [148]. However, it is still technically more challenging to master compared to PK and also stromal rejection may still occur [44]. In addition, there is a significant risk of haze between the graft and host interface which may affect the final visual outcome [44]. There are different surgical approaches to DALK including big bubble technique and femtosecond assisted DALK [44,151,152]. Having all the above in mind, only very few manuscripts in literature were detected, where the use of DALK in treating PMD was used [55,143,153]. In the manuscript by Kodavoor

et al. [153] only one patient with PMD was included who underwent DALK. DALK in this patient was accompanied by the complication of double anterior chamber which was successfully managed. Millar et al. [55] described the application of bilateral DALK in one patient and reported no complications and satisfactory visual outcome. Al-Torbak [143] has up until the present day the largest case series of sixteen eyes suffering from PMD that underwent DALK. Al-Torbak [143] reported that two out of sixteen eyes had intraoperative perforation, which was managed with injection of air or a mixture of perfluoropropane (C3F8) with air (14% C3F8, 86% air). In addition, the perforation did not have a significant impact on the final visual acuity [143]. Post-operatively, two out of sixteen eyes exhibited graft-host neovascularization [143]. In summary, as with CXL and ICRS, the present data for the use of DALK in treating PMD is very limited and therefore larger prospective studies should be conducted in order to establish the safety and efficacy of DALK as a means of surgical treatment of PMD.

Crescentic Lamellar Keratoplasty (CLK) is another form of partial thickness surgical intervention that has been used for the treatment of PMD. It involves the surgical removal of unhealthy corneal stroma, which is then replaced by a stromal graft [1,5,44,154-156]. The benefits of this surgical approach is that the globe remains closed and also similar to DALK the endothelium is spared, thus the risk of endothelial rejection is minimized [44,154-156]. Two reports describe that CLK in combination with contact lenses and spectacles can produce good visual outcomes [154-156]. The same technique has been used for the treatment of corneal perforation [154-156]. The main disadvantages are the post-operative induced astigmatism, the potential opacification of the graft-host interface and the increased difficulty performing it, which requires a very steep learning curve [44]. As with other previously described surgical approaches, no larger prospective studies exist for CLK in order to establish the long term usefulness and safety of this procedure.

Lamellar thermokeratoplasty (LTK) is a modified version of CLK. In LTK, thermal burns are applied to the host corneal stroma prior to the implantation of the grafted stromal tissue [13]. However, there is limited data in the literature about the safety and efficacy of LTK and no larger prospective studies exist in order to establish the long term usefulness and safety of this procedure.

Epikeratoplasty is another type of lamellar surgical approach to tackle PMD. The procedure involves the suturing of donor corneal lenticule onto the anterior corneal surface as an attempt to alter the shape and refractive properties of the cornea [1,44,157]. However, only one manuscript in the literature was detected that describes the use of epikeratoplasty as a means of surgical treatment for PMD [157]. Only two patients were included in the manuscript [157]. The visual outcomes reported were very good [157]. The main complication that was reported in the manuscript was the formation of folds between the donor lenticule and the host cornea [157]. Due to the improvement in other surgical techniques, this procedure has been deemed obsolete.

Crescentic Lamellar Wedge Resection (CLWR) involves the removal of the abnormal corneal stroma and the subsequent approximation of the residual stromal edges [44,63,158-161]. It does not require donor grafts and during the procedure the globe remains closed [44,160]. In all manuscripts that were detected through the literature search, the number of eyes was very small. Javadi et al. [63] described a series of 15 eyes (9 patients) and reported no significant complications with CLWR. Cameron presented his own case series



with 5 eyes (4 patients) [158]. In all five patients in that case series in that case series, inferior pannus was a universal complication [158]. In addition, one eye had recurrence of thinning [158]. Maccheron et al. [159] presented 7 eyes (6 patients), who underwent CLWR. Intraoperative microperforation was reported in 14% of the treated eyes [159]. In addition, suture infiltrates were observed in 34% of the treated eyes [159]. In the case report by Andrade et al., CLWR delayed the need for PK for over a decade [160]. As with other previously described surgical methods, these manuscripts provide a limited number of eyes/patients and follow-up and therefore larger prospective studies are required to elucidate whether CLWR is a safe and effective surgical approach for the treatment of PMD.

Another type of partial thickness surgical approach for PMD is known as Tuck-in Lamellar Keratoplasty (TILK). TILK involves the formation of a central lamellar keratoplasty with intrastromal tucking of the peripheral flange [44,161,162]. It is postulated that an important advantage of TILK is the provision of stronger biomechanical support to the peripheral cornea [44,161,162]. The literature review that was conducted identified three manuscripts describing the application of this surgical technique [161-163] and one with a slight modification of TILK named "crescentic TILK" [164]. Two of these manuscripts were case series of very limited number of eyes [161,163] and the other two case reports [162,164]. Kaushal et al. [161] recruited eight patients suffering from combined keratoconus and PMD and four patients with keratoglobus and reported good visual outcomes with no significant complications. Arora et al. [164] described a case of "crescentic TILK" in a patient with PMD and reported very good visual outcome as well. Nevertheless, the current published data for TILK is very limited and therefore larger prospective studies are necessary to elucidate the safety and efficacy of TILK and make it more popular amongst the corneal surgeons.

**Full thickness interventions:** Penetrating Keratoplasty (PK) is a form of corneal transplant surgery, where all corneal layers are replaced by a new healthy donor corneal tissue. It is reserved as the last line surgical treatment in advanced PMD [13,20,165]. The case series published by Varley et al. [20] provided useful information about the application of PMD that underwent PK. This case series was published in 1990 and covered a 14 year period from 1974 to 1988 [20]. Twelve eyes of 11 patients underwent PK with large eccentric grafts [20]. One graft failed because of a persistent epithelial defect with keratolysis of the wound [20]. Seven out of the residual 11 eyes exhibited episodes of endothelial rejection which were treated successfully [20]. Retinal detachment and bacterial ulcer were reported in that case series [20]. Loose sutures and graft neovascularization were not significant complications [20]. Overall, the authors suggest that PK is a viable means of surgical treatment for advanced PMD. However, large eccentric grafts were associated with high degrees of irregular astigmatism due to the difference between the donor and graft corneal thickness [20,44]. In addition, large eccentric grafts have also been associated with other major complications, namely graft neovascularization, suture complications, secondary glaucoma due to angle structure damage, and graft rejection [20,44,165]. Another important consideration is the long term survival of a PK graft, especially in younger individuals, who possess a stronger immune system which can induce a stronger inflammatory response [44]. Finally, in PMD the peripheral cornea is affected, whereas other corneal layers (mainly the endothelium) and the central cornea preserve their integrity [44]. Hence, it is scientifically challenging to provide adequate justification for the replacement of all the corneal

layers [44]. This is the reason why PK is not opted as first line means of surgical treatment for PMD but other forms of partial thickness surgical interventions are suggested and these were discussed in greater detail previously in this review manuscript.

Full Thickness Wedge Resection (FTWR) is similar to CLWR but the difference is that in FTWR the globe is open, whereas in CLWR it remains closed [44,166-168]. Similar to CLWR, FTWR does not require donor tissue and seems to have shorter recovery time compared to PK [44]. MacLean et al published the first case series of 10 eyes of 9 patients who underwent the procedure [166]. In that case series, 3 eyes developed inferior corneal graft pannus, 1 eye developed choroidal detachment, 1 eye developed hydrops and 1 eye had wound leak [166]. Of note, all eyes in that case series exhibited significant astigmatic drift [166]. The author suggested that the technique should be modified to address all the aforementioned issues [166]. In 2000, Biswas et al. [13] reported no complications in their own case series of six eyes. In 2008, Busin et al. [168] performed combined FTWR with corneal relaxing incisions in 10 eyes and reported very minimal astigmatic drift. To this day, no other publications about the use of FTWR in the treatment of PMD were detected. As with previous surgical techniques, the aforementioned studies provide limited data and therefore larger prospective studies are required in order to make FTWR a more mainstream surgical approach for PMD.

**Toric intraocular lens implantation:** Toric Intraocular Lenses (IOLs) can be used for the correction of refractive error and astigmatism in individuals with PMD. Toric IOL implantation can be implanted either in the anterior or posterior chamber with or without simultaneous crystalline lens extraction [44]. If the crystalline lens is preserved, then the IOL implant is called toric phakic IOL (tp IOL) [44].

Toric IOLs have been used in patients suffering from corneal ectasia, mainly keratoconus [169-172]. They have also been used in PMD patients [173,174]. In 2012, Camoriano et al. [173] described a retrospective case series of ten eyes of five patients with PMD, where a tp IOL was inserted with preservation of the natural crystalline lens. The reported visual outcomes were satisfactory [173]. One eye suffered from severe haloes and glare post-operatively, hence requiring IOL removal [173]. Based on these findings, the authors suggest that tp IOLs seem to be a promising surgical treatment modality for the optimization of visual acuity in PMD patients [173]. In 2015, Balestrazzi et al. [174] published a prospective case series of eleven eyes of 8 patients who suffered from stable PMD and cataract. The eyes enrolled in the study underwent standard phacoemulsification with toric IOL insertion [174]. There were no intraoperative complications [174]. Moreover, the patients reported no significant visual disturbances such as haloes and glare and the refractive outcomes were satisfactory [174]. Apart from these two case series, no other studies were found about the application of toric IOLs for the management of PMD. As with other aforementioned surgical techniques, the current data available is limited and larger prospective studies are vital to determine the safety and efficacy of toric IOLs. Another disadvantage of this surgical technique is that, though treating the refractive errors, it does not target the structural and biomechanical properties of the ectatic cornea and therefore does not prevent the progression of PMD [44]. As a result, the condition progresses and this may necessitate the need for spectacles and potentially another form of surgery after a while [44].

**Combination of surgical interventions:** Combination of surgical

treatments has been initiated by some authorities, because there is currently no surgical approach that can tackle both the refractive errors and the modification of the structural properties of the cornea at the same time [44].

Kymionis et al. [139] described a prospective case series of PMD patients that underwent combined CXL with Photorefractive Keratectomy (PRK). The authors used conventional PRK and avoided topography based PRK in order to avoid significant loss of corneal stromal tissue [139]. The authors reported no intra- or post-operative complications in their prospective interventional study and satisfactory visual outcomes [139]. This study had its own limitations, namely the limited number of patients enrolled, the absence of control group, the lack of prolonged follow-up [139]. However, it was the first study that provided promising results with regards to the use of CXL especially in the prevention of post PRK corneal ectasia, which is the major concern of every refractive corneal surgeon [44,139]. Similar promising results were reported in another case series published in 2010 by Stojanovic et al. [175] but the differences in that case series was the use of topography-guided transepithelial surface ablation and the inclusion of eyes with keratoconus and eyes with PMD. Kymionis et al. [139] focused solely on PMD and did not include eyes suffering from keratoconus. Kymionis et al. [140] reported the use of combined CXL and PRK in one patient who underwent ICRS implantation previously. The authors combined CXL and PRK in an attempt to halt the progression of PMD and improve the visual acuity without removing the previously inserted ring from the cornea [140]. The patient had a very good outcome. As iterated many times above, larger prospective studies assessing the combination of CXL with PRK should be conducted in order to make this treatment modality more mainstream.

In 2019, Kymionis et al. [141] described the first case of a 53 year-old male patient who suffered from advanced PMD and underwent combined CXL with sectoral lamellar crescentic wedge resection of the thinner inferior part of the cornea. The first eye was treated solely with sectoral lamellar crescentic wedge excision of the thinner inferior part of the cornea affected by the disease. The inferior cornea was then sutured [141]. However, despite the initial good result, after the first few months regression was observed [141]. In order to tackle regression, the authors used the same surgical technique combined with CXL as an attempt to stabilize the biomechanical properties of the cornea long term [141]. Eight months after surgery, the authors reported that the second eye demonstrated stabilization of the corneal structure with absence of regression and good visual acuity [141]. The authors suggest that the concomitant use of the two surgical techniques may be a viable option for the treatment of PMD. As this manuscript is a single case report, the data provided is not sufficient enough to make the combination of CXL with sectoral lamellar crescentic wedge excision a mainstream treatment modality.

### Acute management

PMD can rarely present with acute hydrops or corneal perforation [1,49-60]. Hydrops can be managed with cycloplegics, lubricants, bandage contact lenses and topical antibiotics in a similar fashion to keratoconus [176-179]. Other treatment modalities include injection of air and tension sutures [180]. Of note, hydrops cases have also been reported after suture removal from a PK graft which was performed due to advanced PMD [179]. In cases of perforation, the management will depend upon the size and location of the perforation

[180]. The management of corneal perforation includes gluing, amniotic membrane transplantation or corneal transplantation [180].

### Conclusions/Final Comments

The literature search did not find any other published manuscripts where other combinations of surgical treatments were described. Of all the aforementioned treatments, CXL combined with another partial thickness surgical intervention seems to be promising. Ideally, large multicenter double-blind prospective studies should be conducted in order to elucidate the optimum surgical management of PMD. It is acknowledged by the author that such a task will be very challenging to accomplish due to the rarity of PMD. The paucity in numbers of PMD patients prevents the recruitment of large amount of participants which would provide enhanced validity to such study and also raises doubts about the cost-effectiveness of such project.

In summary, PMD is a rare ectatic disorder of the cornea that may resemble keratoconus especially at the early stages. It can be managed either conservatively or surgically with a wide range of treatment modalities. In the modern rapidly evolving world of refractive surgery, junior ophthalmologists, refractive surgeons and optometrists need to be aware of this condition, as it may go undetected at early stages and may complicate the outcomes of laser refractive surgery. At the moment, there is no unanimity with regards to the optimum surgical treatment of PMD and larger prospective studies will be required to form a more robust algorithm for the surgical approach of PMD individuals whose vision cannot be corrected with spectacles or contact lenses.

### References

- Jinabhai A, Radhakrishnan H, O' Donnell C. Pellucid corneal marginal degeneration: A review. *Cont Lens Anterior Eye*. 2011;34(2):56-63.
- Krachmer JH, Feder RS, Belin MW. Keratoconus and related non inflammatory corneal thinning disorders. *Surv Ophthalmol*. 1984;28(4):293-322.
- Krachmer JH. Pellucid marginal corneal degeneration. *Arch Ophthalmol*. 1978;96(7):1217-21.
- Robin JB, Schanzlin DJ, Verity SM, Barron BA, Arffa RC, Suarez E, et al. Peripheral corneal disorders. *Surv Ophthalmol*. 1986;31(1):1-36.
- Sridhar M, Mahesh S, Bansal AK, Nutheti R, Rao G. Pellucid marginal corneal degeneration. *Ophthalmology*. 2004;111(6):1102-207.
- Taglia DP, Sugar J. Superior pellucid marginal corneal degeneration with hydrops. *Arch Ophthalmol*. 1997;115(2):274-5.
- Rao SK, Fogla R, Padmanabhan P, Prema M, Sitalakshmi G. Corneal topography in atypical pellucid marginal degeneration. *Cornea*. 1999;18(3):265-72.
- Bower KS, Dhaliwal DK, Barnhorst Jr DA, Warnicke J. Pellucid marginal degeneration with superior corneal thinning. *Cornea*. 1997;16(4):483-5.
- Sridhar MS, Mahesh S, Bansal AK, Rao GN. Superior pellucid marginal corneal degeneration. *Eye (Lond)*. 2004;18(4):393-9.
- Ertan A, Bahadir M. Management of superior pellucid marginal degeneration with a single intracorneal ring segment using femtosecond laser. *J Refract Surg*. 2007;23(2):205-8.
- Wagenhorst BB. Unilateral pellucid marginal degeneration in an elderly patient. *Br J Ophthalmol* 1996;80(10):927-8.
- Basak SK, Hazra TK, Bhattacharya D, Sinha TK. Unilateral pellucid marginal degeneration. *Indian J Ophthalmol*. 2000;48(3):233-4.
- Biswas S, Brahma A, Tromans C, Ridgway A. Management of pellucid



- marginal corneal degeneration. *Eye (Lond)*. 2000;14(Pt 4):629-34.
14. Kaushik S, Jain AK, Saini JS. Unilateral pellucid marginal degeneration. *Eye (Lond)*. 2003;17(2):246-8.
  15. Schlaeppli V. La dystrophie marginale inferieure pellucide de la cornee. *Probl Actuels Ophthalmol*. 1957;1:672-7.
  16. Zucchini G. Su di un caso di degenerazione marginale della cornea – varietà inferiore pellucida – studio clinico ed istologico. *Ann Ottalmol Clin Oculist*. 1962;88:47-56.
  17. Francois J, Hanssens M, Stockmans L. Degenerescence marginale pellucide de la cornee. *Ophthalmologica*. 1968;155(5):337-56.
  18. Nagy M, Vigvary L. Beitrage zur atologie der degeneratio marginalis pellucid cornea. *Klin Monatsbl Augenh*. 1972;161:604-11.
  19. Etzine S. Corneal thinning syndrome: Keratoleptynsis. *Ophthalmologica*. 1969;157(4):263-7.
  20. Varley GA, Macsai MS, Krachmer JH. The results of penetrating keratoplasty for pellucid marginal corneal degeneration. *Am J Ophthalmol*. 1990;110:149-52.
  21. Kayazawa F, Nishimura K, Kodama Y, Tsuji T, Itoi M. Keratoconus with pellucid marginal corneal degeneration. *Arch Ophthalmol*. 1984;102:895-6.
  22. Karabatsas CH, Cook SD. Topographic analysis in pellucid marginal corneal degeneration and keratoglobus. *Eye (Lond)*. 1996;10(Pt 4):451-5.
  23. Fogla R, Rao SK, Padmanabhan P. Keratectasia in 2 cases with pellucid marginal corneal degeneration after laser in situ keratomileusis. *J Cataract Refract Surg*. 2003;29(4):788-91.
  24. Randleman JB. Post-laser in-situ keratomileusis ectasia: current understanding and future directions. *Curr Opin Ophthalmol*. 2006;17(4):406-12.
  25. Randleman JB, Russell B, Ward MA, Thompson KP, Stulting RD. Risk factors and prognosis for corneal ectasia after LASIK. *Ophthalmology*. 2003;110(2):267-75.
  26. Ambrosio Jr R, Klyce SD, Wilson SE. Corneal topographic and pachymetric screening of keratorefractive patients. *J Refract Surg*. 2003;19(1):24-9.
  27. Poulighen Y, Chauvaud D, Lacombe E, Amiet F, Savoldelli M. Degenerescence pellucide marginale de la cornee ou keratocone marginale. *J Francais D'ophthalmol*. 1980;3(2):109-14.
  28. Rodrigues MM, Newsome DA, Krachmer JH, Eiferman RA. Pellucid marginal corneal degeneration: A clinicopathologic study of two cases. *Exp Eye Res*. 1981;33(3):277-88.
  29. Feder RS, Kshetry P. Noninflammatory ectatic disorders. In: Krachmer JH, Mannis MJ, Holland EJ, editors. *Cornea – fundamentals, diagnosis and management*. 2<sup>nd</sup> Ed. London: Elsevier Inc.; 2005. p. 955-74.
  30. Parker D, McDonnell P, Barraquer J, Green W. Pellucid marginal corneal degeneration. *Cornea*. 1986;5:115-23.
  31. Tzelikis P, Cohen EJ, Rapuano C, Hammersmith K, Laibson PR. Management of pellucid marginal corneal degeneration. *Cornea*. 2005;24(5):555-60.
  32. Kompella VB, Aasuri MK, Rao GN. Management of pellucid marginal corneal degeneration with rigid gas permeable contact lenses. *CLAO J*. 2002;28(3):140-5.
  33. Santo R, Beehara SJ, Kara-Jose N. Corneal topography in asymptomatic family members of a patient with pellucid marginal degeneration. *Am J Ophthalmol*. 1999;127(2):205-7.
  34. Stankovic I, Stankovic M. Ein Beitray zur kenntnis des keratotorus. *Klin Monatsbl Augenh*. 1966;148:873-80.
  35. Taglia DP, Sugar J. Superior pellucid marginal corneal degeneration with hydrops. *Arch Ophthalmol*. 1997;115(2):274-5.
  36. Horodenski J. Pellucid marginal corneal degeneration. *Klinika Oczna*. 1978;48:167-8.
  37. Liu J, Leach N, Bergmanson J. Reverse-geometry gas-permeable lens design for pellucid marginal degeneration. *Eye Cont Lens*. 2005;31(3):127-9.
  38. Sii F, Lee GA, Sanfilippo P, Stephensen DC. Pellucid marginal degeneration and scleroderma. *Clin Exp Optom*. 2004;87(3):180-4.
  39. Jain V, Nair AG, Jain-Mhatre K, Shome D. Pellucid marginal corneal disease in a case of atopic keratoconjunctivitis. *Ocul Immunol Inflamm*. 2010;18(3):187-9.
  40. Seiler T, Quurke AW. Iatrogenic keratectasia after LASIK in a case of forme fruste keratoconus. *J Cataract Refract Surg*. 1998;24(7):1007-9.
  41. Rodriguez-Prats J, Galal A, Garcia-Lledo M, De La Hoz F, Alió JL. Intracorneal rings for the correction of pellucid marginal degeneration. *J Cataract Refract Surg*. 2003;29:1421-4.
  42. Ambrosio RJ, Wilson SE. Early pellucid marginal corneal degeneration: Case reports of two refractive surgery candidates. *Cornea*. 2002;21(1):114-7.
  43. Walker RN, Khachikian SS, Belin MW. Scheimpflug photographic diagnosis of pellucid marginal degeneration. *Cornea*. 2008;27(8):963-6.
  44. Moshirfar M, Edmonds NJ, Behunin LN, Christiansen MS. Current options in the management of Pellucid Marginal Degeneration. *J Refract Surg*. 2014;30(7):474-85.
  45. Maguire LJ, Klyce SD, McDonald MB, Kaufman HE. Corneal topography of pellucid marginal degeneration. *Ophthalmology*. 1987;94(5):519-24.
  46. Gruenauer-Kloevekorn C, Fischer U, Kloevekorn-Norgall K, Duncker GI. Pellucid marginal corneal degeneration: Evaluation of the corneal surface and contact lens fitting. *Br J Ophthalmol*. 2006;90:318-23.
  47. Tang M, Shekhar R, Miranda D, Huang D. Characteristics of keratoconus and pellucid marginal degeneration in mean curvature maps. *Am J Ophthalmol*. 2005;140(6):993-1001.
  48. Lee BW, Jurkunas UV, Harissi-Dagher M, Poothullil AM, Tobaigy FM, Azar DT. Ectatic disorders associated with a claw-shaped pattern on corneal topography. *Am J Ophthalmol*. 2007;144:154-6.
  49. Carter JB, Jones DB, Wilhelmus KR. Acute hydrops in pellucid marginal corneal degeneration. *Am J Ophthalmol*. 1989;107(2):167-70.
  50. Grewal S, Laibson PR, Cohen EJ, Rapuano CJ. Acute hydrops in the corneal ectasias: associated factors and outcomes. *Trans Am Ophthalmol Soc*. 1999;97:187-98, discussion 198-203.
  51. Akpek EK, Altan-Yaycioglu R, Gottsch JD, Stark WJ. Spontaneous corneal perforation in a patient with unusual unilateral pellucid marginal degeneration. *J Cataract Refract Surg*. 2001;27(10):1698-700.
  52. Lucarelli MJ, Gendelman DS, Talamo JH. Hydrops and spontaneous perforation in pellucid marginal corneal degeneration. *Cornea*. 1997;16(2):232-4.
  53. Forooghian F, Assaad D, Dixon WS. Successful conservative management of hydrops with perforation in pellucid marginal degeneration. *Can J Ophthalmol*. 2006;41(1):74-7.
  54. Lee WB, O'Halloran HS, Grossniklaus HE. Pellucid marginal degeneration and bilateral corneal perforation: case report and review of the literature. *Eye Cont Lens*. 2008;34(4):229-33.
  55. Millar MJ, Maloof A. Deep lamellar keratoplasty for pellucid marginal degeneration: Review of management options for corneal perforation. *Cornea*. 2008;27(8):953-6.
  56. Jeng BH, Aldave AJ, McLeod SD. Spontaneous corneal hydrops and

- perforation in both eyes of a patient with pellucid marginal degeneration. *Cornea*. 2003;22(7):705-6.
57. Orlin SE, Sulewski ME. Spontaneous corneal perforation in pellucid marginal degeneration. *CLAO J*. 1998;24(3):186-7.
  58. Aldave AJ, Mabon M, Hollander DA, McLeod SD, Spencer WH, Abbott RL. Spontaneous corneal hydrops and perforation in keratoconus and pellucid marginal degeneration. *Cornea*. 2003;22(2):169-74.
  59. Symes RJ, Catt CJ, Sa-ngiampornpanit T, Males JJ. Corneal perforation associated with pellucid marginal degeneration and treatment with crescentic lamellar keratoplasty: Two case reports. *Cornea*. 2007;26(5):625-8.
  60. Gharebaghi D, Fallahi B, Javadzadeh A, Amiraslanzadeh G. Spontaneous corneal hydrops and perforation in pellucid marginal degeneration: A case report. *J Ophthal Vis Res*. 2009;4(3):174-6.
  61. Kymionis GD, Aslanides IM, Siganos CS, Pallikaris IG. Intacs for early pellucid marginal degeneration. *J Cataract Refract Surg*. 2004;30(1):230-3.
  62. Mularoni A, Torreggiani A, di Biase A, Laffi GL, Tassinari G. Conservative treatment of early and moderate pellucid marginal degeneration: A new refractive approach with intracorneal rings. *Ophthalmology*. 2005;112(4):660-6.
  63. Javadi MA, Karimian F, Hosseinzadeh A, Noroozizadeh HM, Sa'eedifar MR, Rabie HM. Lamellar crescentic resection for pellucid marginal corneal degeneration. *J Refract Surg*. 2004;20:162-5.
  64. Raizada K, Sridhar MS. Nomogram for spherical RGP contact lens fitting in patients with Pellucid Marginal Corneal Degeneration (PMCD). *Eye Cont Lens*. 2003;29(3):168-72.
  65. Rasheed K, Rabinowitz YS. Surgical treatment of advanced pellucid marginal degeneration. *Ophthalmology*. 2000;107(10):1836-40.
  66. Rabinowitz YS. Keratoconus. *Surv Ophthalmol*. 1998;42(4):297-319.
  67. Wilson SE, Lin DTC, Klyce SD. Corneal topography of keratoconus. *Cornea*. 1991;10(1):2-8.
  68. Rabinowitz Y, McDonnell P. Computer-assisted corneal topography in keratoconus. *Refract Corneal Surg*. 1989;5(6):400-8.
  69. Lindsay R. Pellucid marginal degeneration. *Clin Exp Optom*. 1993;76(6):219-21.
  70. Verrey F. Keratoglobus aigu. *Ophthalmologica*. 1947;114:284-8.
  71. Velazquez A, Kim T. Developmental corneal anomalies of size and shape. In: Krachmer JH, Mannis MJ, Holland EJ, editors. *Cornea – fundamentals, diagnosis and management*. 2<sup>nd</sup> Ed. London: Elsevier Inc.; 2005. p.727-38.
  72. Cameron JA. Keratoglobus. *Cornea*. 1993;12:124-30.
  73. Sangwan VS, Zafirakis P, Foster CS. Mooren's ulcer: Current concepts in management. *Indian J Ophthalmol*. 1997;45(1):7-17.
  74. Hill JC, Potter P. Treatment of Mooren's ulcer with cyclosporin A: Report of three cases. *Br J Ophthalmol*. 1987;71:11-5.
  75. Yang L, Xiao J, Wang J, Zhang H. Clinical characteristics and risk factors of recurrent Mooren's Ulcer. *J Ophthalmol*. 2017;2017:8978527.
  76. Srinivasan M, Zegans ME, Zelefsky JR, Kundu A, Lietman T, Whitcher JP, et al. Clinical characteristics of Mooren's ulcer in South India. *Br J Ophthalmol*. 2007;91(5):570-5.
  77. Wilson SE, Lee WM, Murakami C, Weng J, Moninger GA. Mooren's corneal ulcer and hepatitis virus infection. *N Engl J Med*. 1993;329(1):62.
  78. Wilson SE, Lee WM, Murakami C, Weng J, Moninger GA. Mooren-type hepatitis C virus-associated corneal ulceration. *Ophthalmology*. 1994;101(4):736-45.
  79. Moazami G, Auran JD, Florakis GJ, Wilson SE, Srinivasan DB. Interferon treatment of Mooren's ulcers associated with hepatitis C. *Am J Ophthalmol*. 1995;119(3):365-6.
  80. Pluznik D, Butrus SI. Hepatitis C-associated peripheral corneal ulceration. Rapid response to intravenous steroids. *Cornea*. 2001;20(8):888-9.
  81. Kafkala C, Choi J, Zafirakis P, Baltatzis S, Livir-Rallatos C, Rojas B, et al. Mooren ulcer: An immunopathologic study. *Cornea*. 2006;25(6):667-73.
  82. Tandon R, Chawla B, Verma K, Sharma N, Titiyal JS. Outcome of treatment of mooren ulcer with topical cyclosporine a 2%. *Cornea*. 2008;27(8):859-61.
  83. Tsoumani A, Theopistos V, Katsanos K, Asproudis I, Tsianos EV. Treatment and non-treatment related ocular manifestations in patients with chronic hepatitis B or C. *Eur Rev Med Pharmacol Sci*. 2013;17(8):1123-31.
  84. Aaltonen V, Alavesa A, Pirilä L, Vesti E, Al-Juhaish M. Case report: Bilateral Mooren ulcer in association with hepatitis C. *BMC Ophthalmol*. 2017;6;17(1):239.
  85. Chow CYC, Foster CS. Mooren's ulcer. *Int Ophthalmol Clin* 1996;36(1):1-13.
  86. Ding Y, Murri MS, Birdsong CO, Ronquillo Y, Morshifar M. Terrien marginal degeneration. *Surv Ophthalmol*. 2019;64(2):162-174.
  87. Forstot SL. Marginal corneal degenerations. *Int Ophthalmol Clin*. 1984;24:93-106.
  88. Galvis V, Tello A, Niño AC, Larrea J. Terrien marginal degeneration: Clinical characteristics and outcomes. *Am J Ophthalmol*. 2016;164:151-2.
  89. Golubovic S. [Terrien's marginal corneal degeneration]. *Srp Arh Celok Lek*. 1994;122(3-4):110-2.
  90. Goldman KN, Kaufman HE. Atypical pterygium. A clinical feature of Terrien's marginal degeneration. *Arch Ophthalmol*. 1978;96(6):1027-29.
  91. Chan TA, Ulate R, Goldich Y, Rootman SD, Chan CC. Terrien marginal degeneration: Clinical characteristics and outcomes. *Am J Ophthalmol*. 2015;160(5):867-72.
  92. Nirankari VS, Kelman SE, Richards RD. Central cornea involvement in Terrien's degeneration. *Ophthal Surg*. 1983;14(3):245-7.
  93. Suveges J, Leval G, Alberth B. Pathology of Terrien's disease. Histochemical and electron microscopic study. *Am J Ophthalmol*. 1972;74(6):1191-200.
  94. Wilson SE, Lin DT, Klyce SD, Inslers MS. Terrien's marginal degeneration: Corneal topography. *Refract Corneal Surg*. 1990;6(1):15-20.
  95. Binder PS, Zavala EY, Stainer GA. Noninfectious peripheral corneal ulceration: Mooren's ulcer or Terrien's marginal degeneration? *Ann Ophthalmol*. 1982;14(5):425-6, 428-9, 432-5.
  96. Austin P, Brown SI. Inflammatory Terrien's marginal corneal disease. *Am J Ophthalmol*. 1981;92:189-92.
  97. Vejdani AH, Khakshoor H, McCaughey MV, Moshirfar M. Partial and total Descemet's detachments in a patient with severe Terrien's marginal degeneration and juvenile idiopathic arthritis. *Case Rep Ophthalmol Med*. 2014;2014:279491.
  98. Romanchuk KG, Hamilton WK, Braig RF. Terrien's marginal degeneration with corneal cyst. *Cornea*. 1990;9(1):86-7.
  99. Zarei-Ghanavati S, Javadi M, Yazdani S. Bilateral Terrien's marginal degeneration and posterior polymorphous dystrophy in a patient with rheumatoid arthritis. *J Ophthalmic Vis Res*. 2012;7(1):60-3.
  100. Shimazaki J, Yang HY, Shimmura S, Tsubota K. Terrien's marginal degeneration associated with erythema elevatum diutinum. *Cornea*. 1998;17(3):342-4.
  101. Romero-Jimenez M, Santodomingo-Rubido J, Wolffsohn JS. Keratoconus: A review. *Cont Lens Ant Eye*. 2010;33(4):157-66;quiz 205.
  102. Tzelikis P, Cohen EJ, Rapuano C, Hammersmith K, Laibson PR.

- Management of pellucid marginal corneal degeneration. *Cornea*. 2005;24(5):555-60.
103. Mahadevan R, Amudhaolia A, Valarmathi A. Retrospective study of contact lens fitting in pellucid marginal degeneration. *Eye Cont Lens*. 2008;34(4):207-10.
104. Astin CL. The long-term use of the softperm lens on pellucid marginal corneal degeneration. *CLAO J*. 1994;20(4):258-60.
105. Oriowo O, Briggs S. Contact lens management of pellucid marginal corneal degeneration in a Saudi Arabia teaching hospital. *Int Cont Lens Clin*. 1994;21(7-8):147-50.
106. Scheid T, Wetcher SP. SoftPerm contact lens fitting for a case of pellucid marginal degeneration. *Int Cont Lens Clin*. 1990;17(11-12):296-9.
107. Abdalla YF, Elsahn AF, Hammersmith KM, Cohen EJ. SynergEyes lenses for keratoconus. *Cornea*. 2010;29(1):5-8.
108. Nau AC. A comparison of Synergeyes versus traditional rigid gas permeable lens designs for patients with irregular corneas. *Eye Cont Lens*. 2008;34(4):198-200.
109. Maguen E, Martinez M, Rosner IR, Caroline P, Macy J, Nesburn AB. The use of Saturn II lenses in keratoconus. *CLAO J*. 1991;17(1):41-3.
110. McMahon TT, Zadnik K. Twenty-five years of contact lenses: The impact on the cornea and ophthalmic practice. *Cornea*. 2000;19(5):730-40.
111. Maguen E, Caroline P, Rosner IR, Macy JI, Nesburn AB. The use of the SoftPerm lens for the correction of irregular astigmatism. *CLAO J*. 1992;18(3):173-6.
112. Chung CW, Santim R, Heng WJ, Cohen EJ. Use of SoftPerm contact lenses when rigid gas permeable lenses fail. *CLAO J*. 2001;27(4):202-8.
113. Ozbek Z, Cohen EJ. Use of intralimbal rigid gas-permeable lenses for pellucid marginal degeneration, keratoconus, and after penetrating keratoplasty. *Eye Cont Lens*. 2006;32:33-6.
114. Dominguez CE, Shah A, Weissman BA. Bitoric gas-permeable contact lens application in pellucid marginal corneal degeneration. *Eye Cont Lens*. 2005;31(5):241-3.
115. Kastl PR, Kirby RG. Bitoric rigid gas permeable lens fitting in highly astigmatic patients. *Eye Cont Lens*. 1987;13:215-6.
116. Stalboerger GM. Poster 7: Scleral lenses in the management of pellucid marginal corneal degeneration. *J Am Optom Assoc*. 2008;79(6):302.
117. Visser ES, Visser R, van Lier HJ, Otten HM. Modern scleral lenses part I: Clinical features. *Eye Cont Lens*. 2007;33(1):13-20.
118. Pullum KW, Buckley RJ. A study of 530 patients referred for rigid gas permeable scleral contact lens assessment. *Cornea*. 1997;16(6):612-22.
119. Tan DT, Pullum KW, Buckley RJ. Medical applications of scleral contact lenses: Gas-permeable scleral contact lenses. *Cornea*. 1995;14(2):121-9.
120. Nosé W, Neves RA, Burris TE, Schanzlin DJ, Belfort Júnior R. Intrastromal corneal ring: 12-month sighted myopic eyes. *J Refract Surg*. 1996;12(1):20-28.
121. Anjali K, Pathak, Antonio Jaime Villarreal Gonzalez, Humeyra Karacal. ICRS: Corneal biomechanics effects. American Academy of Ophthalmology. 2020.
122. Colin J, Cochener B, Savary G, Malet F. Correcting keratoconus with intracorneal rings. *J Cataract Refract Surg*. 2000;26(8):1117-22.
123. Alió J, Salem T, Artola A, Osman A. Intracorneal rings to correct corneal ectasia after laser in situ keratomileusis. *J Cataract Refract Surg*. 2002;28(9):1568-74.
124. Kymionis GD, Siganos CS, Tsiklis NS, Anastasakis A, Yoo SH, Pallikaris AI, et al. Long-term follow-up of Intacs in keratoconus. *Am J Ophthalmol*. 2007;143(2):236-44.
125. Shetty R, Kurian M, Anand D, Mhaske P, Narayana KM, Shetty BK. Intacs in advanced keratoconus. *Cornea*. 2008;27(9):1022-9.
126. Colin J, Cochener B, Savary G, Malet F, Holmes-Higgin D. INTACS inserts for treating keratoconus: One-year results. *Ophthalmology*. 2001;108(8):1409-14.
127. Ertan A, Bahadir M. Intrastromal ring segment insertion using a femtosecond laser to correct pellucid marginal corneal degeneration. *J Cataract Refract Surg*. 2006;32(10):1710-6.
128. Barbara A, Shehadeh-Masha'our R, Zvi F, Garzozzi HJ. Management of pellucid marginal degeneration with intracorneal ring segments. *J Refract Surg*. 2005;21(3):296-8.
129. Pinero DP, Alio JL. Intracorneal ring segments in ectatic corneal disease: A review. *Clin Exp Ophthalmol*. 2010;38(2):154-67.
130. Kubaloglu A, Sari ES, Cinar Y, Koytak A, Kurnaz E, Piñero DP, et al. A single 210-degree arc length intrastromal corneal ring implantation for the management of pellucid marginal corneal degeneration. *Am J Ophthalmol*. 2010;150(2):185-92.
131. Ertan A, Bahadir M. Management of superior pellucid marginal degeneration with a single intracorneal ring segment using femtosecond laser. *J Refract Surg*. 2007;23(2):205-8.
132. Alió JL, Shabayek MH, Artola A. Intracorneal ring segments for keratoconus correction: Long-term follow-up. *J Cataract Refract Surg*. 2006;32(6):978-85.
133. Kugler LJ, Hill S, Sztipanovits D, Boerman H, Swartz TS, Wang MX. Corneal melt of incisions overlying corneal ring segments: Case series and literature review. *Cornea*. 2011;30(9):968-71.
134. Snibson GR. Collagen cross-linking: A new treatment paradigm in corneal disease- a review. *Clin Exp Ophthalmol*. 2010;38(2):141-53.
135. Stojanovic A, Chen X, Jin N, Zhang T, Stojanovic F, Raeder S, et al. Safety and efficacy of epithelium-on corneal collagen cross-linking using a multifactorial approach to achieve proper stromal riboflavin saturation. *J Ophthalmol*. 2012;2012:498435.
136. Wollensak G, Spoerl E, Seiler T. Riboflavin/Ultraviolet-A-induced collagen crosslinking for the treatment of keratoconus. *Am J Ophthalmol*. 2003;135(5):620-7.
137. Kanellopoulos AJ. Long term results of a prospective randomized bilateral eye comparison trial of higher fluence, shorter duration ultraviolet A radiation, and riboflavin collagen cross linking for progressive keratoconus. *Clin Ophthalmol*. 2012;6:97-101.
138. Spadea L. Corneal collagen cross-linking with riboflavin and UV-A irradiation in pellucid marginal degeneration. *J Refract Surg*. 2010;26(5):375-7.
139. Kymionis GD, Karavitaki AE, Kounis GA, Portaliou DM, Yoo SH, Pallikaris IG. Management of pellucid marginal corneal degeneration with simultaneous customized photorefractive keratectomy and collagen crosslinking. *J Cataract Refract Surg*. 2009;35(7):1298-301.
140. Kymionis GD, Grentzelos MA, Portaliou DM, Karavitaki AE, Krasia MS, Dranidis GK, et al. Photorefractive keratectomy followed by same-day corneal collagen crosslinking after intrastromal corneal ring segment implantation for pellucid marginal degeneration. *J Cataract Refract Surg*. 2010;36(10):1783-5.
141. Kymionis GD, Voulgari N, Samutelela E, Kontadakis G, Tabibian D. Combined corneal wedge resection and corneal cross-linking for pellucid marginal degeneration: A first report. *Ther Clin Risk Manag*. 2019;12;15:1319-24.
142. Raiskup-Wolf F, Hoyer A, Spoerl E, Pillunat LE. Collagen crosslinking with riboflavin and ultraviolet-A light in keratoconus: Long-term results. *J Cataract Refract Surg*. 2008;34(5):796-801.



143. Al-Torbak AA. Deep anterior lamellar keratoplasty for pellucid marginal degeneration. *Saudi J Ophthalmol.* 2013;27(1):11-4.
144. Al-Torbak AA, Al-Motowa S, Al-Assiri A, Al-Kharashi S, Al-Shahwan S, Al-Mezaine H, et al. Deep anterior lamellar keratoplasty for keratoconus. *Cornea.* 2006;25(4):408-12.
145. Keane M, Coster D, Ziaei M, Williams K. Deep anterior lamellar keratoplasty versus penetrating keratoplasty for treating keratoconus. *Cochrane Database Syst Rev.* 2014;22(7):CD009700.
146. Liu H, Chen Y, Wang P, Bing Li, Wang W, Su Y, et al. Efficacy and safety of deep anterior lamellar keratoplasty vs. penetrating keratoplasty for keratoconus: A meta-analysis. *PLoS One.* 2015;29;10(1):e0113332.
147. Henein C, Nanavaty AM. Systematic review comparing penetrating keratoplasty and deep anterior lamellar keratoplasty for management of keratoconus. *Cont Lens Anterior Eye.* 2017;40(1):3-14.
148. Kanski J. *Clinical Ophthalmology: A systematic approach.* 8<sup>th</sup> ed. 2015. Elsevier.
149. Reinhart WJ, Musch DC, Jacobs DS, Lee WB, Kaufman SC, Shtein RM. Deep anterior lamellar keratoplasty as an alternative to penetrating keratoplasty: A report by the American Academy of Ophthalmology. *Ophthalmology.* 2011;118(1):209-18.
150. Genc S, Sucu EM, Çakmak S, Yildirim Y, Yıldız KB, Ağca A. Deep anterior lamellar keratoplasty techniques; predescemetic versus big bubble: Anterior segment optical coherence tomography study. *J Fr Ophtalmol.* 2020;43(3):222-7.
151. Feizi S, Javadi AM, Jamali H, Mirbabaee F. Deep anterior lamellar keratoplasty in patients with keratoconus: Big-bubble technique. *Cornea.* 2010;29(2):177-82.
152. Buzzonetti L, Petrocelli G, Valente P. Femtosecond laser and big-bubble deep anterior lamellar keratoplasty: A new chance. *J Ophthalmol.* 2012;2012:264590.
153. Kodavoor KS, Deb B, Ramamurthy D. Outcome of deep anterior lamellar keratoplasty patients with intraoperative Descemet's membrane perforation: A retrospective cross-sectional study. *Indian J Ophthalmol.* 2018;66(11):1574-9.
154. Akpek EK, Altan-Yaycioglu R, Gottsch JD, Stark WJ. Spontaneous corneal perforation in a patient with unusual unilateral pellucid marginal degeneration. *J Cataract Refract Surg.* 2001;27(10):1698-700.
155. Schanzlin DJ, Sarno EM, Robin JB. Crescentic lamellar keratoplasty for pellucid marginal degeneration. *Am J Ophthalmol.* 1983;96(2):253-4.
156. Schnitzer JI. Crescentic lamellar keratoplasty for pellucid marginal degeneration. *Am J Ophthalmol.* 1984;97(2):250-2.
157. Fronterre A, Portesani GP. Epikeratoplasty for pellucid marginal corneal degeneration. *Cornea.* 1991;10(5):450-3.
158. Cameron JA. Results of lamellar crescentic resection for pellucid marginal corneal degeneration. *Am J Ophthalmol.* 1992;113(3):296-302.
159. Maccheron LJ, Daya SM. Wedge resection and lamellar dissection for pellucid marginal degeneration. *Cornea.* 2012;31(6):708-15.
160. Andrade F, Araújo M. Pellucid marginal degeneration: Postponing penetrating keratoplasty for over a decade. *Rev. bras. of talmol.* 2018;77(2).
161. Kaushal S, Jhanji V, Sharma N, Tandon R, Titiyal JS, Vajpayee RB. "Tuck in" Lamellar Keratoplasty (TILK) for corneal ectasias involving corneal periphery. *Br J Ophthalmol.* 2008;92(2):286-90.
162. Vajpayee RB, Bhartiya P, Sharma N. Central lamellar keratoplasty with peripheral intralamellar tuck: A new surgical technique for keratoglobus. *Cornea.* 2002;21(7):657-60.
163. Vajpayee RB, Sharma N, Bhartiya P, Agarwal T, Tandon R, Titiyal JS. Central penetrating keratoplasty with peripheral intrastromal tuck. *Cornea.* 2005;24(8):947-50.
164. Arora R, Manudhane A, Jain P, Goyal LJ. Crescentic tuck in lamellar keratoplasty-A novel technique in a case of advanced pellucid marginal corneal degeneration. *Eye Contact Lens.* 2018;44(Suppl 1):S345-7.
165. Speaker MG, Arentsen JJ, Laibson PR. Long-term survival of large diameter penetrating keratoplasties for keratoconus and pellucid marginal degeneration. *Acta Ophthalmol.* 1989;192:17-9.
166. MacLean H, Robinson LP, Wechsler AW. Long-term results of corneal wedge excision for pellucid marginal degeneration. *Eye (Lond).* 1997;11(Pt 5):613-7.
167. Dubroff S. Pellucid marginal corneal degeneration: Report on corrective surgery. *J Cataract Refract Surg.* 1989;15(1):89-93.
168. Busin M, Kerdraon Y, Scorgia V, Zambianchi L, Matteoni S. Combined wedge resection and beveled penetrating relaxing incisions for the treatment of pellucid marginal corneal degeneration. *Cornea.* 2008;27(5):595-600.
169. Alfonso JF, Palacios A, Montes-Mico R. Myopic phakic STAAR collamer posterior chamber intraocular lenses for keratoconus. *J Refract Surg.* 2008;24(9):867-74.
170. Venter J. Artisan phakic intraocular lens in patients with keratoconus. *J Refract Surg.* 2009;25(9):759-64.
171. Alfonso JF, Fernandez-Vega L, Lisa C, Fernandes P, Gonzalez-Mejome JM, Montes-Mico R. Collagen copolymer toric posterior chamber phakic intraocular lens in eyes with keratoconus. *J Cataract Refract Surg.* 2010;36(6):906-16.
172. Navatany AM, Lake D, Daya MS. Outcomes of pseudophakic toric intraocular lens implantation in keratoconic eyes with cataract. *J Refract Surg.* 2012;28(12):884-90.
173. Camoriano GD, Aman-Ullah M, Purba MK, Sun J, Gimbel HV. Toric collagen copolymer phakic intraocular lens to correct myopic astigmatism in eyes with pellucid marginal degeneration. *J Cataract Refract Surg.* 2012;38(2):256-61.
174. Balestrazzi A, Baiocchi S, Balestrazzi A, Cartocci G, Tosi GM, Martone G, et al. Mini-incision cataract surgery and toric lens implantation for the reduction of high myopic astigmatism in patients with pellucid marginal degeneration. *Eye (Lond).* 2015;29(5):637-42.
175. Stojanovic A, Zhang J, Chen X, Nitter AT, Chen S, Wang Q. Topography-guided transepithelial surface ablation followed by corneal collagen cross-linking performed in a single combined procedure for the treatment of keratoconus and pellucid marginal degeneration. *J Refract Surg.* 2010;26(2):145-52.
176. Tuft SJ, Gregory WM, Buckley RJ. Acute corneal hydrops in keratoconus. *Ophthalmology.* 1994;101(10):1738-44.
177. Maharana KP, Sharma N, Vajpayee BR. Acute corneal hydrops in keratoconus. *Indian J Ophthalmol.* 2013;61(8):461-4.
178. Bhandari V, Ganesh S. Corneal hydrops in pellucid marginal degeneration: A case series. *Case Rep Ophthalmol.* 2015;13(6):191-9.
179. Motlagh FB, Mortazavi ZS. Acute corneal hydrops following post-keratoplasty suture removal in pellucid marginal degeneration. *J Ophthalmic Vis Res.* 2013;8(2):172-4.
180. Jhanji V, Young AL, Mehta JS, Sharma N, Agarwal T, Vajpayee RB. Management of corneal perforation. *Surv Ophthalmol.* 2011;56(6):522-38.