



Conservatively Treated Bacterial Tricuspid Valve Endocarditis Complicated with Fungal Re-Infection, Tricuspid Valve Destruction, and Septic Pulmonary Emboli Necessitating Surgical Intervention

Saroj Pani^{1*}, Joanne Barlin¹, Mikhail Torosoff², Sridhar R Musuku¹ and Adanna Akujuo³

¹Department of Anesthesiology, Albany Medical Center, USA

²Department of Cardiology, Albany Medical Center, USA

³Department of Cardiothoracic Surgery, Albany Medical Center, USA

Abstract

Here we present an unusual case of an endocarditis in an intravenous drug user. While convalescing from conservatively treated bacterial tricuspid valve endocarditis, the patient developed Candidal tricuspid valve endocarditis with severe valvular regurgitation and multiple pulmonary septic emboli, necessitating life-saving surgical treatment. This case illustrates severe complications of Candidal Infective Endocarditis (IE) in a vulnerable patient with prior history of endocarditis and continued IVDA. Diagnosis of Candidal infection requires a high index of suspicion. The clinical presentation may be similar, but the disease can be more devastating. The presented case increases awareness of fungal IE, illustrates complexity of treatment and demonstrates importance of multidisciplinary approach to the management this potentially lethal condition.

Keywords: Tricuspid endocarditis; *Candida albicans*; IE

OPEN ACCESS

*Correspondence:

Saroj Pani, Department of Anesthesiology, Albany Medical Center, 43, New Scotland Avenue, 12208, Albany NY, USA, Tel:518-262-4305; Fax:518-262-2671; E-mail: Panis@amc.edu@amc.edu

Received Date: 21 Feb 2019

Accepted Date: 26 Mar 2019

Published Date: 28 Mar 2019

Citation:

Pani S, Barlin J, Torosoff M, Musuku SR, Akujuo A. Conservatively Treated Bacterial Tricuspid Valve Endocarditis Complicated with Fungal Re-Infection, Tricuspid Valve Destruction, and Septic Pulmonary Emboli Necessitating Surgical Intervention. *Ann Clin Anesth Res.* 2019; 3(1): 1019.

Copyright © 2019 Saroj Pani. This is an open access article distributed under the Creative Commons Attribution License, which permits unrestricted use, distribution, and reproduction in any medium, provided the original work is properly cited.

Introduction

We present an unusual case of an endocarditis in an intravenous drug user. While convalescing from conservatively treated bacterial tricuspid valve endocarditis, the patient developed Candidal tricuspid valve endocarditis with severe valvular regurgitation and multiple pulmonary septic emboli, necessitating life-saving surgical treatment. Candidal Infective Endocarditis (IE) historically accounts for 1% to 2% of all IE cases. In addition to antibiotic treatment, surgery is performed in IE complicated with persistent infection, valvular dysfunction, and/or heart failure unresponsive to optimal medical management. With opioid epidemic, growing number of IE patients undergo surgical treatment, however, the overall rarity of Candidal IE makes it challenging to prove that surgical therapy improves outcomes in fungal IE [1-3]. Despite advances in antifungal therapy and surgical techniques, in-hospital mortality in Candidal IE exceeds 33% and 1-year mortality approaches 66%. The presented case increases awareness of fungal IE, illustrates complexity of treatment and demonstrates importance of multidisciplinary approach to the management this potentially lethal condition.

Case Presentation

A 24-year-old Caucasian female with history of Intra Venous Drug Abuse (IVDA) and hepatitis C presented with fever and shortness of breath three weeks after the completion of a 6-week vancomycin course for tricuspid valve Methicillin Susceptible *Staphylococcus aureus* (MSSA) endocarditis. After completion of the antibiotic course, she resumed IVDA and shortly thereafter developed a high-grade fever, shortness of breath, back pain, and general malaise necessitating readmission. The blood culture at that time grew *Candida albicans*. CT scan performed for assessment of shortness of breath revealed large right main pulmonary artery thrombus and multiple bilateral lung cavitary lesions. Trans Thoracic Echocardiogram (TTE) was suggestive for tricuspid valve vegetation (Figure 1, Panel A), which was subsequently confirmed on the Trans Esophageal Echocardiogram (TEE), also revealing severe Tricuspid Regurgitation (TR), and Right Ventricular (RV) dilation with systolic dysfunction (Figure 1, Panel B). Treatment with enoxaparin,

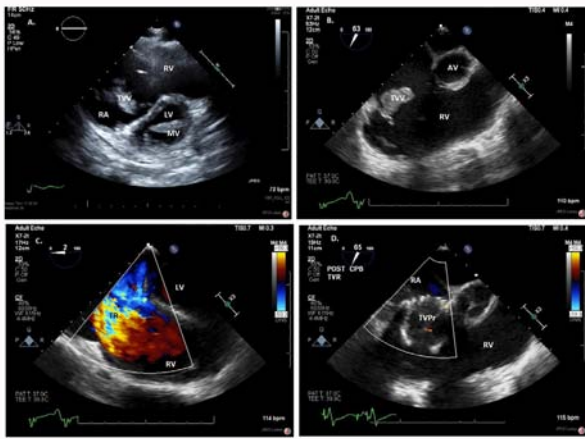


Figure 1: Panel A: Pre-operative transthoracic echocardiogram revealed dilated Right Ventricle (RV) and Right Atrium (RA) with large TV Vegetation (TVV). Left Ventricle (LV) and Mitral Valve (MV) were not affected. **Panel B:** Intra-operative trans-esophageal echocardiogram confirmed very large TV Vegetation (TVV) and dilated Right Ventricle (RV). **Panel C:** Severe TV Regurgitation (TR) was noted intraoperatively. **Panel D:** Infected TV was replaced with tissue Mosaic tricuspid valve prosthesis (TVPr) without a para valvular leak, regurgitation, or stenosis.

piperacillin/tazobactam, and micafungin was administered, and the patient was referred for Tricuspid Valve Replacement (TVR). The patient was brought to the operating room for TVR. She was anxious, cachectic, with significant JVD and hepatomegaly. General anesthesia was induced using intravenous midazolam, propofol, sufentanyl and a muscle relaxant rocuronium. Anesthesia was maintained using isoflurane. Hemodynamic monitoring included a FloTrac system (Edwards's Life sciences®). A TEE probe was placed, which revealed a persistent large tricuspid valve vegetation (Figure 1, Panel B) on the posterior tricuspid valve leaflet with severe TR (Figure 1, Panel C) and hepatic vein flow reversal, pulmonary artery thrombus, and dilated RV with normal ejection fraction. After full heparinization the aorta was cannulated followed by bicaval cannulation completing the Cardio Pulmonary Bypass (CPB) circuit. An ACT >400 s was achieved and CPB was instituted. Umbilical tapes were placed around the Superior Vena Cava (SVC) and Inferior Vena Cava (IVC) and both cava snared. The procedure was accomplished without arresting the heart. The tricuspid valve and vegetation were excised, with meticulous care taken to remove all infected tissue. Given the amount of tissue destruction, an adequate repair was not possible, and the tricuspid valve was replaced with 33 mm tissue Mosaic valve prosthesis (Medtronic®). Post-procedure, global RV ejection fraction was found to be decreased, the prosthetic valve function was normal without a para valvular leak, regurgitation, or stenosis (Figure 1, Panel D), and the hepatic vein flow reversal was no longer present. The patient was weaned off CPB on epinephrine, milrinone, and phenylephrine. She was extubated on post-operative day 1. Her post-operative course was complicated by pericardial tamponade requiring a pericardial window on the 7th post-operative day and completes heart block necessitating placement of a permanent pacemaker. Heart failure symptoms had resolved. Two weeks after her surgery, she was discharged to rehabilitation with an outpatient course of antibiotics. Pathology confirmed acute and chronic inflammation, abscess formation and necrosis consistent with fungal endocarditis.

Discussion

Despite improvements in diagnosis and management, IE remains

a high-risk condition. The primary causes of IE are IV drug use, right side cardiac device implantation such as pacemaker leads, and defibrillator leads, central venous catheterization including vascular access for dialysis and repaired congenital defects. Right sided infective endocarditis is less common than left sided infective endocarditis, with 90% of right sided IE involving tricuspid valve [4]. Infective endocarditis is generally more common in young males, with the most predominant etiological organism being *Staphylococcus aureus*, followed by *Streptococcus* species [2]. Most IE cases are successfully treated with antibiotics, but 5 to 16% of patients eventually require surgical intervention. Acquired nosocomial infections are seen in older population [4]. The incidence of right-sided IE has been steadily increasing over the last 2 decades [5,6]. Fungal IE is a rare disease with poor prognosis. The prevalence of fungal infective endocarditis is 1% to 10% with mortality greater than 50%. Fungal IE may affect 4 major sites: native valves, prosthetic valves, endocardial surfaces and indwelling cardiac devices. Specifically, the rate of fungal infection in cardiovascular devices -prosthetic valves (2% to 10%), pacemakers and implantable cardioverter defibrillators (4.5%), and ventricular assist devices (35% to 39%) [7]. The prevalence of tricuspid valve endocarditis requiring surgical intervention is on the rise, with a five-fold increase in surgical volume for in a span of 5 years, most likely due to the opioid epidemic [6]. Microbiologically, *Candida species* are isolated in 53% to 68% of fungal IE, with *Candida albicans* being the most common. *Non-albicans* etiologies include *Candida parapsilosis*, *Glabrata*, *Tropicalis aspergillus*, and yet rarer are *Coccidioides*, *Cryptococcus*, *Histoplasma* and *Blastomyces*. Fungal IE is more prevalent in immunocompromised, intravenous drug abusers, recipient of prolonged antibiotics, parenteral nutrition, prosthetic heart valves or those undergoing reconstructive heart surgery [3,8]. Complications of IE such as septic pulmonary emboli, pulmonary abscess, pleural effusion, empyema can occur. Cardiac complications include tricuspid valve destruction and severe TR, right sided volume overload and right heart failure. Neurological complications include embolic and ischemic strokes, intracranial and subarachnoid hemorrhage and mycotic aneurysms [9]. This may be due to left sided vegetations or paradoxical emboli of the right sided vegetations through a patent *foramen ovale*. The modified Duke criteria are well established for the IE diagnosis [7]. However, there are no specific diagnostic criteria for fungal IE. In fungal IE, early recognition is critical for success of antifungal therapy, but the correct diagnosis is often delayed because fungi are slow growing organisms which require prolonged incubation time for microbiological diagnosis. Furthermore, rare pathogens are sometimes dismissed as contaminants [9]. Patients with fungal IE present with wide range of acuity from mild complaints of fatigue, chest pain, dyspnea, hemoptysis, fever and chills, nausea, vomiting, weakness, weight loss and anorexia to overwhelming sepsis and cardiogenic shock. Examination may reveal new or changing heart murmurs [9,10]. Chest x-ray may show pulmonary infiltrates and pulmonary opacities. In a patient presenting with fever, bacteremia and pulmonary infiltrates, right sided IE should be strongly considered. In this case, TTE and/or TEE studies may show tricuspid valve vegetation and regurgitation [10]. Vegetations may also be attached to the superior vena cava catheter, Eustachian valve, or pulmonic valve prosthesis [7,11]. Antimicrobial therapy is the first line of treatment in fungal IE. Traditional antifungal treatment consists of 6 to 8 weeks course of amphotericin B or an echinocandins (e.g. micafungin, Astellas Pharma®), followed by fluconazole for chronic suppression, because of frequent relapses [10]. Approximately

20% of fungal IE patients have persistent infection, with symptomatic valvular regurgitation, concomitant left sided infection, or recurrent septic pulmonary embolic complications requiring surgery. Indications for surgery are recurrent pulmonary embolism, large >10 mm vegetation, uncontrolled sepsis despite antibiotic regimen and intractable heart failure. A multi-disciplinary approach is required for management of these critically ill patients. Communication between teams enables effective targeted therapy decision. Extensive septic screens before antibiotics facilitate targeted antimicrobial therapy, which is of paramount importance in the era of increasing antibiotic resistance. Thorough radiological assessment provides global embolic assessment. Infectious disease specialists can recommend appropriate antimicrobial therapy [2,12]. The surgeon in collaboration with cardiologist can determine the best timing for surgical intervention, which often provides invaluable diagnostic tissue sampling for histopathological and microbiological investigations. The timing of surgery is typically within 1 week of diagnosis in patients with native valve endocarditis and within days with prosthetic valve Candida endocarditis. Indication and timing of surgery are less clear for failed medical therapy. Delaying surgery leads to increased rates of hospital death and embolic events. Aggressive surgical intervention in large >10 mm lesions may result in lower operative mortality and decreased risk of embolization [4,13]. Principles of surgery for fungal IE are complete removal of infected tissue and reconstruction of cardiac structures. Earlier intervention may permit more valve repair and improve outcomes. If possible, valve replacement should be avoided. Unfortunately, patients with tricuspid IE usually present with extensive valve destruction requiring valvectomy, complex valve repair or replacement. Valvectomy is better tolerated in young and otherwise healthy patients but can lead to permanent damage to RV, heart failure and death. Tricuspid valve repair, rather than valvectomy or replacement, is recommended for a single leaflet involvement [14]. This enables eradication of infection without implantation of prosthetic material. However, in most cases, valve replacement is needed due to late referral to tertiary center and irreparable valve damage. Once the decision to replace has been made, most patients receive tissue valve prosthesis because of historical poor patient adherence to anticoagulation regimen when mechanical prosthesis is implanted [2,12]. Valve replacement can also be done using a mitral homograft in the tricuspid position. Angiovac system (AngioDynamics®) may be used for vegetation debulking in TV endocarditis, thus reducing the occurrence of septic embolization and enhancing the efficacy of antibiotics in clearance of bloodstream infection [15]. Imaging modalities using a 3D TEE has been used to guide Angio Vac debulking of Tricuspid valve vegetation [16]. Removal of infected pacemaker leads or AICD is also recommended. TV replacement, however, does not address RV dysfunction and cor pulmonale common in patients with septic pulmonary emboli and severe TV regurgitation. Surgical outcomes in fungal IE are significantly affected by co-morbidities and social issues. A retrospective review of 56 patients indicated up to 15% mortality with surgical intervention in isolated native TV IE and worse prognosis in concomitant left sided involvement, likely due to abscess formation [17]. A review of 919 patients enrolled in the STS database demonstrated 7% perioperative mortality in repair or replacement of TV [18]. While TV repair and replacement offer similar long-term survival, valve repair may offer greater freedom from recurrent IE and re-operations as well as freedom from pacemaker and should be the preferred approach for patient with tricuspid valve IE [19]. In a

series of 126 patients, 59% underwent TV replacement with reported 11% 30-day mortality, 5.6% reoperation rate, stroke in 0.8% and renal failure in 8% [6]. Patients with healed TV IE may have decreased complication rates (31.5%) as compared to the patients with active IE (68.5%), and also shortened length of stay and a trend towards decreased mortality [18]. Continued injection drug use carries high risk of re-operation for infective endocarditis [8,20-22].

Conclusion

We present an unusual case of an endocarditis in an intravenous drug user. While convalescing from conservatively treated bacterial tricuspid valve endocarditis, the patient developed Candidal tricuspid valve endocarditis with severe valvular regurgitation and multiple pulmonary septic emboli, necessitating life-saving surgical treatment. This case illustrates severe complications of Candidal IE in a vulnerable patient with prior history of endocarditis and continued IVDA. Her clinical course reveals how medically challenging these cases is. Infectious valve destruction caused severe TV regurgitation and right-sided heart failure. Septic emboli lead to lung abscesses and respiratory failure. Myocardial abscesses and damage to the conduction system resulted in pericardial tamponade and heart block. In the management of these complex patients, intra- and post-operative echocardiography was critical in defining the extent of the valve destruction, securing success of the valve replacement, and identifying postoperative complication of pericardial tamponade. After the surgery, the patient underwent an extended four-week course of micafungin. Although she survived her surgery and was successfully discharged from the hospital, literature suggests 66% 1-year mortality rate despite advances in antifungal therapy and surgical techniques. With her history of IVDA and relapse, the patient is at high risk for future complications and re-infection of prosthetic valve and pacemaker wires. With her large tricuspid valve vegetation, severe TR, pulmonary embolus, and acute right side heart failure, replacement of the valve was the only option and surgical therapy was absolutely necessary. Incidence of IVDA associated endocarditis requiring valvular surgery is increasing and is an emerging public health issue. The five-fold increase in IE surgical volume reported in a span of last 5 years is thought to be due to the opioid epidemic, disproportionately affecting young people and burdening limited health care resources. Further studies are urgently needed to investigate best treatment strategies and establish optimal timing for surgical intervention in this deadly disease. Diagnosis of Candidal infection requires a high index of suspicion. The clinical presentation may be similar, but the disease can be more devastating. Recurrent endocarditis may be etiologically different caused by completely different microorganism as in the present case where a treated bacterial endocarditis was followed by fungal endocarditis. The presented case increases awareness of fungal IE, illustrates complexity of treatment and demonstrates importance of multidisciplinary approach to the management this potentially lethal condition.

References

1. Pasha AK, Lee JZ, Low SW, Desai H, Lee KS, Al Mohajer M. Fungal Endocarditis: Update on Diagnosis and Management. *Am J Med.* 2016;129(10):1037-43.
2. Arnold CJ, Johnson M, Bayer AS, Bradley S, Giannitsioti E, Miró JM, et al. Candida infective endocarditis: an observational cohort study with a focus on therapy. *Antimicrob Agents Chemother.* 2015;59(4):2365-73.
3. Baddley JW, Benjamin DK Jr, Patel M, Miró J, Athan E, Barsic B, et al. Candida infective endocarditis. *Eur J Clin Microbiol Infect Dis.*

- 2008;27(7):519-29.
4. Hussain ST, Witten J, Shrestha NK, Blackstone EH, Pettersson GB. Tricuspid valve endocarditis. *Ann Cardiothorac Surg.* 2017;6(3):255-61.
 5. Moss R, Munt B. Injection drug use and right sided endocarditis. *Heart.* 2003;89(5):577-81.
 6. Wallen TJ, Szeto W, Williams M, Atluri P, Arnaoutakis G, Fults M, et al. Tricuspid valve endocarditis in the era of the opioid epidemic. *J Card Surg.* 2018;33(5):260-4.
 7. Pasha AK, Snyder BA, Zangeneh TT, Thompson JL, Sobonya RE, Abidov A. A distinctly rare case of candida endocarditis involving the bioprosthetic pulmonary and the Eustachian valve diagnosed on 3D transesophageal echocardiography. *Echocardiography.* 2015;32(3):607-9.
 8. Witten JC, Hussain ST, Shrestha NK, Gordon SM, Houghtaling PL, Bakaeen FG, et al. Surgical treatment of right-sided infective endocarditis. *J Thorac Cardiovasc Surg.* 2019;157(4):1418-27.
 9. Mansell J, Goutsoyannis Y, Draz N, Buchanan R. Infective endocarditis due to *Atropobium vaginae*: a rare association between genital infection and endocarditis of the tricuspid valve. *BMJ case Rep.* 2018;225871.
 10. Neely RC, Leacche M, Shah J, Byrne JG. Current readings: Status of surgical treatment for endocarditis. *Semin Thorac Cardiovasc Surg.* 2014;26(1):53-66.
 11. Karabinos IK, Kokladi M, Katritsis D. Fungal Endocarditis of the Superior Vena Cava: The role of Transesophageal Echocardiography. *Hellenic J Cardiol.* 2010;51:538-9.
 12. Byrne JG, Rezai K, Sanchez JA, Bernstein RA, Okum E, Leacche M, et al. Surgical management of endocarditis: the society of thoracic surgeons clinical practice guideline. *Ann Thorac Surg.* 2011;91(6):2012-9.
 13. Kang DH, Kim YJ, Kim SH, Sun BJ, Kim DH, Yun SC, et al. Early surgery versus conventional treatment for infective endocarditis. *N Engl J Med.* 2012;366(26):2466-73.
 14. Carozza A, Renzulli A, De Feo M, Ismeno G, Della Corte A, Dialetto G, et al. Tricuspid repair for infective endocarditis: clinical and echocardiographic results. *Tex Heart Inst J.* 2001;28(2):96-101.
 15. Abubakar H, Rashed A, Subahi A, Yassin AS, Shokr M, Elder M. Angio Vac System Used for Vegetation Debulking in a Patient with Tricuspid Valve Endocarditis: A Case Report and Review of the Literature. *Case Rep Cardiol.* 2017; 2017:1-7.
 16. Dalia AA, Bamira D, Albaghdadi M, Essandoh M, Rosenfield K, Dudzinski D, et al. Four-Dimensional Transesophageal Echocardiography-Guided Angio Vac Debulking of a Tricuspid Valve Vegetation. *J Cardiothorac Vasc Anesth.* 2017;31(5):1713-6.
 17. Dawood MY, Cheema FH, Ghoreishi M, Foster NW, Villanueva RM, Salenger R, et al. Contemporary outcomes of operations for tricuspid valve infective endocarditis. *Ann Thorac Surg.* 2015;99(2):539-46.
 18. Gaca JG, Sheng S, Daneshmand M, Rankin JS, Williams ML, O'Brien SM, et al. Current outcomes for tricuspid valve infective endocarditis surgery in North America. *Ann Thorac Surg.* 2013;96(4):1374-81.
 19. Yanagawa B, Elbatarny M, Verma S, Hill S, Mazine A, Puskas JD, et al. Surgical Management of Tricuspid Valve Infective Endocarditis: A Systematic Review and Meta-Analysis. *Ann Thorac Surg.* 2018;106(3):708-14.
 20. Schranz AJ, Fleischauer A, Chu VH, Wu LT, Rosen DL. Trends in Drug Use-Associated Infective Endocarditis and Heart Valve Surgery, 2007 to 2017: A Study of Statewide Discharge Data. *Ann Intern Med.* 2018;17(1):31-40.
 21. Østergaard L, Valeur N, Bundgaard H, Butt JH, Ihlemann N, Køber L, et al. Temporal changes in infective endocarditis guidelines during the last 12 years: High-level evidence needed. *Am Heart J.* 2017;193:70-5.
 22. Kaygusuz I, Mulazimoglu L, Cerikcioglu N, Toprak A, Oktay A, Korten V. An unusual native tricuspid valve endocarditis caused by *Candida colliculosa*. *Clin Microbiol Infect.* 2003;9(4):319-22.