



Paratesticular Fibrous Pseudotumor: A Case Report

Ilyass Zerda, Amine Saouli*, Abdoulazizi Bilgo, Tarik Karmouni, Khalid El Khader, Abdellatif Koutani and Ahmed IbenAttya Andaloussi

Department of Urology B, CHU Ibn Sina, Mohamed V University, Morocco

Abstract

Background: Paratesticular Fibrous Pseudotumor (PFP) is a rare benign tumor that is not a neoplasm but a reactive fibrous inflammatory hyperplasia that occurs from the vaginal tunica, epididymis or spermatic cord. The diagnosis of this entity is purely histological.

Case Report: We report the case of a 22-year-old patient with no notable history, who presents a left testicular mass discovered by autopalpation, which has gradually increased in size over the past 3 years. On physical examination, a left paratesticular mass is palpated, firm, not hard and painless. Ultrasound revealed the presence of an epididymal mass, scrotal MRI showed well-limited left tissue formation hypointense in T1, T2 and diffusion, which was markedly enhanced after injection of contrast product. The diagnosis of a benign fibrous tumor of the epididymis was retained on histological examination.

Conclusion: Paratesticular fibrous tumors remain a rare entity of benign tumors, radiological exploration does not confirm the benignity of the tumor, and surgical exploration with an extemporaneous examination remains the most suitable attitude followed by excision of the tumor and the tunica vagina.

Keywords: Testis; Tumor; Benign; Fibrous pseudotumor

Abbreviations

PFP: Paratesticular Fibrous Pseudotumor; MRI: Magnetic Resonance Imaging

Background

Paratesticular Fibrous Pseudotumor (PFP) is a rare benign tumor that is not a neoplasm but a reactive fibrous inflammatory hyperplasia. Paratesticular fibrous pseudotumor occurs from intrascrotal tissues, such as the tunica vagina, epididymis, or spermatic cord. The diagnosis of this entity is purely histological. Through this observation exposing us the diagnostic and therapeutic peculiarities of the fibrous pseudotumor of the epididymis [1].

Case Presentation

We report the case of a 22-year-old young patient with no notable history, presented with a left testicular mass discovered by autopalpation, which has gradually increased in size over the past 3 years. On physical examination, a left, firm, non-hardened, painless paratesticular mass was palpated. The transillumination test pointed to a tissue mass.

The ultrasound objectified the presence of an epididymal mass of 16 mm × 26 mm × 27 mm stuck to the upper pole of the testis without signs of invasion, well limited, of oval shape with lobulated contours, heterogeneous echostructure containing some macrocalcifications, vascularized at Doppler (Figure 1).

The radiological assessment was completed by scrotal MRI which showed a very limited left tissue formation of 27 mm × 24 mm in hypo-signal in T1, T2 and in diffusion, improving markedly after injection of contrast product, without signs of necrosis (Figure 2).

An inguinal left testicular exploration is then performed. It shows a totally dissectable paratesticular mass from the testis and epididymis. Excised respecting the adjacent structures (Figure 3).

The diagnosis of a benign fibrous tumor of the epididymis was retained on histological examination.

OPEN ACCESS

*Correspondence:

Amine Saouli, Department of Urology B,
CHU Ibn Sina, Mohamed V University,
Rabat, Morocco, Tel: 0676779535;
E-mail: amine.saouli0@gmail.com

Received Date: 01 Aug 2022

Accepted Date: 29 Aug 2022

Published Date: 02 Sep 2022

Citation:

Zerda I, Saouli A, Bilgo A, Karmouni T, El Khader K, Koutani A, et al. Paratesticular Fibrous Pseudotumor: A Case Report. *Oncol Case Report J*. 2022; 5(1): 1045.

ISSN: 2641-9173

Copyright © 2022 Amine Saouli. This is an open access article distributed under the Creative Commons Attribution License, which permits unrestricted use, distribution, and reproduction in any medium, provided the original work is properly cited.

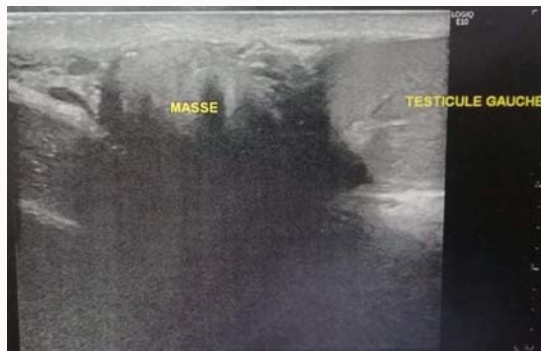


Figure 1: Scrotal ultrasound showing the epididymal mass.

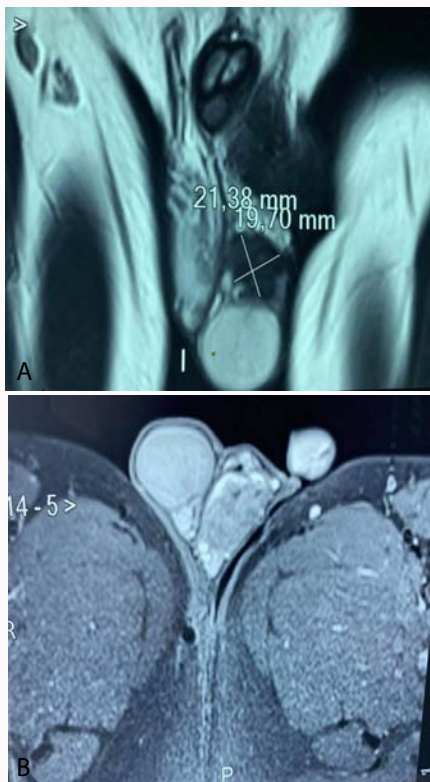


Figure 2: A: Testicular MRI, coronal slice, T2 showing the epididymal mass. B: Testicular MRI, axial slice, T1.

Discussion

Fibrous or fibroinflammatory tumors is the rarest entity of benign paratesticular tumors [2], which may be primary or secondary to a repair process after trauma, or after inflammation. These lesions are localized on the vaginal tunica, the epididymis and the tunica albuginea [3]. These different tumors were first described in the literature by Astley Cooper in 1830, and then described under various names encompassing different entities: Fibrous pseudotumor (Mostofi), testicular tunic fibroma (Jones), inflammatory pseudotumors [4]. The incidence Global paratesticular fibrous pseudotumor is exceptionally rare with around 200 cases reported to date [5].

The clinical presentation of these tumors often takes the form of multiple, painless, intrascrotal nodules that evolve over several years in young patients [6], but other signs may reveal these entities such as hydrocele present in half of the cases. Ca pathogenesis is due to

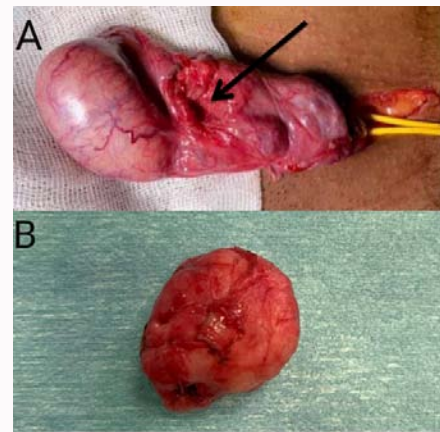


Figure 3: A) Intraoperative view after resection of the pseudo fibrous tumor. B) Macroscopic appearance of the fibrous tumor of the epididymis.

a primary immune-mediated inflammatory reaction characterized by lesions containing dense fibrosis ("storiform") with infiltration of IgG4 positive plasma cells [7], or secondary which is a probable response to trauma, surgery, or infection which is difficult to objectify by questioning our patient.

However, the scrotal ultrasound was not specific. It showed one or more solid masses typically attached to, or associated with testicular tunics, of varying echogenicity [8,9]. Magnetic resonance imaging is more characteristic by showing hypointense in T1 and T2, with very weak or absent gadolinium uptake, on the other hand in our case the contrast uptake was marked [8,10].

Macroscopically, fibrous pseudotumors mainly manifest as firm, white nodules, well-defined, ovoid, motile structures. They can be single or multiple.

Microscopically, fibrous pseudotumors are composed of dense fibrous tissue made up of hyalinized collagen and spindle-shaped fibroblasts with variable proportions associated with a more or less marked inflammatory lymphoplasmacyte infiltrate. As they can be calcified, mitoses are absent or infrequent [11].

The therapeutic decision depends on the results of the surgical exploration associated with an extemporaneous histopathological study if possible, which can confirm the criteria of benignity and opts for the conservative attitude which consists of excision of the tumor and the vaginal tunica, if the benign nature is impossible to determine extemporaneously, an orchiectomy is often performed [1,12].

Conclusion

Paratesticular fibrous tumors remain a rare entity of benign tumors, radiological exploration does not confirm the benignity of the tumor, and surgical exploration with an extemporaneous examination remains the most suitable attitude followed by excision of the tumor and the tunica vagina.

References

1. Akan S, Haki O, Ozbay N, Verit A. Testicular fibrous pseudotumour as a rare intrascrotal. *Rev Int Andrologia*. 2015;13(4):138-41.
2. DL Pélouquin, AUCUN CONFLIT D' INTÉRÊT. 2019.
3. Zhang Z, Yang J, Li M, Cai W, Liu Q, Wang T, et al. Paratesticular fibrous pseudotumor: A report of five cases and literature review. *Front Med*. 2014;8(4):484-8.

4. Merhej KL, Kanso C. Pseudotumeurs Fibreuses Paratesticulaires. *Prog Urol*. 2005.
5. Kodama H, Hatakeyama S, Matsumoto T, Tanaka T, Horiguchi H, Kubota Y, et al. A case of fibrous pseudotumor in the scrotum: Challenge for diagnosis and testicular preservation. *Case Rep Urol*. 2018;2018:6904827.
6. Vates TS, Ruemmler-Fisch C, Smilow PC, Fleisher MH. Benign fibrous testicular pseudotumors in children. *J Urol*. 1993;150(6):1886-8.
7. Garber ME, Wu A, Millet JD. IgG4-related disease presenting as a solitary paratesticular fibrous pseudotumor. *Urol Case Rep*. 2021;36:101584.
8. Yang DM, Kim HC, Lim SJ. Sonographic findings of fibrous pseudotumor of the tunica vaginalis. *J Clin Ultrasound*. 2012;40(4):252-4.
9. Akbar SA, Sayyed TA, Jafri SZH, Hasteh F, Neill JSA. Multimodality imaging of paratesticular neoplasms and their rare mimics. *Radiographics*. 2003;23(6):1461-76.
10. Chang Chien YC, Kovács I, Hargitai Z, Magyar L. Paratesticular fibrous pseudotumor: A new entity of IgG4-related disease? *Ann Clin Lab Sci*. 2018;48(3):381-5.
11. Al-Sayyad A, Cagiannos I. Fibrous pseudotumor of the epididymis and tunica vaginalis. *Can J Urol*. 2006;13(5):3279-80.
12. Bhandari A, Elder JS, MacLennan GT. Fibrous pseudotumor of the tunica vaginalis. *J Urol*. 2008;179(2):727.