



Pancreaticojejunostomy vs Pancreaticogastrostomy Reconstruction Following Pancreaticoduodenectomy: Meta-Analysis of Various Techniques to Prevent Pancreatic Fistula after Duodeno-Pancreatectomy

Danilo Coco^{1*} and Silvana Leanza²

¹Department of General Surgery and Surgical Pathology, Madre Teresa of Calcutta Hospital, Schiavonia, Padova, Italy

²Department of General Surgery and Surgical Pathology, Carlo Urbani Hospital, Jesi, Ancona, Italy

Abstract

Pancreatico-duodenectomy has been the main procedure for patients with malignant and benign diseases. Pancreatic anastomosis remains the Achilles's heel. Two types of pancreatic anastomosis have been gained favor in recent years: Pancreatico-gastrostomy versus Pancretico-jujenostomy. In both techniques there are still many others modified technique. In this review, we analyzed various types of anastomoses to underline which is the major safe anastomosis with good results.

Keywords: Pancretico-jujenostomy (PJ)- -PJ end to side; PJ end to end; PJ duct to mucosa sec cattell-warren; PJ duct to mucosa sec blumgart; PJ sec Peng binding/dunking; PJ Su ansa R-Y; PJ pair watch; PJ ante-colic; PJ retrocolic; PJ under colic (Viola); PJ end to sideVolkman technique; PJ with transfixing suture chen technique; Pancreatico-gastrostomy: Waugh-Clagett technique; Ohigashi technique; Montenegro technique; Stent technique

Introduction

From 1940 with the first Pancreaticoduodenectomy performed by Whipple, Pancreatico-Duodenectomy (PD) following Pylorus Preserving Pancreatico-Duodenectomy (PPPD in the last years) [1], have been the main procedures for patients with malignant and benign diseases of the head of pancreas and periampullary region and remains a technically demanding operation [2-4]. The pancreatic anastomosis is one of the crucial points of the pancreaticoduodenectomy procedure and is still the Achilles' heel of this surgery [5]. Pancreatic anastomosis leakage remains a major cause of postoperative morbidity after pancreaticoduodenectomy between 9% to 30% and it contributes significantly to operative mortality between 1% to 5% [6-8]. For this reason a variety of Pancreatico-Enteric anastomosis have been employed to reduce morbidity and mortality. Two types of pancreatic anastomosis have been gained favour in recent years: Pancreatico-gastrostomy versus Pancretico-Jujenostomy. Both techniques can be further divided into many others modified technique to achieve the best results. The best technique in pancreatic anastomosis is still debated [9]. In this review, we analyzed various types of anastomoses to obtain which are the major safe anastomoses with good results. To date there is a lack of well-designed and well-conducted randomized and non-randomized studies [10-12].

Methods

We performed a PUBMED review and Cochrane review from 1995 to 2017 about every type of Pancreatico-Enteric anastomosis. We analyzed Pancretico-Jujenostomy (PJ) (110 manuscripts) with variants as end to side, end to end, duct-to mucosa technique, Blumgart technique, modified Blumgart, Peng technique (binding or dunking technique), over-mesocolic or under mesocolic Pancreatico-Jujenostomy and Pancreatico-Gastrostomy (PG) (25 manuscripts) and his variants as binding, Montenegro technique, Ohigashy technique. We have found fourteen different types of pancreatic-enteric anastomoses. The objective of this study is to describe and compare one of the most frequently used techniques for pancreatic anastomosis [3].

Results

Multiple techniques in anastomosing the pancreatic duct to the Gastro-Intestinal (GI)

OPEN ACCESS

*Correspondence:

Danilo Coco, Madre Teresa of Calcutta Hospital, Schiavonia, Padova, Italy, E-mail: webcostruction@msn.com

Received Date: 07 Mar 2018

Accepted Date: 13 Apr 2018

Published Date: 20 Apr 2018

Citation:

Coco D, Leanza S. Pancreaticojejunostomy vs Pancreaticogastrostomy Reconstruction Following Pancreaticoduodenectomy: Meta-Analysis of Various Techniques to Prevent Pancreatic Fistula after Duodeno-Pancreatectomy. *Ann Digest Liver Dis.* 2018; 1(1): 1005.

Copyright © 2018 Danilo Coco. This is an open access article distributed under the Creative Commons Attribution License, which permits unrestricted use, distribution, and reproduction in any medium, provided the original work is properly cited.

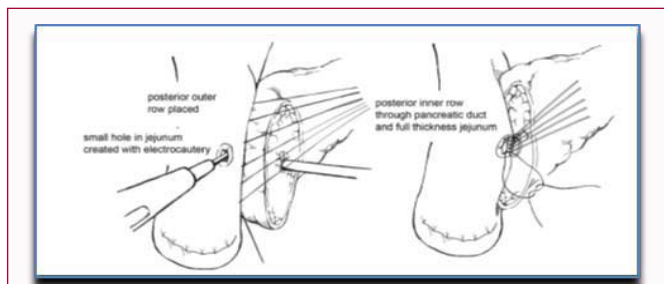


Figure 1: Sequential steps of a Cattell-Warren Anastomosis.

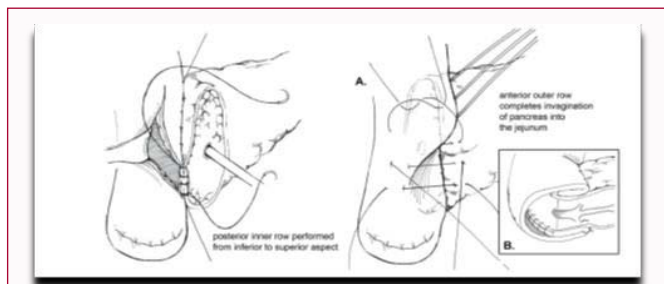


Figure 2: Invagination Pancreaticojejunostomy.

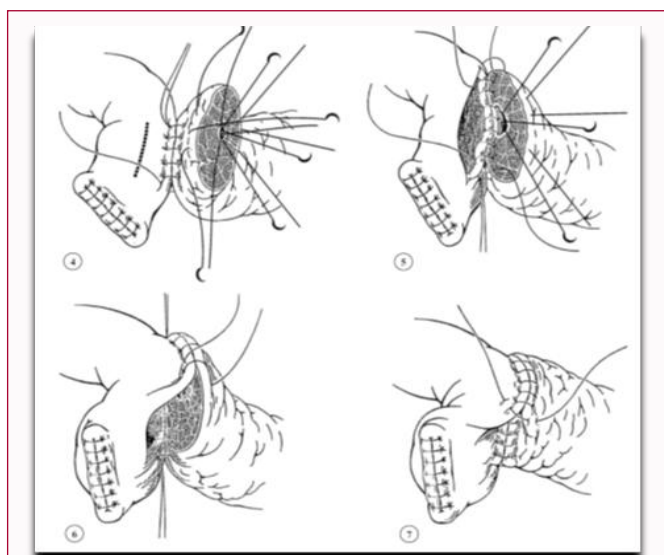


Figure 3: Modified duct-to-mucosa: Blumgart's techniques.

tract after pancreaticoduodenectomy have been described in the literature. Two of the predominant methods of creating a PJ and PG. Pancreatojejunal anastomosis technique: Ever since Whipple modified pancreaticoduodenectomy in 1942 by performing pancreaticojejunostomy instead of occlusion of pancreatic remnant, this type of anastomosis has been most commonly used for a reconstruction of pancreatic digestive continuity. There have been further modifications over the years. For example, jejunal loop can be positioned in antecolic, retrocolic or retro-mesenteric fashion, or the isolated Roux loop pancreaticojejunostomy can be performed. The anastomosis can be performed as an end-to-end anastomosis with invagination of the pancreatic stump in the jejunum or as an end-to-side anastomosis with or without duct-to-mucosa suturing [13].

Pancreatico-Jujenostomy Group (PJG)

“PJ end-to-side duct-to-mucosa anastomosis: Cattell-Warren”:

A two-layer anastomosis is constructed with interrupted absorbable suture material:

- a) A posterior row of seromuscular sutures securing the jejunum to the pancreas.
- b) Pancreatic duct to jejunal mucosa sutures.
- c) Posterior parenchymal and duct to mucosa sutures [14] (Images in PDF Article)
- d) Completion of an anterior layer of seromuscular sutures again securing the anterior aspect of the opened jejunum to the capsule of the pancreas [15] (Figure 1).

“PJ end to side duct to mucosa with invagination: invaginate or “dunk” all of the cut edge of the pancreatic parenchyma into the lumen of the jejunum:

- a) Posterior row of interrupted seromuscular sutures bringing the jejunum into apposition with the pancreatic capsule.
- b) Jejunum is opened
- c) An inner layer of running locking suture is then performed taking full-thickness jejunal bites and large bites of the pancreatic parenchyma and capsule,
- c) An anterior layer of seromuscular sutures rolling the jejunum onto the pancreatic capsule [15] (Figure 2).

“PJ Modified duct-to-mucosa: Blumgart's techniques”:

Transpancreatic U-suture technique with a duct to mucosa anastomosis: a full thickness posterior-to-anterior bite coming up through the pancreas [15] (Figure 3)

“PJ Peng's techniques: end to end binding technique”:

Proximal 3 cm of the pancreatic stump is then anastomosed to just the mucosa of the jejunum. The treated 3 cm of jejunum are then rolled out and intussuscepted back over the pancreas [15] (Figure 4).

“Isolated Roux loop PJ”:

A separate Roux loop was created for the end-to-side Hepatico-Jejunostomy (HJ) and the end-to-side antecolic Gastro-Jejunostomy (GJ) [16] (Figure 5).

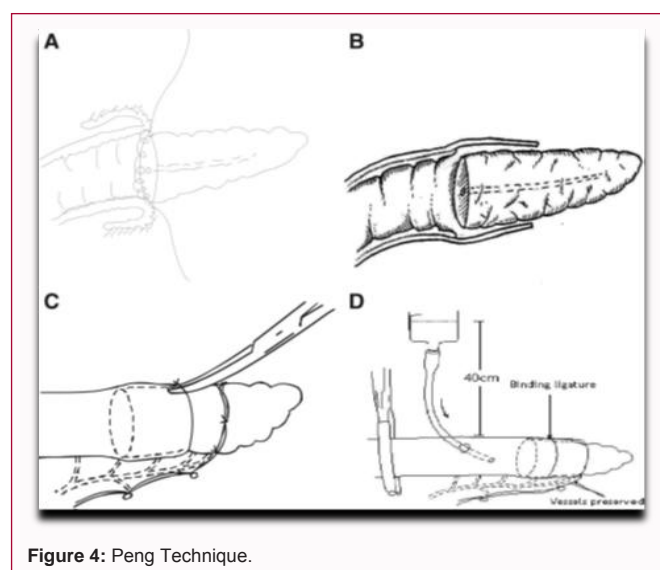


Figure 4: Peng Technique.

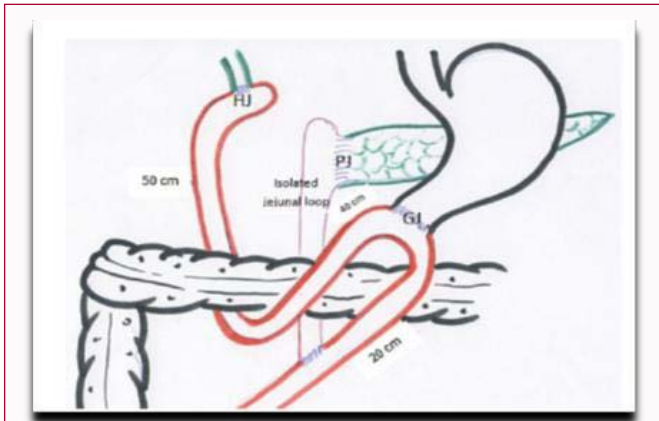


Figure 5: Isolated Roux loop PJ.

polyglactin 910 at the centre of the mucosa, where another tip of the stent tube was introduced into the intestinal lumen, and ligated by this fast-absorbable suture.

The other tip of the tube was introduced dextracorporeally through the transhepatic or transintestinal route. The pancreatic juice flowed through the lumen of the stent tube and then drained externally [17] (Figure 6).

“Pair-Watch suturing technique PJ”:

End to side duct to mucosa with internal/external tube

Pair-Watch suturing technique: the faces of a pair of watches, the jejunal hole corresponding to the left-side watch and the pancreatic duct hole to the right-side one (Figure 2). The posterior wall of pancreatic duct consists of the latter half of the clock cycle, from 6 o'clock to 12 o'clock, and the posterior wall of jejunal hole consists of the first half of the clock cycle, from 12 o'clock to 6 o'clock [18] (Figure 7).

“PJ reinforcing the pancreas”:

The Polyethylene Glycolic Acid (PGA) felt pasting method.

Paste a couple of PGA felts (1.5e2.0 4.0e5.0 cm in size) with fibrin sealant around the cut end of the pancreatic remnant.

End-to-side 2-layer anastomosis is performed.

Suture the cut end of the pancreas remnant reinforced with PGA felts and seromuscular layer of jejunum.

Completion. The line of anastomosis is not covered with the PGA felts [19] (Figure 8).

“Transverse Mesocolic Sandwich”

End to side duct to mucosa PJ in sub. Mesocolic fashion with mesocolic sutures reinforced (Figure 9).

Pancreatico-gastrostomy group (PGG).

“Classical PG anastomosis: Waugh-Clagett 1946”:

The proximal part of the pancreatic remnant was mobilized from the splenic vessels and the retroperitoneum for subsequent anastomosis to the posterior gastric wall.

The PG was constructed in two layers. A seromuscular suture was performed between the posterior wall of the stomach and pancreatic capsule using either interrupted or continuous 3/0 silk.

A 2.5 cm-3.0 cm Gastrostomy was performed and the pancreatic parenchyma with the duct were sutured to the full thickness of the stomach using interrupted or continuous 5/0 vicryl sutures.

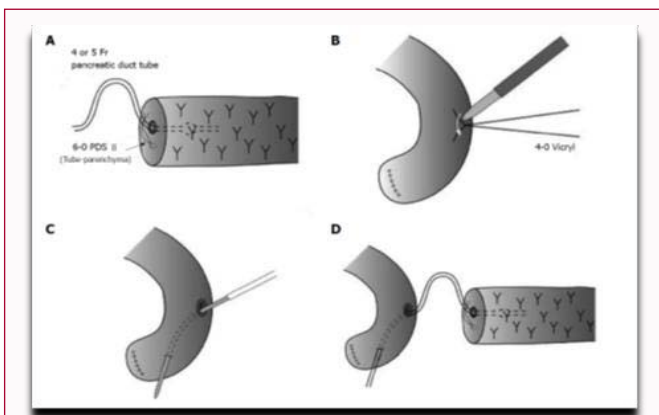


Figure 6: Volkman's PJ with internal-external tube.

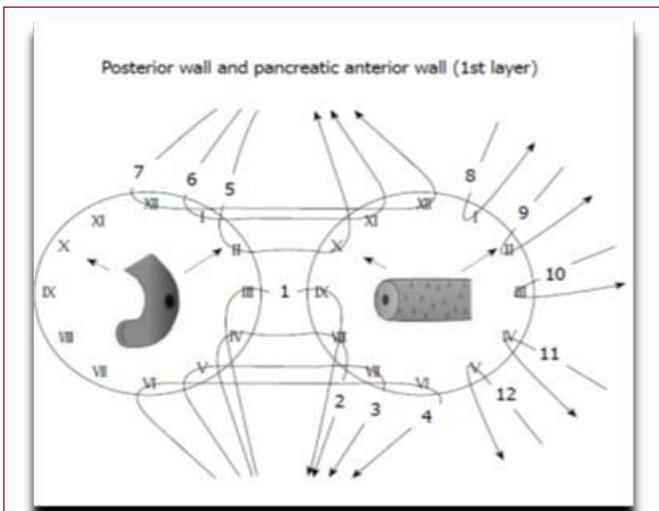


Figure 7: Pair-Watch suturing technique PJ.

“Volkman's PJ with internal-external tube”:

The stent tube was ligated with the pancreatic duct near the cut end by a 4-0 fast-absorbable synthetic suture.

The seromuscular layer of the jejunum was cut at the anti-mesenteric side.

A purse-string suture was made by using a 4-0 irradiated

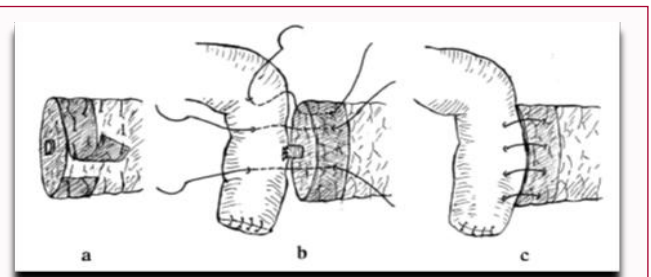


Figure 8: PJ reinforcing the pancreas.

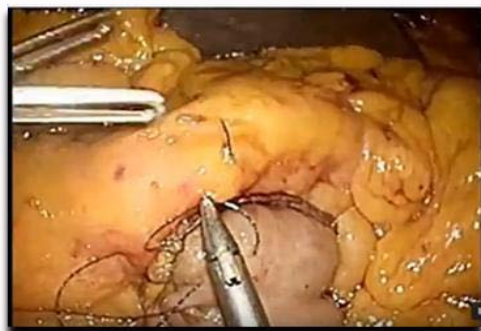


Figure 9: Sub mesocolic fashion with mesocolic sutures reinforced.

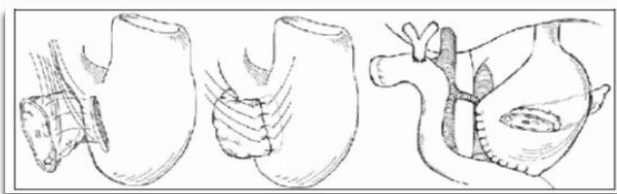


Figure 10: Classical PG anastomosis: Waugh-Clagett 1946.

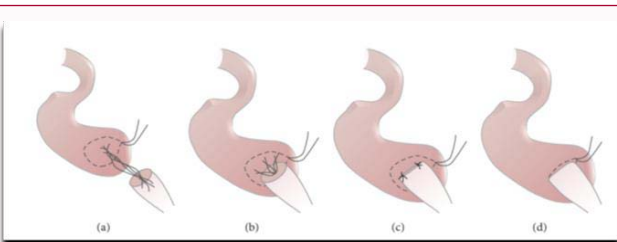


Figure 11: Ohigashi Technique: Dunking pancreas with two purse-string suture.

The outer seromuscular layer between the stomach and pancreatic capsule was sutured using 3/0 silk interrupted sutures without pancreatic stenting [16] (Figure 10).

“Ohigashi’s PG”:

Dunking pancreas with two purse-string suture (Figure 11)

“Montenegro’s binding techniques PG”:

Dunking stump pancreas is anastomised after a sleeve pancreatectomy with one purse-string suture (Figure 12)

“Stenting PG”:

The same technique with free stent in pancreatic duct (Figure 13)

PG One Binding Purse-String and Two Transfixing Mattress Sutures:

The two mattress sutures running through the posterior gastric wall and the pancreatic remnant in an U-like fashion, while the purse-string suture is already in place. PS: Pursestring Suture [20] (Figure 14)

Discussion

We have summarized the following advantages of Pancreatogastrostomy over Pancreatojejunostomy:

- a) It can be performed easily, because the posterior wall of

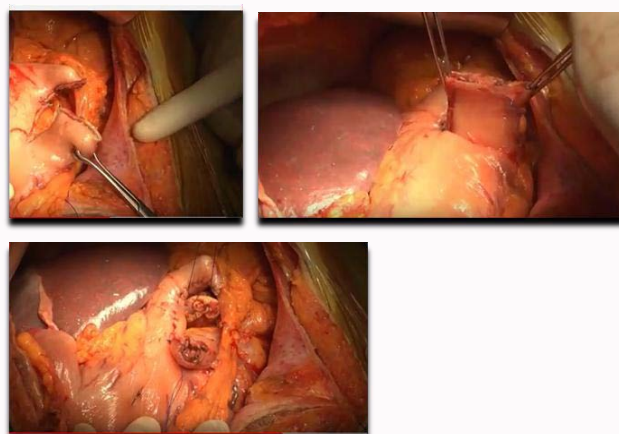


Figure 12: Montenegro’s Technique: Sleeve Gastrectomy.

the stomach lies immediately anterior to the mobilized pancreatic remnant and is usually wider than the transected pancreas.

- b) The posterior wall of the stomach is thick and highly vascularised
- c) PG anastomosis is then located at a certain distance away from the major blood vessels
- d) The pancreatic exocrine secretions enter the potentially acidic gastric environment, precluding digestive damage of the Pancreatoenteric anastomosis by activated proteolytic enzymes
- e) PG avoids the long jejunal loop where pancreatobiliary secretions accumulate during the early postoperative period and reduces the number of anastomoses in a single loop of retained jejunum, which potentially decreases the likelihood of loop kinking
- f) A nasogastric tube can be used as drainage if a fistula occurs after PG, thereby avoiding potentially invasive procedures [21]
- g) EGDS can be performed to control anastomosis

From these studies we have highlighted a comparison of both techniques. To compare both techniques of reconstruction, five randomized trials [39,52,54-56] and several meta-analysis and systematic reviews[16,22,53,57-64] have been published in the recent years. Systematic reviews included 553 patients and found a significant difference only in the incidence of intraabdominal collections favouring PG (OR = 0.46; 95%CI: 0.26-0.79; P = 0.005). Pancreatic Fistulas (PF), Delayed Gastric Emptying (DGE) and mortality were not different.

Conclusions

Some authors sustained PJ over PG and the other way around. Analyzing PubMed manuscripts and Cochrane review, we found PJ may differ little from PG in length of hospital stay (MD 1.04 days, 95% CI -1.18 to 3.27), risk of surgical re-intervention (11.6% vs 10.3%; RR 1.18, 95% CI 0.86 to 1.61). We identified no difference between PJ and PG in terms of risk of any surgical complication (46.5% vs 44.5%; RR 1.03, 95% CI 0.90 to 1.18. PJ may improve the risk of postoperative bleeding (9.3% vs 13.8%; RR 0.69, 95% CI: 0.51 to 0.93), but may worsen the risk of developing intra-abdominal abscess (14.7% vs 8.0%; RR 1.77, 95% CI 1.11 to 2.81).The lack of a uniform technique for PG and PJ raises the same controversy, since different operative procedures could reasonably lead to different complications [18].

References

- Diener MK, Heukauffer C, Schwarzer G, Seiler CM, Antes G, Buchler MW, et al. Pancreaticoduodenectomy (classic Whipple) versus pylorus-preserving pancreaticoduodenectomy (pp Whipple) for surgical treatment of periampullary and pancreatic carcinoma. *Cochrane Database Syst Rev.* 2008;16(2).
- R Montenegro costa, L Lucas. Ten years experience with 150 pancreaticoduodenectomy with pancreaticoenteric reconstruction using sleeve pancreaticogastrostomy (montenegro's binding technique). 2016;18:e434.
- Whipple AO. Observations on radical surgery for lesions of pancreas. *Surg Gynecol Obstet.* 1946;82:623-31.
- Trimble IR, Parsons JW, Sherman CP. A one stage operation for cure of carcinoma of the ampulla of Vater and of the head of the pancreas. *Surg Gynecol Obstet.* 1941;73:711-22.
- Targarona J, Barreda L, Pando E, Barreda C. Is peng's pancreaticojejunal anastomosis more effective than mucosa-mucosa anastomosis in duodenopancreatectomy for pancreatic and peri-ampullary tumours?, *Cir Esp.* 2013;91(3):163-8.
- Bassi C, Dervenis C, Butturini G, Fingerhut A, Yeo C, Izbicki J, et al. Postoperative pancreatic fistula: An International Study Group (ISGPF) definition. *Surgery.* 2005;138(1):8-13.
- Alexakis N, Halloran C, Raraty M, Ghaneh P, Sutton R, Neoptolemos JP. Current standards of surgery for pancreatic cancer. *Br J Surg.* 2004;91(11):1410-27.
- Halloran CM, Ghaneh P, Bosonnet L, Hartley MN, Sutton R, Neoptolemos JP. Complications of pancreatic cancer resection. *Dig Surg.* 2002;19(2):138-46.
- Shu You Peng, Jian Wei Wang, Wan Yee Lau, Xiu Jun Cai, Yi Ping Mou, Ying Bin Liu, et al. Conventional versus binding pancreaticojejunostomy after pancreaticoduodenectomy A Prospective Randomized Trial. *Ann Surg.* 2007;245(5):692-8.
- Bassi C, Falconi M, Molinari E, Mantovani W, Butturini G, Gumbs AA, et al. Duct-to-mucosa versus end-to-side pancreaticojejunostomy reconstruction after pancreaticoduodenectomy: results of a prospective randomized trial. *Surgery.* 2003;134(5):766-71.
- Berger AC, Howard TJ, Kennedy EP, Sauter PK, Bower-Cherry M, Dutkevitch S, et al. Does type of pancreaticojejunostomy after pancreaticoduodenectomy decrease rate of pancreatic fistula? A randomized, prospective, dual-institution trial. *J Am Coll Surg.* 2009;208(5):738-47.
- Langrehr JM, Bahra M, Jacob D, Glanemann M, Neuhaus P. Prospective randomized comparison between a new mattress technique and Cattell (duct-to-mucosa) pancreaticojejunostomy for pancreatic resection. *World J Surg.* 2005;29(9):1111-9.
- Mario Zovak, Dubravka Mužina Mišić, Goran Glavčić. Pancreatic surgery: evolution and current tailored approach. *Hepatobiliary Surg Nutr.* 2014;3(5):247-258.
- Halloran CM, Platt K, Gerard A, Polydoros F, O'Reilly DA, Gomez D, et al. PANasta Trial; Cattell Warren versus Blumgart techniques of pancreaticojejunostomy following pancreatoduodenectomy: Study protocol for a randomized controlled trial. *Trials.* 2016;17:30.
- Hans F Schoellhammer, Yuman Fong, Singh Gagandeep. Techniques for prevention of pancreatic leak after pancreatectomy. *Hepatobiliary Surg Nutr.* 2014;3(5):276-87.
- Ayman El Nakeeb, Emad Hamdy, Ahmad M Sultan, Tarek Salah, Waleed Askr, Helmy Ezzat, et al. Isolated Roux loop pancreaticojejunostomy versus pancreaticogastrostomy after pancreaticoduodenectomy: A prospective randomized study, HPB. 2014;16(8):713-22.
- Kenichi Hakamada, Shunji Narumi, Yoshikazu Toyoki, Masaki Nara, Kenosuke Ishido, Takuya Miura, et al. An easier method for performing a pancreaticojejunostomy for the soft pancreas using a fast-absorbable suture. *World J Gastroenterol.* 2008;14(7):1091-6.
- Azumi Y, Isaji S, Kato H, Nobuoka Y, Kuriyama N, Kishiwada M, et al. A standardized technique for safe pancreaticojejunostomy: Pair-watch suturing technique, *World J Gastroenterol Surg.* 2010;2(8):260-4.
- Masafumi Kuramoto, Satoshi Ikeshima, Shinya Shimada, Kenichiro Yamamoto, Toshiro Masuda, Kenichi Nakamura, et al. Pancreaticojejunostomy by reinforcing the pancreas without covering the anastomotic line reduces pancreatic fistula, *International Journal of Surgery.* 2013;11(9):909-13.
- D Kbartsch, P Langer, V Kanngießner, V Fendrich, K Dietzel et al. Clinical study a simple and safe anastomosis for pancreatogastrostomy using one binding purse-string and two transfixing mattress sutures. *International Journal of Surgical Oncology.* 2012(2012).
- Gómez T. Technique of reconstruction after pancreatoduodenectomy, *World J Gastroenterol Surg.* 2014;6(9).