



Optimizing Anterior Implant Outcome Immediately after Implant Placement and Grafting by using Patient's Extracted Teeth: A Case Report

Soni Prasad¹*, Jay Darryl Banez¹, Despoina Bompolaki² and Yvonne Hart¹

¹Department of General Dental Science, Marquette University School of Dentistry, USA

²Department of Restorative Dentistry, Oregon Health and Science University School of Dentistry, USA

Abstract

Optimizing anterior implant outcome using patient's extracted teeth.

Successful implant treatment in the anterior maxilla is predicated on providing a functional and esthetically acceptable outcome. As well, achieving a predictable ideal emergence profile and soft tissue contour is expected. Placing immediate provisional restorations utilizing the patient's modified extracted teeth can facilitate initiate facial soft tissue contouring while precluding undue pressure on the surgical site during the early healing phase. This allows for a one stage surgical procedure, fixed provisionalization and ideal tissue contouring.

This clinical report presents the use of a patient's modified extracted permanent teeth as bonded fixed provisional restorations placed immediately after implant placement and bone grafting. The gingival-lingual and cingulum tooth structure was recontoured to allow no contact with the implant or bone graft material. A combination of cement and screw-retained definitive restorations were fabricated with contours reflecting the tissue contours established by the interim restoration.

Introduction

Restoring maxillary anterior teeth with implants is challenging due to high esthetic expectations and the fact that the maxillary anterior ridge often presents with minimal facial bone thickness requiring hard and soft tissue grafting [1-3]. Patients presenting with a high smile line, thin biotype and limited mesiodistal space, further add to the challenge [4]. Therefore, providing esthetic anterior maxillary implant restorations may be more difficult to accomplish than achieving implant osseointegration.

Traditional anterior implant placement requires extraction of non-restorable teeth and grafting with a healing period of 3-4 months [5,6]. Following healing, surgical implant placement is performed and an additional healing time allowed for osseointegration. This protocol requires multiple surgical appointments and extended treatment time [5,6]. Immediate implant placement (IIP) protocol which allows placement of implants and bone grafting simultaneously, shortens treatment time, reduces the number of surgical procedures, and increases patient compliance [7-11].

Providing a provisional restoration during the healing phase of an IIP procedure is important for anterior implants for several reasons, patient acceptance being one of them [4,12,13]. The anterior implant site can be provisionalized using either a fixed, removable, or an implant supported prostheses [1]. Provisionalization using a removable partial denture has the potential of placing undesirable pressure on the healing site [1]. A fixed tooth supported provisional restoration addresses this issue but still does not provide for emergence profile and soft tissue maturation [1].

An immediate implant provisional restoration (IIPR) has significant benefits when compared to the traditional delayed protocol. These include establishing an ideal emergence profile with maximum tissue volume, preserving mid-facial gingiva and enhancing patient comfort and acceptability [10,12,14-17]. IIPR serves as a guide for designing an esthetic definitive restoration which facilitates adequate hygiene [12,18]. Therefore, IIP together with IIPR helps develop the desired esthetics for anterior implant restorations [12].

OPEN ACCESS

*Correspondence:

Soni Prasad, Department of General Dental Sciences, Marquette University School of Dentistry, 1801 W Wisconsin Ave., Rm. 360, Milwaukee, WI 53233, USA, Tel: (414) 288-6515;

E-mail: soni.prasad@marquette.edu

Received Date: 08 Nov 2016

Accepted Date: 15 Dec 2016

Published Date: 04 Jan 2017

Citation:

Prasad S, Banez JD, Bompolaki D, Hart Y. Optimizing Anterior Implant Outcome Immediately after Implant Placement and Grafting by using Patient's Extracted Teeth: A Case Report. *J Dent Oral Biol.* 2017; 2(1): 1022.

Copyright © 2017 Soni Prasad. This is an open access article distributed under the Creative Commons Attribution License, which permits unrestricted use, distribution, and reproduction in any medium, provided the original work is properly cited.

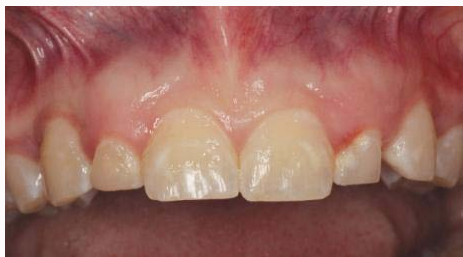

Figure 1: Pre-operative view: Malformed permanent maxillary right and left lateral incisors.

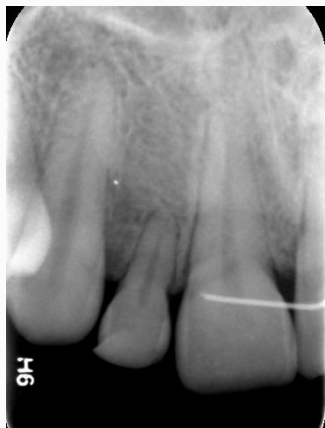

Figure 2: Pre-operative radiograph: Radiograph of maxillary left lateral incisor showing short clinical root.

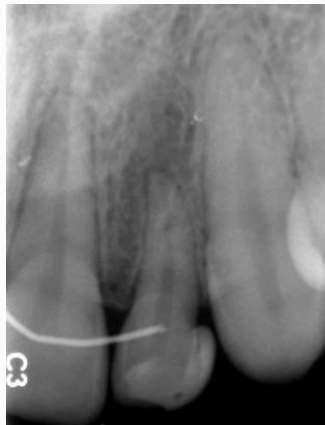

Figure 3: Pre-operative radiograph: Radiograph of maxillary right lateral incisor showing short clinical root.

A number of published articles have shown that survival rates with IIPR are comparable to those achieved with traditional protocols [16,18-20]. However, Atieh et al. [21] determined that IIPR with IIP increases the risk for implant failure. Lateral forces and small diameter implants further negatively affect implant survival of immediately loaded implants [22]. Khzam et al. [23] suggested the possibility of unpredictable soft and hard tissue healing with IIPR. Some authors have suggested that in order to maximize the chance of success, IIPR should be performed along with IIP only when primary stability can be achieved [7,8]. Also, IIPR should not contact the opposing dentition in centric and eccentric occlusion [1,18,24]. When bone grafting is performed concurrently with IIP, IIPR is not indicated due to the risk of implant failure [21]. Instead, a two-stage protocol is to be followed

to allow for uneventful healing of the grafted site without any pressure from the overlying provisional restoration. Patients' extracted teeth have been used as provisional restorations after implant placement without concurrent grafting [25]. However, utilizing a patient's extracted teeth as provisional restorations to contour soft tissue in cases where bone grafting is performed concurrently with IIP has not been documented.

The purpose of this clinical report is to describe the technique and clinical steps necessary to provide immediate implant provisionalization (IIPR) after IIP and bone grafting. This technique precludes allowing pressure on the implant and grafted bone site while safely and predictably contouring the peri-implant soft tissue necessary for fabricating an ideal definitive restoration.

Case Presentation

A 20-year-old woman presented to the pre-doctoral clinic with a chief complaint of two mobile front teeth. Intra-oral examination revealed malformed permanent maxillary left and right lateral incisors with Class II mobility (Figure 1). Radiographic examination revealed short clinical roots of the maxillary lateral incisors (Figure 2 and 3). The lateral incisors were diagnosed to have a poor prognosis based on the clinical and radiographic examination. Treatment options were discussed with the patient. These included: extraction of the maxillary lateral incisors and restoration with implant-supported crowns or, extraction and restoration with a conventional fixed dental prosthesis. The patient chose the treatment plan that included extraction of the maxillary lateral incisors and implant supported single crowns. A diagnostic wax-up was performed to obtain ideal contours of the maxillary lateral incisors. Cone beam computed tomography (CBCT) was performed to evaluate the teeth and surrounding structures. CBCT imaging revealed inadequate alveolar ridge width at the proposed implant sites. It was decided to follow an immediate implant placement protocol with grafting to augment the alveolar ridge width. A surgical guide was fabricated based on the diagnostic wax-up to guide the implant placement in a proper 3-dimensional orientation.

On the day of the surgery, extraction of the malformed maxillary lateral incisors was performed and two endosseous implants (3.3 × 12 mm NC SL Active, Straumann USA) were placed using the surgical guide. The implants were torque to 35Ncm and healing abutments were placed (NC Healing abutment, 3.6 × 3.5 mm Straumann USA). Concurrent allogeneous bone grafting was performed to achieve adequate ridge anatomy and bone thickness. Post-surgery, the patient's extracted teeth were used to fabricate bonded restorations

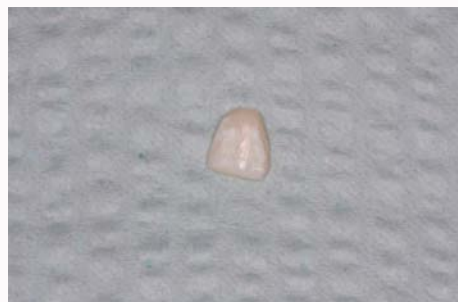

Figure 4: Shaped extracted lateral incisor: The root of the extracted lateral incisor was sectioned and the palatal surface of the crown was trimmed. The remaining intact cervicofacial facade was shaped to mimic an ovate gingival contour to aid in soft tissue contouring.

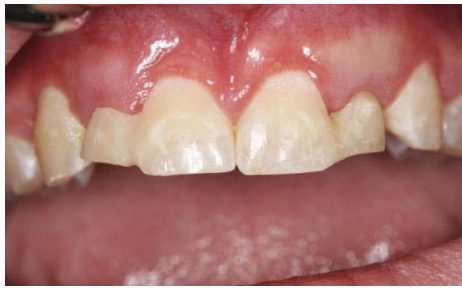

Figure 5: Bonded extraction teeth in place: Frontal view of bonded extracted lateral incisors immediately after implant placement.

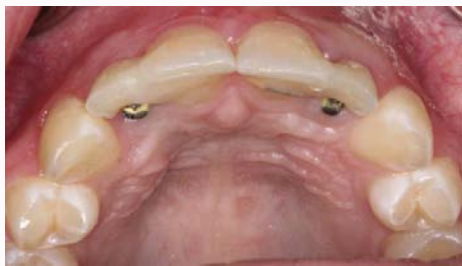

Figure 6: Bonded extraction teeth in place: Occlusal view of bonded extracted lateral incisors immediately after implant placement.

to restore the missing lateral incisors. Modifications to the patient's teeth were made. The roots of the extracted teeth were sectioned and the palatal and cingulum surfaces of the crowns were removed. The remaining intact cervicofacial facades were shaped to mimic ovate gingival contours to aid in facial soft tissue contouring (Figure 4). The distal surfaces of the left and right central incisors were then etched with 32% phosphoric acid (Unietch, Bisco Inc.) and primer and adhesive were applied (Optibond FL, Kerr.) The contoured lateral incisors were bonded to the central incisors with flowable resin (Synergy D6 Flow, Coltene) (Figure 5 and 6). The bonded extracted lateral incisors did not apply pressure to the newly placed implants or grafted sites. The bonded restorations were taken out of occlusion and the teeth remained bonded throughout the healing period without complications. This technique allowed early facial soft tissue contouring and uneventful healing of the implants and graft sites.

Eight weeks post-surgery the bonded provisional restorations and healing abutments were removed and a fixture level impression was made with open tray impression copings (NC Impression post, Straumann) and poly vinyl siloxane impression material (Aquasil Ultra LV and monophasic, Dentsply Caulk). The tray was removed after the impression was set and the healing abutments were replaced and the extracted lateral incisor interim restorations were re-bonded. The implant-level impression was poured in Type 5 dental stone (Jade Stone, Whipmix Corp) to obtain a working cast. Screw retained provisional restorations were fabricated in acrylic resin (SNAP, Parkell) using a pull down matrix of a cast of the diagnostic wax-up and temporary abutments (NC Temporary Abutment, Straumann) screwed to place in the working model. An ideal emergence profile was developed in the provisional screw-retained restorations which were placed in the patient to finalize the surrounding soft tissue healing (Figure 7). The provisional restorations were torque to 15 Ncm and the screw channels filled with cotton and Teflon tape and sealed with flowable resin. Centric and lateral occlusal contacts were eliminated to minimize non-axial loading. Oral hygiene instructions

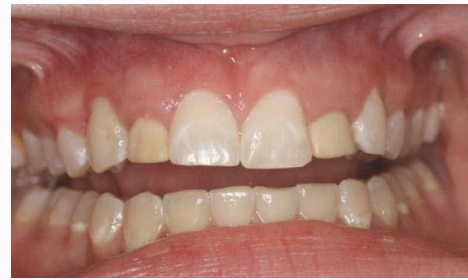

Figure 7: Screw-retained provisional restorations: 8-week post placement, screw-retained provisional restorations inserted to finalize surrounding soft tissue healing.

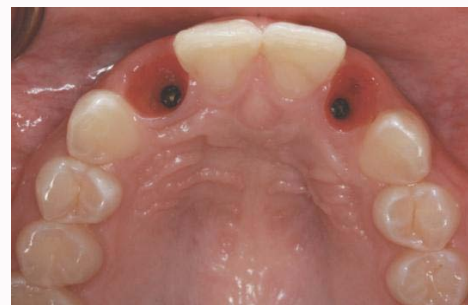

Figure 8: Mature peri-implant soft tissue: Healed peri-implant soft tissue with ideal emergence profile.

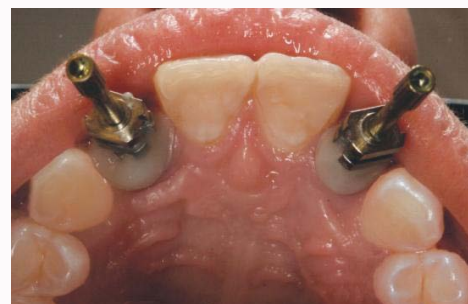

Figure 9: Implant impression: Capturing molded soft tissue profile with custom impression copings.

were given to the patient.

Two weeks later the screw-retained provisional restorations were removed from the right and left lateral incisors to evaluate soft tissue healing. The position of the free gingival margin was assessed in relation to the desired definitive restorations. Measurements were made from the implant to the free gingival margin to evaluate the amount of soft tissue contouring that would be possible without violating the biologic width. A soft tissue laser (AMD Picasso Lite Diode Laser, DENTSPLY) was used to contour the facial gingiva to correct the discrepancies between central and lateral incisors while maintaining 3mm of soft tissue height around the implants. The screw-retained provisional restorations were relined with flowable resin and screwed to place, torque to 15Ncm and the screw channels resealed.

After three weeks, stability of the soft tissue was determined (Figure 8) and the fabrication of the definitive restorations was initiated. An open-tray impression was made with custom impression copings (Figure 9) to capture the created emergence profile [13]. The impression was poured in Type 5 dental stone to obtain a new

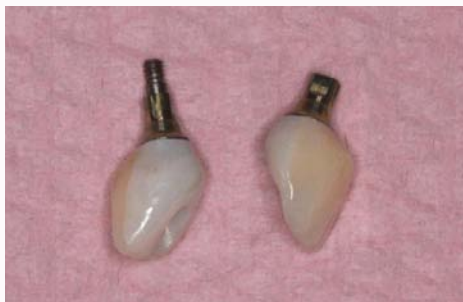

Figure 10: Definitive restorations with ideal contour and emergence profile: All-ceramic crowns were luted extra orally to the custom titanium abutment (Variobase) and the screw-retained abutment-crown unit was then placed intra orally.

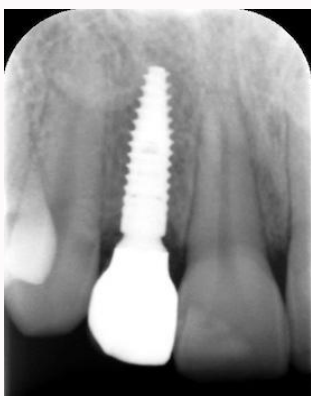

Figure 11: Post –operative radiograph: Radiograph of definitive restoration of maxillary left lateral incisor taken on the day of insertion.

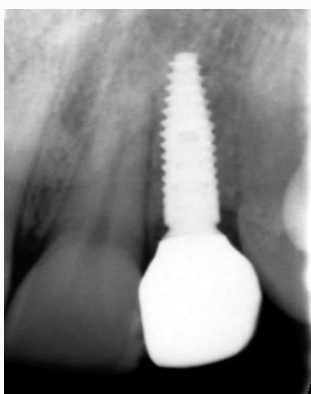


Figure 12: Post-operative radiograph: Radiograph of definitive restoration of maxillary right lateral incisor taken on the day of insertion.

working cast. Custom titanium abutments (NC Variobase abutment, Straumann) and all-ceramic crowns (Lava, 3M ESPE) were fabricated. The crowns were luted to the custom titanium abutments extra orally (Figure 10). The screw-retained abutment- crown assembly was then tried in intra-orally. Radiographs were taken to confirm the seating (Figure 9 and 10) and occlusion was checked with articulating paper (Articulating paper, Henry Schein) and shim stock (Shimstock, Bausch). The definitive restorations (Figure 11 and 12) were torque according to the manufacturer's instruction and the screw channels were filled with Teflon tape and composite resin (Z250, 3M ESPE). Oral hygiene instructions were given and the patient was placed on a 3-month recall.

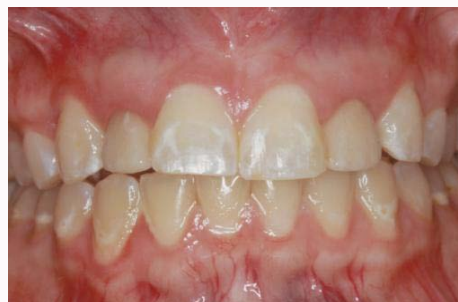

Figure 13: Follow up frontal view: Six-month follow up frontal view with definitive restorations in place.

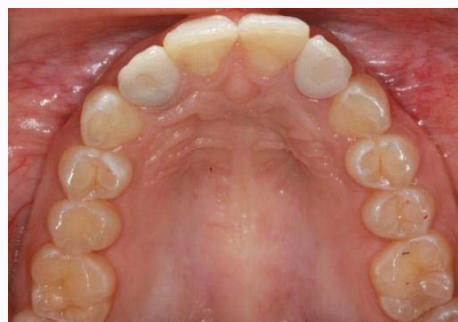

Figure 14: Follow up occlusal view: Six-month follow-up occlusal view of definitive restorations in place.

Discussion

IIP along with bone grafting is often performed as a 2-stage procedure [21]. The implants are uncovered in a second surgical procedure after osseointegration. Healing abutments are placed on the implants before soft tissue contouring is initiated [21]. The present technique describes a protocol for immediate provisionalization using a bonded fixed restoration fabricated from the patient's modified extracted teeth, placed immediately after implant placement and grafting. This enables a 1-stage procedure allowing early contouring of the peri-implant soft tissues without undue stress on the grafted and implanted sites. This procedure provided the natural cervico-facial contours of the extracted teeth for development of ideal emergence profiles. Thus, the early initiation of soft tissue contouring led to a predictable and stable esthetic outcome even when implant placement and grafting were performed concurrently (Figure 13 and 14). It reduced the number of surgical procedures and the treatment time required to deliver definitive restorations.

An impression for the definitive restorations was made after finalizing the soft tissue contours. Proper design of the definitive restoration was crucial for a positive long-term prognosis. Definitive restorations were fabricated using a customized titanium one-piece abutment (NC Variobase abutment, Straumann) that captured the molded contours of the soft tissue surrounding the implant. In addition, it allowed the definitive restorations to be cleansable and retrievable.

Conclusion

This clinical report presented the use of the patient's modified permanent extracted teeth as immediate provisional restorations during the initial healing phase immediately following the single stage procedure of implant placement and bone grafting. The

cervical contours of the extracted teeth were used to influence the initial soft tissue remodeling and healing. As well, it described the clinical procedures involved in fabricating the definitive restorations reproducing similar ideal soft tissue profiles. A combination of cement and screw-retained definitive restorations was described.

References

- Priest G. Esthetic potential of single-implant provisional restorations: selection criteria of available alternatives. *J Esthet Restor Dent.* 2006; 18: 326-338.
- Becker W, Goldstein M. Immediate implant placement: treatment planning and surgical steps for successful outcome. *Periodontol.* 2000; 2008; 47: 79-89.
- Becker CM, Wilson TG, Jr., Jensen OT. Minimum criteria for immediate provisionalization of single-tooth dental implants in extraction sites: a 1-year retrospective study of 100 consecutive cases. *J Oral Maxillofac Surg.* 2011; 69: 491-497.
- Schoenbaum TR, Klokkevold PR, Chang YY. Immediate implant-supported provisional restoration with a root-form pontic for the replacement of two adjacent anterior maxillary teeth: A clinical report. *J Prosthet Dent.* 2013; 109: 277-282.
- Albrektsson T, Branemark PI, Hansson HA, Lindstrom J. Osseointegrated titanium implants. Requirements for ensuring a long-lasting, direct bone-to-implant anchorage in man. *Acta Orthop Scand.* 1981; 52: 155-170.
- Branemark PI. Osseointegration and its experimental background. *J Prosthet Dent.* 1983; 50: 399-410.
- Becker W, Becker BE, Israelson H, Lucchini JP, Handelsman M, Ammons W, et al. One-step surgical placement of Branemark implants: a prospective multicenter clinical study. *Int J Oral Maxillofac Implants.* 1997; 12: 454-462.
- Barone A, Rispoli L, Voza I, Quaranta A, Covani U. Immediate restoration of single implants placed immediately after tooth extraction. *J Periodontol.* 2006; 77: 1914-1920.
- Hammerle CH, Chen ST, Wilson TG, Jr. Consensus statements and recommended clinical procedures regarding the placement of implants in extraction sockets. *Int J Oral Maxillofac Implants.* 2004; 19: 26-28.
- Eposito M, Grusovin MG, Polyzos IP, Felice P, Worthington HV. Interventions for replacing missing teeth: dental implants in fresh extraction sockets (immediate, immediate-delayed and delayed implants). *Cochrane Database Syst Rev.* 2010; CD005968.
- Harvey BV. Optimizing the esthetic potential of implant restorations through the use of immediate implants with immediate provisionals. *J Periodontol.* 2007; 78: 770-776.
- Wohrle PS. Single-tooth replacement in the aesthetic zone with immediate provisionalization: fourteen consecutive case reports. *Pract Periodontics Aesthet Dent.* 1998; 10: 1107-1114.
- Schoenbaum TR, Han TJ. Direct custom implant impression copings for the preservation of the pontic receptor site architecture. *J Prosthet Dent.* 2012; 107: 203-206.
- De Rouck T, Collys K, Cosyn J. Single-tooth replacement in the anterior maxilla by means of immediate implantation and provisionalization: a review. *Int J Oral Maxillofac Implants.* 2008; 23: 897-904.
- De Rouck T, Collys K, Cosyn J. Immediate single-tooth implants in the anterior maxilla: a 1-year case cohort study on hard and soft tissue response. *J Clin Periodontol.* 2008; 35: 649-657.
- Kan JY, Rungcharassaeng K, Lozada J. Immediate placement and provisionalization of maxillary anterior single implants: 1-year prospective study. *Int J Oral Maxillofac Implants.* 2003; 18: 31-39.
- Cochran DL. The evidence for immediate loading of implants. *J Evid Based Dent Pract.* 2006; 6: 155-163.
- Salama H, Rose LF, Salama M, Betts NJ. Immediate loading of bilaterally splinted titanium root-form implants in fixed prosthodontics--a technique reexamined: two case reports. *Int J Periodontics Restorative Dent.* 1995; 15: 344-361.
- Randow K, Ericsson I, Nilner K, Petersson A, Glantz PO. Immediate functional loading of Branemark dental implants. An 18-month clinical follow-up study. *Clin Oral Implants Res.* 1999; 10: 8-15.
- Tarnow DP, Emtiaz S, Classi A. Immediate loading of threaded implants at stage 1 surgery in edentulous arches: ten consecutive case reports with 1- to 5-year data. *Int J Oral Maxillofac Implants.* 1997; 12: 319-324.
- Atieh MA, Payne AG, Duncan WJ, Cullinan MP. Immediate restoration/loading of immediately placed single implants: is it an effective bimodal approach? *Clin Oral Implants Res.* 2009; 20: 645-659.
- Vandeweghe S, Nicolopoulos C, Thevissen E, Jimbo R, Wennerberg A, De Bruyn H. Immediate loading of screw-retained all-ceramic crowns in immediate versus delayed single implant placement. *Int J Prosthodont.* 2013; 26: 458-464.
- Khzam N, Arora H, Kim P, Fisher A, Mattheos N, Ivanovski S. Systematic Review of Soft Tissue Alterations and Esthetic Outcomes Following Immediate Implant Placement and Restoration of Single Implants in the Anterior Maxilla. *J Periodontol.* 2015; 86: 1321-1330.
- Saito H, Chu SJ, Reynolds MA, Tarnow DP. Provisional Restorations Used in Immediate Implant Placement Provide a Platform to Promote Peri-implant Soft Tissue Healing: A Pilot Study. *Int J Periodontics Restorative Dent.* 2015; 36: 47-52.
- Margeas RC. Predictable periimplant gingival esthetics: use of the natural tooth as a provisional following implant placement. *J Esthet Restor Dent.* 2006; 18: 5-12.