



New Pull Through Resection Technique in Tongue and Floor-of Mouth Cancers

Nermin Başerer*

Department of Otolaryngology, İstanbul University, İstanbul, Turkey

Editorial

Oral cavity cancers are the sixth most common of all cancers. Tongue and Floor-of-Mouth Cancers (TFMC) often coexistent and most frequent (30% to 60%) tumors of the oral cavity. Despite all improvement in treatment modalities, adequate levels of cure rate have not been achieved. Surgery is the main treatment option in these cancers. In the early stage (T1 N0, T2 N0) TFMC surgery or radiotherapy are alternative treatments. In the late stage, surgery and adjuvant radiotherapy with or without chemotherapy is the only choice. Elective and curative neck dissections are routinely applied in all cases according to the neck status.

Trans oral resection with trans oral approach is the most commonly used technique in early stage of TFMC. This technique should be discussed in terms of oncology. Observations and the experience of the high rate recurrence up to 30% of trans oral local resection led us to more secure radical surgery. Para hyoid region contains muscle fibers, vascular, lymphatic and neural channels carrying tumor cells, so it is the most common zone of early recurrence. This area can not be reached by trans oral approach, and also not be included into the neck dissection specimen. Therefore, this region must be removed to prevent early recurrence (Figure 1). Surgical procedures of TFMC should be least possibly morbid, but oncologically safe. Therefore, we have modified the pull through techniques for the least morbidity. We have used our technique for over 20 years as an alternative to trans oral resection. Our technique can be applied to all TFMC without mandibular invasion. Mandibulotomy, lip splitting or lip checks flap are not performed in our technique. Therefore, facial scarring, or hypoesthesia, anesthesia due to mental nerve injury and mandibulotomy complications were prevented. However, these problems of morbidity are the disadvantages of the other pull through techniques. We use trans oral, trans cervical submandibular route for adequate vision. Resection of tumor is initiated by trans oral approach. Resections on the horizontal plane, detachment of the tumor mass from mandible are firstly performed. Three dimensional radical resection is completed by trans cervical submandibular approach on the hyoid as pull through (Figure 2a-c).

Reconstruction is essential in this technique. In the moderate defect sterno cleido mastoid (SCM) muscular flap is the least morbid and easy. It is the first choice in T1 of TFMC. In the voluminous defects, pectoralis major myocutaneous (PMMC) flaps or radial forearm free flaps

OPEN ACCESS

*Correspondence:

Nermin Başerer, Department of Otolaryngology, İstanbul University, İstanbul, Turkey,
E-mail: nerminbaserer@hotmail.com

Received Date: 02 Jun 2017

Accepted Date: 10 Jul 2017

Published Date: 12 Aug 2017

Citation:

Başerer N. New Pull Through Resection Technique in Tongue and Floor-of Mouth Cancers. *J Dent Oral Biol.* 2017; 2(10): 1069.

ISSN: 2475-5680

Copyright © 2017 Nermin Başerer.

This is an open access article distributed under the Creative Commons Attribution License, which permits unrestricted use, distribution, and reproduction in any medium, provided the original work is properly cited.

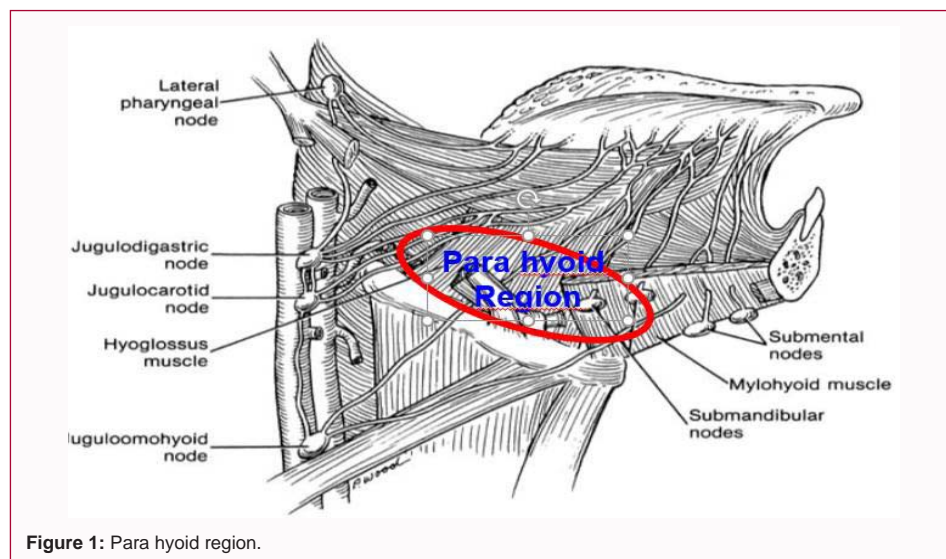


Figure 1: Para hyoid region.

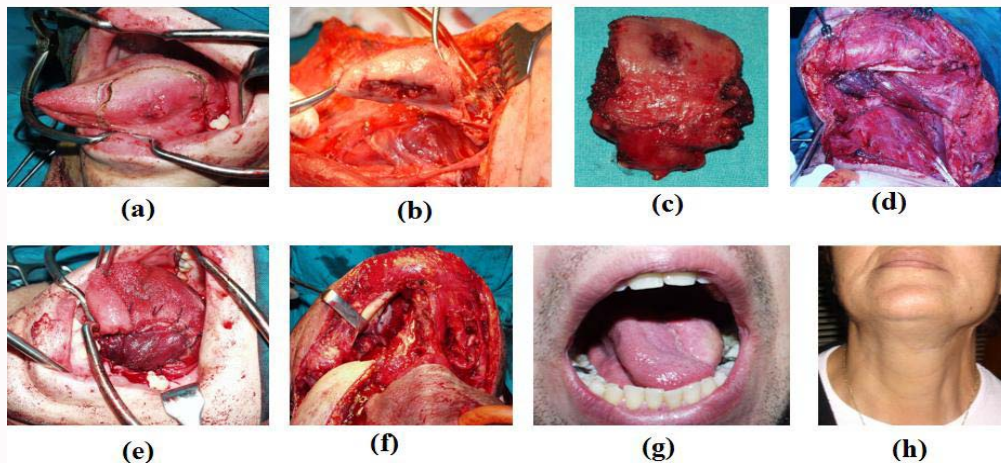


Figure 2: (a) Trans oral phase and horizontal plane resection, (b) Submandibular pull through, (c) Tumor resection specimen, (d) SCM muscular flap, (e) Reconstruction of oral cavity defect with SCM flap, (f) Reconstruction with PMMC flap, (g) View of tongue after reconstruction with PMMC flap, (h) View of patient after pull through resection.

are commonly preferred (Figure 2d-g). We have prepared a study comparing the oncologic, functional, clinical follow up and cosmetic results obtained in the T1 -T2 stages of TFMC to trans oral resection. Within a total of 49 cases of T1-T2 stages of TFMC, 22 patients were in T1, and 27 were in T2 stage. In the pull through resection group, there were 10 patients in T1 and 16 in T2 stage. In trans oral resection group, 12 patients were in T1, and 10 patients were in T2 stage. The recurrence rate was 26% in patients treated with trans oral resection, whereas 3.8% in patients who underwent pull through resection.

Despite the important oncologic differences, there was no significant difference concerning function and cosmetics [1]. We conclude that, the pull through resection is oncologically safe and minimal morbid technique in surgical treatment of TFMC (Figure 2h).

Reference

1. Başerer N, Damar M. Pull-through resection and peroral resection in early-stage (T1 and T2) tongue and floor of the mouth cancers: a comparison of two techniques. *Kulak Burun Bogaz Ihtis Derg.* 2011;21(6):305-11.