Journal of Cancer Clinics

Case Report
Published: 11 Jan, 2021

New in the Formation of Areflux Esophagojejunostomy after Gastrectomy

Martynov VL[1], Kolchin DG[2], Rulev VN[2], Trukhalev VA[2] and Kurilov VA[2]*

[1]*Department of Medical Sciences, National Research Nizhny Novgorod State University Named after N.I. Lobachevsky (UNN), Russia*

[2]*Department of Surgery, City Clinical Hospital No. 12, Russia*

Abstract

Underestimation of the development of reflux esophagitis after gastrectomy, the shortcomings of the Roux technique during the formation of esophagojejunostomy leads to a sharp deterioration in the quality of life of patients with the possible development of an oncological process in the esophagus. Creation of an areflux esophagojejunoanastomosis with the formation of a developed "plug" on the adductor and interintestinal anastomosis is the prevention of these pathological processes.

Keywords: Gastrectomy; Areflux esophagojejuno-anastomosis; "Plug" on the adductor loop

Introduction

The current stage in the development of gastric surgery is characterized by a critical assessment of the long-term results of gastrectomy and the search for new, physiological technical aspects of the operation [1].

Surgical techniques are aimed not only at eliminating the disease, but also at maximizing the replacement of the function of the removed organ. However, the results obtained are not always satisfactory, so the search continues for a method that will help to avoid or reduce mortality, the number of complications in both the early and late postoperative period [2,3].

Most of the methods for the formation of the esophageal-intestinal anastomosis are aimed at increasing their reliability and do not provide for the creation of an antireflux mechanism that provides physiological, portioned evacuation of food [4].

Prevention of functional disorders after gastrectomy is assessed as an exceptional parameter for improving the quality of life of patients who have undergone an already complex surgical intervention [5].

A study of the long-term consequences of gastrectomy carried out by many authors' shows that a significant number of operated patients, at various times after the intervention, develop a number of functional and organic disorders [6].

Based on the analysis of the results of surgical treatment of patients with gastric cancer, it can be seen that the development of new antireflux techniques for the formation of esophagoentero and esophagogastrostomy is a promising direction in the surgical treatment of this category of patients, allowing improving the quality of life of patients [7].

For internal drainage of the hollow organs of the abdominal cavity and cavity formations of the retroperitoneal space, the Roux-isolated loop of the small intestine is most often used, which is the "gold standard". But this method of drainage has its drawbacks, which affect the immediate and late postoperative periods, the development of functional and organic complications, and the quality of life of patients. Therefore, the development of new approaches to solving these problems is urgent.

We have improved the approach to drainage of the hollow organs of the abdominal cavity and cavity formations of the retroperitoneal space with the creation of an interintestinal anastomosis with the formation of a "plug" developed in the clinic on the adductor loop of the small intestine (Figures 1-3).

The data of the scientific calculation made justify the practical performance of the operation by the surgeons without compressing the intestinal wall:

OPEN ACCESS

Correspondence:
Martynov Vladimir Leonidovich, Department of Medical Sciences, National Research Nizhny Novgorod State University Named after N.I. Lobachevsky (UNN), 603033, Nizhny Novgorod, ul. Zaprudnaya, 3 - 176; t.s. 89049188600, tr. 2256629, Russia, E-mail: hirurgia12@mail.ru

Received Date: *27 Nov 2020*
Accepted Date*: 06 Jan 2021*
Published Date*: 11 Jan 2021*

Citation:
Martynov VL, Kolchin DG, Rulev VN, Trukhalev VA, Kurilov VA. New in the Formation of Areflux Esophagojejunostomy after Gastrectomy. J Cancer Clin. 2021; 2(1): 1008.

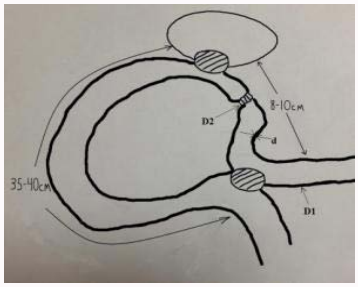

Figure 1: Scheme of drainage of the cavity formation of the abdominal cavity or retroperitoneal space using a "plug".

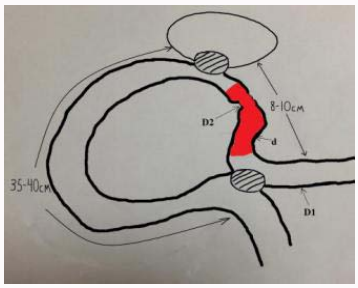

Figure 2: The area of the small intestine that does not pass chyme (painted over).

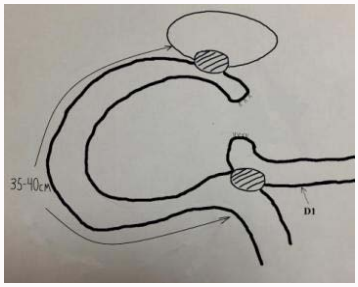

Figure 3: A mentally distant section of the intestine that does not pass chyme - a variant of the method of drainage according to Ru.

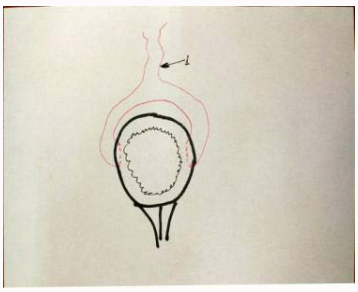

Figure: 4 Scheme of ligation (1) through the serous-muscular membrane at 3 and 9 hours.

- Injections at 3, 9 o'clock in relation to the mesentery of the intestine in the place of the supposed "plug" impose a serous-muscular suture (Figure 4).
- On both sides, 1 cm from the first seam, one more similar seam is applied (Figure 6).
- Separately tie the ends of the suture threads, invaginate the antimesenteric wall of the intestine until it touches the mesenteric wall (Figures 7-11).
- From a strand of a free omentum and a non-absorbable ligature passed through it, we form a developed "plug", the diameter of which is equal to the diameter of the invaginated section of the intestine, tying the ends of the thread, which determines the anatomical constancy of the created structure (Figure 10).

Figure 5: Photo of ligation through the serous-muscular membrane at 3 and 9 o'clock.

Figure 6: Photo of carrying out three ligatures through the serous-muscular membrane at 3 and 9 o'clock.

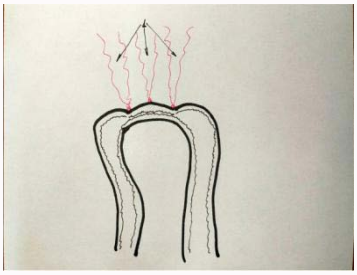

Figure 7: Scheme of approaching the antimesenteric wall to the mesenteric wall with three ligatures (1).

Figure 8: Photo of the approach of the antimesenteric wall to the mesenteric wall by three ligatures.

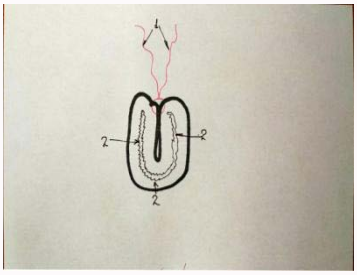

Figure 9: The intestinal lumen (2) was eliminated by invaginating sutures (1).

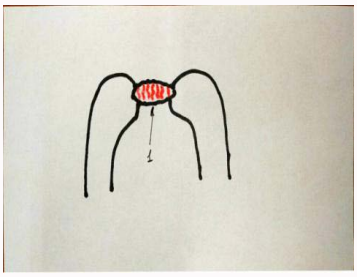

Figure 10: Scheme - the line of invaginating sutures is fixed with a free strand of an omentum with a ligature (1).

Thus, during internal drainage of cavities in the abdominal cavity and retroperitoneal space, a "plug" has been developed for the small bowel adductor loop, which excludes compression, ischemia (proven by microcirculation studies) and necrosis of the intestinal wall with subsequent migration of the created structure into the lumen of the gastrointestinal tract and determines planned areflux effect.

Case Presentation

Here is a clinical example. Patient B 56-year-old, was admitted to the hematology department of the GBUZ NO "GKB No. 12" 08.12.2011, with a diagnosis of diffuse beta-cell lymphoma of the stomach; progression; Art. Exacerbation; hypertension 2 tbsp., uncomplicated, risk 3; mixed myocardial dystrophy ". EGD was performed on 13.12.2011: The esophagus was freely passable; the mucous membrane was pale pink. On the walls - dark red clots. The stomach expands with air. Peristalsis is alive in all departments. The stomach is ½ filled with dark red clots. In the lower third of the body along the lesser curvature with a transition to the posterior wall, there is an irregularly shaped flat ulcer with an infiltrative shaft measuring 4 cm × 5 cm. In the center is a thrombosed vessel.

Conclusion: gastric lymphoma complicated by ongoing bleeding. The threat of bleeding remains.

13.12.2011 due to recurrent bleeding, the patient is transferred to the intensive care unit, where hemostatic and heme-replacement therapy is performed.

FGDS - control (12/19/2011): No positive dynamics was detected. The threat of bleeding remains.

FGDS - control (12/21/2011): No positive dynamics was found. The entire surface of the tumor is covered with a large, loose thrombus. No leaks of fresh blood were found at the time of examination. The threat of recurrent bleeding.

On 22.12.2011 due to recurrent bleeding the patient was urgently operated. Operation - gastrectomy, Upper median laparotomy.

Figure 11: Photo - the line of invaginating sutures is fixed by a free strand of an omentum with a ligature.

Figure 12: Formed "plug" through which the chyme should not pass, and interintestinal anastomosis according to Brown.

During the revision of the abdominal organs, bile began to flow from under the hepatic space. On the front wall of the lower third of the body of the stomach, a perforation up to 2 cm in diameter is determined, from where bile and altered blood come from. The perforation is sutured with interrupted sutures. The abdominal cavity is washed with 3 liters of saline sodium chloride solution. Under the liver, on the greater omentum - fibrin deposits, it was concluded that there is a covered perforation of the tumor with a breakthrough into the free abdominal cavity. On the front wall of the body of the stomach, a tumor-like formation up to 8 cm in diameter is palpated, in the center there is a sutured perforation. Given the rapid increase in the size of the tumor, an increase in ulceration, it is impossible to exclude the defeat of other parts of the stomach, which determines the greater likelihood of failure of possible anastomosis of the stomach with the intestine. Therefore, it was decided to perform a gastrectomy.

Mobilization of the stomach

The duodenum is stitched by the UKL -60 1 cm below the pylorus. The stomach was cut off from the duodenum 12. The stump of the duodenum 12 is additionally immersed with two semi-string sutures. The stomach is cut off from the esophagus. Elimination of the existing paroxysmal peritonitis, dissection of Treitz's ligament to reduce hypertension in the stump of 12 duodenal ulcer. A loop of the jejunum was drawn behind the transverse colon, taken 50 cm from Treitz's ligament. Esophagojejuno anastomosis is imposed end-to-side with a two-row interrupted suture. The first line of the anastomosis is reinforced with a tachocomb. The anastomotic area is covered with an adductor loop. Below the root of the transverse colon, an anastomosis is formed between the adductor and discharge loops of the jejunum relative to the esophagojejunostomy. Above the interintestinal anastomosis, a “plug” was applied to the adductor loop in the modification of the chair (Figure 12).

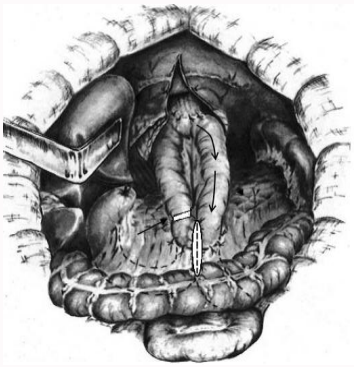

Figure 13: Scheme of the formation of a reflux esophagoenteroanastomosis using a "plug".

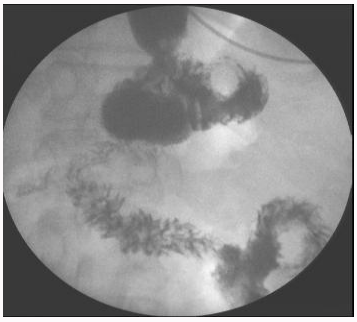

Figure 14: Barium reaches the zone of the "plug" of the adducting section without penetrating it, passes through the loop of the small intestine that takes off from the esophagoenteroanastomosis.

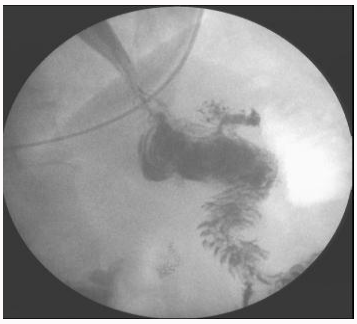

Figure 15: After a few seconds, the bulk of barium left the zone of the esophageal-intestinal anastomosis does not pass through the "plug" zone.

Through counter-openings to the area of esophagojejunostomy, to the spleen, to the small pelvis, catching drains are brought. Layered suture of the wound Ac. sticker.

Drug: Stomach

In the lower third of the body of the stomach, an ulcerated tumor of 8 cm in diameter with a perforation up to 2 cm in diameter is determined.

Histological examination 14776/92 from 26.12.11: Deep chronic penetrating gastric ulcer, with exacerbation. The bottom of the ulcer is represented by the proliferation of fibrous and granulation tissue. In regional lymph nodes - reactive lymphoid hyperplasia of acute lymphadenitis. There are no data for the presence of gastric lymphoma within the studied material.

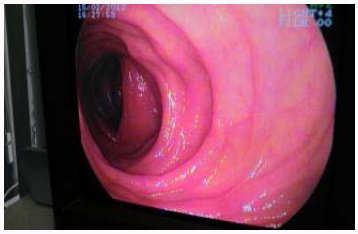

Figure 16: The mucous membrane of the esophagus in the middle third is pink, without signs of inflammation. Vascular pattern is traced.

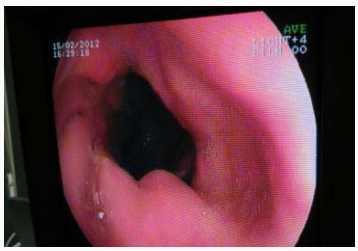

Figure 17: The mucous membrane of the esophagus near the esophagojejunostomy is pink in color, without signs of inflammation. No signs of anastomosis were found.

Figure 18: Esophagojejunoanastomosis decreased, bile flow is not observed, vascular pattern is traced. No signs of anastomosis were found.

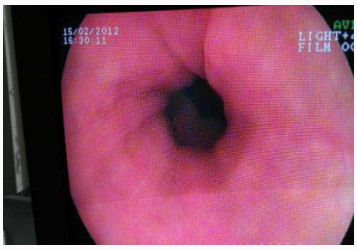

Figure 19: Esophagojejunoanastomosis decreased even more, took a rounded shape, there is no bile flow.

Figure 20: The area of the leading and outgoing loops. A month after the operation, complete epithelialization of the anastomotic area is noted. No bile discharge was detected. No signs of anastomosis were found.

Postoperative diagnosis

Lymphoma of the lower third of the 3rd body of the stomach, complicated by bleeding and covered perforation, local peritonitis.

P/o period is smooth. On 10.02.2012 the patient was transferred for further treatment to the hematology department, from where she was discharged on 25.02.2012, for outpatient treatment.

From 31.01.2012 to 16.02.2012 was again in the hematology department for cytostatic treatment (case history No. 969).

On 16.02.2012, an X-ray of the esophagus was performed: the esophagus is passable. Condition after gastrectomy we are undergoing anastomosis. The small intestine was normal. The evacuation is timely. A series of X-ray images did not reveal the passage of barium through the segment of the small intestine in the place of the formed "plug". The contrast goes to the adducting section of the small intestine only up to the "plug" zone. The main part of the contrast goes through the efferent gut (Figure 14,15). Thus, it has been proven that the esophagus is isolated from the damaging effects of bile, 12-PC digestive juices and the pancreas.

On February 15th, 2012, a control EGD was performed: the state after gastrectomy with the imposition of an esophagojejunostomy with the formation of an interintestinal anastomosis according to Brown and a "plug" on the adductor loop. The mucous membrane of the esophagus is pink; the vascular pattern can be traced. Anastomosis is freely passable. Function - no pathology. A biopsy specimen was taken from the anastomotic area and the lower third of the esophagus (Figures 16-20).

References

1. Xiong JJ, Altaf K, Muhammad AJ, Quentin MN, Huang W, Gang Mai, et al. Roux-en-Y versus Billroth I reconstruction after distal gastrectomy for gastric cancer: A meta-analysis. World J Gastroenterol. 2013;19(7):1124-34.
2. Osugi H, Fukuhara K, Takada N, Takemura M, Kinoshita H. Reconstructive procedure after distal gastrectomy to prevent remnant gastritis. Hepatogastroenterology. 2004;51(58):1215-8.
3. Shinoto K, Ochiai T, Suzuki T, Okazumi S, Ozaki M. Effectiveness of Roux-en-Y reconstruction after distal gastrectomy based on an assessment of biliary kinetics. Surg Today. 2003;33(3):169-77.
4. Kagan, New methods of microsurgical biliodigestive anastomoses with sphincter properties: Experimental rationale and clinical experience. Materials of the 21st Congress of surgeons of the Russian Federation May 25–27. 2011; Volgograd:150-1.
5. Tarasenko SV. Nosological structure of obstructive jaundice syndrome. Ann Surg. 2012;1:63-7.
6. Nunobe S, Okaro A, Sasako M, Saka M, Fukagawa T, Katai H, et al. Billroth 1 versus Roux-en-Y reconstructions: a quality-of-life survey at 5 years. Int J Clin Oncol. 2007;12(6):433-9.
7. Novikov EA. Experience of surgical treatment of patients with gastric cancer with the formation of esophageal anastomoses. Int Med J. 2011;2:40-42.