



Natural Orifice Specimen Extraction in Laparoscopic Radical Cystectomy: Initial Report

Marcos Tobias*

Department of Urology, ABC Medical School and Brazilian Institute of Cancer Control, Brazil

Abstract

Introduction: The use of laparoscopic procedures is widespread and well documented in Urology. Advances such as decreased use of analgesics and shorter length of stay can be disrupted by an abdominal incision. Natural Orifice Specimen Extraction (NOSE) can be a powerful allied to minimize complications. Minimally invasive radical cystectomy increased importance and decreased side effects, despite still being usual, specially related its wound. NOSE in Urology does not focus on transanal extraction, focus of this report.

Objective: Present initial experience of laparoscopic radical cystectomy with transanal specimen extraction.

Methods: Between January 2016 and February 2017, five patients, all male, with hi-grade muscle invasive tumor previously evidenced on TURB with important comorbidities and low performance status were enrolled. Previous CT showed no signs of metastasis. Cutaneous ureterostomy was chosen as the diversion method, including simplified pelvic bilateral lymphadenectomy.

Surgical technique: After bowel preparation including manitol and cefoxitine, five trocars, three 12 mm trocars and two 5 mm were inserted to the abdomen, observing the same position usually used to laparoscopic radical prostatectomy. Deep venous control was followed by ureters isolation and bilateral preservation up to the bladder insertion. Bladder vascular control used both polymeric clips and harmonic scalpel, also used to achieve final specimen release. A Right after, a single 5 cm vertical incision was done towards sigmoid taeniae and an 15 mm endoscopic bag was inserted, packed the specimen and was gently extracted. Taeniae repair was performed using a 60 mm stapler with reinforcement stitches. Ureters were placed outside through the 5 mm ports.

Results: Total surgical procedure time had an average of 180 min, including median of 25 min of specimen extraction and sigmoid reconstruction. Length of Stay (LOS) had a median of 3 days, with early food intake initiated right after signs of bowel peristalsis.

Discussion: Laparoscopic radical cystectomy is a powerful tool to decrease postoperative complications. Its use in association with NOSE can be an even better strategy, leading to shorter LOS, avoiding external organ exposition and decreased use of analgesics. Proctology literature has a better experience using NOSE on Oncology, evidencing promising data.

Conclusion: The use of NOSE concept is a promising area that needs further studies to prove and replicate the findings on this issue and be used not only for cutaneous ureterostomy, but also to other forms of urinary diversion.

Keywords: Ureters; Cutaneous ureterostomy; Specimen extraction; Laparoscopic radical cystectomy

Introduction

The use of pure laparoscopic in urological procedures is widespread and well documented in Urology literature. Shorter length of hospital stay, decreased use of analgesics and faster recovery process are real, however, an abdominal incision can disrupt these advantages. In order to minimize these effects, Natural Orifice Specimen Extraction Technique (NOSE) may be a powerful allied to minimize wound complications [1,2]. Radical cystectomy is the gold standard procedure for muscle invasive bladder cancer. Minimally invasive radical cystectomy has gained importance, during the past 20 years, mainly due to less blood loss and transfusions, however its post-operative complications are quite usual and all efforts to decrease complications, including abdominal wall strategies are welcome and should be studied [3]. The use of NOSE in Urology for large pieces, such

OPEN ACCESS

*Correspondence:

Marcos Tobias, Department of Urology,
ABC Medical School and Brazilian
Institute of Cancer Control, Brazil,
E-mail: tobias-machado@uol.com.br

Received Date: 01 Sep 2019

Accepted Date: 15 Oct 2019

Published Date: 22 Oct 2019

Citation:

Tobias M. Natural Orifice Specimen
Extraction in Laparoscopic Radical
Cystectomy: Initial Report. *Ann Clin
Surg.* 2019; 1(1): 1002.

Copyright © 2019 Marcos Tobias. This
is an open access article distributed
under the Creative Commons Attribution
License, which permits unrestricted
use, distribution, and reproduction in
any medium, provided the original work
is properly cited.

Table 1: Duration of surgeries, complications of patients and length of stay.

Patient	Age years	Surgery Duration (min)	Patient Complication	Length of Stay (days)	Cancer staging
1	70	160	-	2	2
2	75	220	wound seroma in a 12 mm trocar	4	3
3	78	180	-	2	3
4	80	170	-	3	2
5	85	200	Atelectasis	5	2

as kidney or large tumoral specimens is focused on transvaginal access [4]. Use of colonic incision for tactical extraction is barely unknown and not utilized by urological surgeons. This article has the objective to present the initial experience of laparoscopic radical cystectomy with transanal specimen extraction and cutaneous ureterostomy performed on 5 patients.

Materials and Methods

Patient and diversion selection

A total of 5 patients, all male, with hi-grade muscle invasive tumor evidenced after previous endoscopic bladder resection (TURB) with important comorbidities and low performance status were enrolled. Pre operative CT scan showed no evidence of metastasis. Besides, to avoid excess of sutures and decrease fistula risk, cutaneous ureterostomy was performed and just simplified pelvic lymph node pelvic bilateral was performed. Surgeries were performed between January 2016 and December 2017. The Institution’s Ethics Committee approved this report.

Surgical technique

Twenty four hours before procedure bowel preparation was performed with manitol and cefoxitine: Patient was positioned in modified lithotomy position. Five trocars were used, starting 12 mm super-umbilical to introduce the laparoscope, two 12 mm on the Para rectal space bilaterally and 15 mm port on each low quadrant, quite similar to the position of a laparoscopic radical prostatectomy. Thereafter, patient is adjusted to Trendelenburg position [5-7] (Figure 1).

Firstly, posterior access to vas deferens and seminal vesicles is gained, with complete dissection of these structures, Denonvilliers’ fascia opening and posterior dissection from prostate reaching posterior urethra. After that, Retzius Space was dissected and anterior access to prostate was created. Endopelvic fascia was opened bilaterally and hemostatic Santorini vascular bundle was placed with vicryl 0. Once the anterior site was done, then, ureter was identified and dissected with care to avoid vascular injury up to its insertion in bladder. Once both were carefully dissected, both were ligated just above bladder insertion and then, cut.

Bladder vascular bundles were then dissected and ligated using purple vascular clips (Hem-o-lok®) and ultrasonic scalpel, finishing bladder extraction.

Once the specimen was released, a 5 cm length incision was performed across sigmoid taeniae with gentle insertion of a 15 mm endoscopic bag. Once packed, bladder was then packed and gently extracted. The opened sigmoid was then repaired with single Vicryl stitches on its edges. Soft traction was provided. A 60 mm laparoscopic stapler was the placed, covering the entire opened area. Additional reinforcement sutures were done with Vicryl 3.0, covering the entire area. Simple bilateral lymph node dissection was then done and pieces

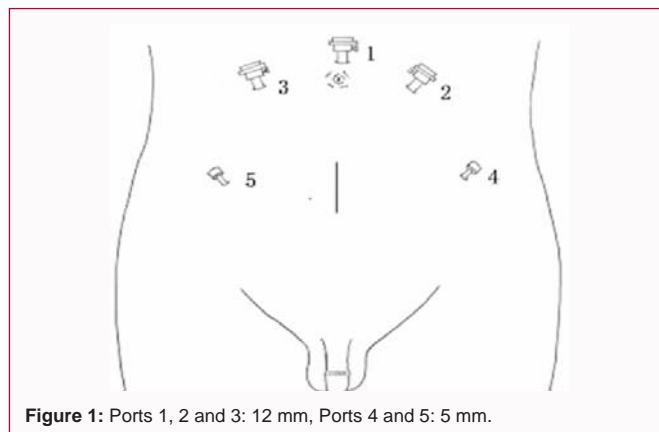


Figure 1: Ports 1, 2 and 3: 12 mm, Ports 4 and 5: 5 mm.

were extracted trough the trocars with grasper forceps. Ureters were guided out the abdomen trough the 5 mm trocars and spatulated and fixed to skin and a 6FR ureteral stent was placed and attached to skin. Finally, cavity was drained with a Silicon Penrose device.

Results

Surgeries took around 180 min (160-220), including median 25 min (15-30) to specimen extraction and sigmoid reconstruction. Length of stay had a median of 3 days (2-5), with no patient presenting major complications. Two patients presented minor complications, solved during stay, (Table 1).

No signs of fistula were identified or reoperations, needed. Food intake was firstly introduced as soon as bowel peristalsis was present. Liquid low fat intake was introduced and kept for at least one week.

Final pathology specimen analysis evidenced 3 T2 and 2 T3 transitional bladder carcinomas with no margin compromise. No adjuvant or neoadjuvant chemotherapy was prescribed.

Discussion

Laparoscopic resection of bladder is an important tool for decrease blood loss and length of stay for patients. However, it demands skillfully surgeons and an association with NOSE are barely studied. Bladder extraction through sigmoid has no literature evidence in Urology. Proper data can be adapted from the results applied in Proctology which are quite promising, stating less post operative pain, less chance of incisional hernia and a faster recovery besides protecting the organs from exposition to external environment [8-10]. The sigmoid opening just at the taeniae is an widespread concept brought mainly by sigma rectum pouch, which, in addition to experimental studies made in horses, evidenced less chance of stricture in suture and less inflammatory response when compared to incisions made close to taeniae itself [11,12].

This technique applied to bladder extraction begins to state that can be a feasible and safe tactic that should be learned and studied

with more attention by the urologists, especially regarding the potential side effects of radical cystectomy, specially regarding wound management and complication, such as eventration or evisceration.

Conclusion

Radical cystectomy remains as the gold standard procedure for muscle invasive bladder cancer. However, usually results in serious complications, including abdominal wall issues. The use of NOSE concept is a promising area that needs further studies to prove and replicate the findings on this issue and be used not only for cutaneous ureterostomy, but also to other forms of urinary diversion.

References

1. Ma B, Huang XZ, Gao P, Zhao JH, Song YX, Sun JX, et al. Laparoscopic resection with natural orifice specimen extraction versus conventional laparoscopy for colorectal disease: A meta-analysis. *Int J Colorectal Dis.* 2015;30(11):1479-88.
2. Kayaalp C, Yagci MA, Soyer V. Laparoscopic and natural orifice transluminal restorative proctocolectomy: no abdominal incision for specimen extraction or ileostomy. *Wideochir Inne Tech Maloinwazyjne.* 2016;11(2):115-20.
3. Palazzetti A, Sanchez-Salas R, Capogrosso P, Barret E, Cathala N, Mombet A, et al. Revisión sistemática de resultados perioperatorios y complicaciones después de cistectomía radical abierta, laparoscópica y asistida por robot. *Actas Urol Esp.* 2017;41(7):416-25.
4. Firaza PN, Lorenzo EI, Bardelosa JG 3rd, Patron Na, Reyes EL. Hybrid Natural Orifice Transluminal Endoscopic Surgery Transvaginal Nephrectomy in a low Resource Setting. *J Laparoendosc Adv Surg Tech A.* 2016;26(2):99-102.
5. Wein Alan J, Louis R Kavoussi, Meredith F. Campbell-Walsh Urology. 11th ed. Philadelphia, PA: Elsevier Saunders; 2016.
6. Smith JA, Howards SS, Preminger GM, Hinman F. Hinman's Atlas of urologic surgery. 3rd ed. Philadelphia, PA: Elsevier Saunders. 2012.
7. Huang J, Lin T, Xu K, Huang H, Jiang C, Han J, et al. Laparoscopic radical cystectomy with orthotopic ileal neobladder: a report of 85 cases. *J Endourol.* 2008;22(5):939-46.
8. Nishimura A, Kawahara M, Suda K, Makino S, Kawachi Y, Nikkuni K. Totally laparoscopic sigmoid colectomy with transanal specimen extraction. *Surg Endosc.* 2011;25(10):3459-63.
9. Palanivelu C, Rangarajan M, Jategaonkar PA, Anand NV. An innovative technique for colorectal specimen retrieval: a new era of "natural orifice specimen extraction" (NOSE). *Dis Colon Rectum.* 2008;51(7):1120-4.
10. Akiyoshi T, Kuroyanagi H, Oya M, Konishi T, Fukuda M, Fujimoto Y, et al. Short-term outcomes of laparoscopic rectal surgery for primary rectal cancer in elderly patients: is it safe and beneficial? *J Gastrointest Surg.* 2009;13(9):1614-18.
11. Fisch M, Wammack R, Müller SC, Hohenfellner R. The Mainz pouch II (sigma rectum pouch). *J Urol.* 1993;149(2):258-63.
12. Beard WL, Robertson JT, Getzy DM. Enterotomy technique in the descending colon of the horse. Effect of location and suture pattern. *Vet Surg.* 1989;18(2):135-40.