



Myelofibrosis Diagnosed Through the Explant Liver Way!

Nalini Bansal^{1*}, Vivek Vij¹ and Mukul Rastogi²

¹Fortis Escorts Heart Institute, India

²Fortis Hospital, India

Abstract

Cryptogenic Chronic Liver Disease (CLD) remain an important cause of chronic liver disease where no etiological inciting agent could be attributed to causation of disease, with recent advances in diagnostic testing the prevalence of cryptogenic CLD have decreased though not completely eliminated. We report a case of a 45-year-old female who underwent combined liver and kidney transplant for cryptogenic chronic liver and kidney disease. Her explant liver pathology revealed extensive extramedullary hematopoiesis with many atypical megakaryocytes and advance fibrosis. She subsequently underwent bone marrow aspiration and biopsy and was finally diagnosed as a case of primary myelofibrosis. Post transplant her platelet count peaked to 12 lakhs and she was started on hydroxyurea. Her platelets became normal following 2 weeks of therapy and dropped to about 4 lakhs.

Introduction

Cryptogenic chronic liver disease includes liver disease where underlying etiology remains obscure despite extensive clinical, serological and pathological evaluation. With the advances in medicine many of these cases are now attributed to NASH/viral and other etiologies. However, the prevalence is still around 5% of all cases. Myelofibrosis presenting as chronic liver and kidney disease is extremely uncommon. We herein report first case of myelofibrosis presenting as chronic liver and kidney disease due to marked extramedullary hematopoiesis and fibrosis and subsequently being diagnosed through explant liver pathology.

Case Presentation

We report a case of a 45 year old female from Myanmar diagnosed to have chronic kidney disease since two years requiring dialysis every second day, was evaluated and also found to have chronic liver disease with hepatitis B infection on routine check-up. There was no history of SBP/ GI Bleed/HE/Ascitic tapping.

There is no history of diabetes/ asthma/ tuberculosis or chronic obstructive pulmonary disease. She had history of hypertension and was on regular medication. She also had history of receiving treatment for infertility. There was history of hysterectomy about a year back due to menorrhagia. There was no history of drug allergy and she was a non-smoker and non-alcoholic.

Her physical examination revealed height/weight/BMI: 152 cm/59.2 kg / 25.54 kg/m².

Her lab investigations showed Hb/PCV-8.3/26.2 (13.0 g/dl to 17.0 g/dl), TLC 4.26 (4000/ml to 10000/ml). PT/INR 13.9/1.15 (11.4 sec to 13.7 sec/0.00-1.40 sec). Liver function tests were deranged with elevation of SAP/SGT. Bilirubin/direct-0.81/0.45 (0.00 mg/dl to 1.00 mg/dl/ 0.00 mg/dl to 0.30 mg/dl), SGOT-23 (15 U/L to 37 U/L), SGPT 31(30 U/L to 65 U/L), SAP 300 (50 U/L to 136 U/L), SGGTP 455 (5 U/L to 85 U/L), Protein 8 (6.4 g/dl to 8.2 g/dl), albumin 3.1 (3.4 g/dl to 5.0 g/dl), BUN 69 (6 mg/dl to 20 mg/dl), creatinine 10.78 (0.9 g/dl to 1.3 mg/dl), Na 138 (136 mmol/l to 145 mmol/l), K 5.3 (3.5 mmol/l to 5.10 mmol/l), chloride 101 (98 mmol/l to 107 mmol/l), magnesium 2.5 (1.8 mg/dl to 2.4 mg/dl), T3, T4,TSH-2.1/81.75/9.95. Lipid profile was normal. HBsAg-non reactive, Hepatitis B Core antibody-Reactive 1.67, HBV DNA Quantitative- <20 , Anti HCV Antibdy-negative, HIV I and II-Negative, CMV IgG positive >8.43 (IgM 0.49), Total IgG-16.2, ANA Negative, AFP-2.54, CEA-2.72, CA19.9- <1.2, CA125 43.9, Urine routine showed Protein +++, WBC-5-7, Bacteria +++++.

Chest X Ray revealed subtle haziness in the right lower zone-suggestive of right lung consolidation. Rest of the both lung fields appears normal.

CT Angiography could not be performed in view of kidney disease. Liver Doppler showed

OPEN ACCESS

*Correspondence:

Nalini Bansal, Senior Histopathologist,
SRL Ltd, Fortis Escorts Heart Institute,
Okhla Road, New Delhi, India, Tel:
9990370677;

E-mail: drnalinibansal@yahoo.com

Received Date: 16 May 2018

Accepted Date: 10 Jul 2018

Published Date: 17 Jul 2018

Citation:

Bansal N, Vij V, Rastogi M.
Myelofibrosis Diagnosed Through the
Explant Liver Way!. *Ann Digest Liver
Dis.* 2018; 1(2): 1010.

Copyright © 2018 Nalini Bansal. This is an open access article distributed under the Creative Commons Attribution License, which permits unrestricted use, distribution, and reproduction in any medium, provided the original work is properly cited.

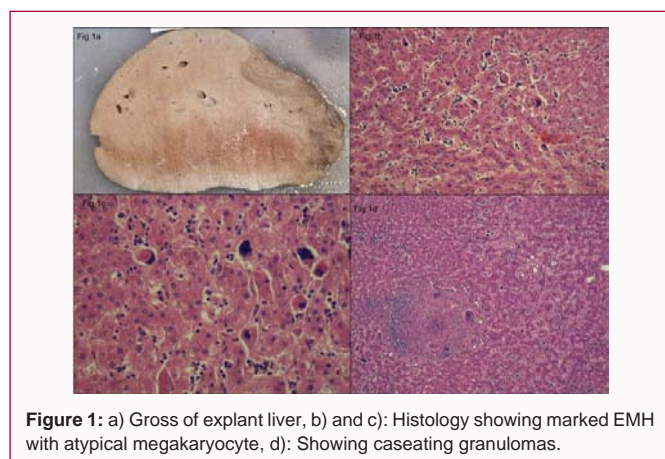


Figure 1: a) Gross of explant liver, b) and c): Histology showing marked EMH with atypical megakaryocyte, d): Showing caseating granulomas.

that liver is enlarged in size, with irregular margins. No Intrahepatic Biliary Radical Dilatation (IHBRD). Portal vein is of normal caliber 12.9 mm and shows hepatopedal flow. No obvious collaterals. No thrombus was noted.

She underwent combined liver and kidney transplant. Living Donor Liver Transplant (Right lobe liver with Modified Neo MHV graft) was done.

Section examined from her explant liver (Figure 1a) different lobes showed presence of multiple caseating and non caseating granulomas (Figure 1d) composed of large multinucleate giant cells, lymphocytes and polymorphs. There are areas of marked sinusoidal dilatation with multiple areas of extra medullary haematopoiesis (Figure 1b and 1c). The areas of extra medullary haematopoiesis show presence of numerous megakaryocytes including some atypical forms with staghorn nuclei, multilobulated large nuclei. There is increased periportal and perisinusoidal fibrosis with formation of porto-central and porto-portal bridges. AFB and PAS stains were performed on 4 sections with granulomas are negative.

In view of marked extra medullary haematopoiesis with atypical megakaryocytes a possibility of myelofibrosis was suggested and bone marrow biopsy was advised.

Her peripheral blood smear done subsequently showed features of myeloid metaplasia with presence of basophils, immature nucleated RBC's and myeloid cells. There were giant platelets with megakaryocytosis (Figure 2).

Bone marrow trephine biopsy performed showed hypercellular marrow with panmyelosis, thickening of bony trabeculae, normoblastic erythroid hyperplasia, myeloid hyperplasia, megakaryocytic proliferation and atypia and increased bone marrow fibrosis WHO Grade: 3+ (on 0-3+ scale). Morphologically suggestive of Primary Myelofibrosis.

Subsequently a hemato-oncologist opinion was sought for myelofibrosis and she was started on hydroxyurea up to 500 mg/day. Her platelet level came down from 12 to 4 lakhs in 2 weeks' time. She is still on follow up.

Discussion

Cryptogenic CLD are chronic liver disease in which its underlying aetiology remains unknown even after extensive clinical, serological, and pathological evaluations have been performed [1].

The prevalence rate of cryptogenic cirrhosis ranged from 5% to

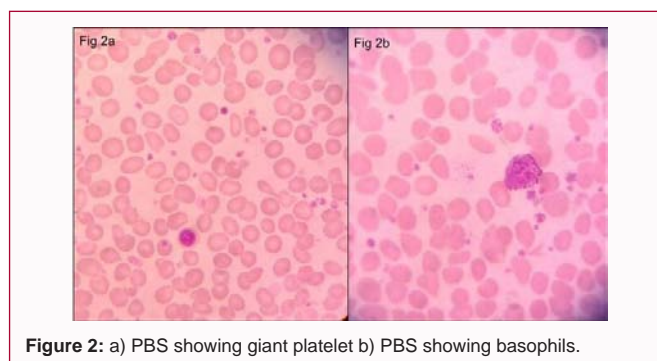


Figure 2: a) PBS showing giant platelet b) PBS showing basophils.

30% in older studies but has now decreased to about 5% with advances in the field. Many of these cases are now attributed to NASH/viral hepatitis with the advent of new markers. However, myelofibrosis presenting as cryptogenic chronic liver disease is extremely rare [2].

Occurrence of portal hypertension has been described in myelofibrosis. The pathophysiology for development of portal hypertension remains controversial. Few authors have postulated that extensive extramedullary hematopoiesis can lead to the development of sinusoidal and pericellular fibrosis which can increase resistance to inflow of blood through portal vein. There by causing portal hypertension. Other theory states that increase portal flow secondary to splenomegaly leads to portal hypertension [3].

Myelofibrosis usually presents with anemia, hepatomegaly and splenomegaly due to extramedullary hematopoiesis. Features secondary to portal hypertension as splenomegaly, ascites, varices can develop [4].

LFT profile usually show elevated Alkaline Phosphatase at the time of presentation, few have had elevated aspartate aminotransferase levels, but occurrence of jaundice is uncommon. Albumin levels mostly remain normal. Elevated ALP has also been shown to be prognostically relevant when it exceeds 2.5 \times the upper normal limit [5].

Many patients also had portal vein thrombosis at time of portal hypertension diagnosis, indicated by either Abdominal Doppler Ultrasound (US) or CT or MRI.

Liver Histology-Show varying degrees of extramedullary hematopoiesis, and infiltration of liver sinusoids with hematopoietic cells (myeloid metaplasia). The degree of fibrosis is variable ranges from perisinusoidal fibrosis to bridging [6].

Prognosis-Portal hypertension usually occurs after 5 years during the natural history of myelofibrosis. Median survival for patients with myelofibrosis is 4 years. Thus most patients will die before they become symptomatic of portal hypertension [3,7,8]. Hence is a rare phenomenon to see presenting with liver disease as was seen in our case.

In conclusion, we report the first case of myelofibrosis being diagnosed through an explant liver way. As the patient has been undergoing dialysis for chronic kidney disease the low haemoglobin was attributed to same. Presence of irregular liver margins, portal hypertension and splenomegaly on ultrasound favoured a cirrhotic liver of a cryptogenic cause. Liver biopsy could not be attempted due to risk of bleeding. This case is reported to highlight the etiological consideration of myelofibrosis in patient presenting with portal hypertension with raised Alkaline Phosphatase and no Jaundice.

References

1. Irizarry MA, Torres EA. Cryptogenic cirrhosis: Current knowledge and future directions. *CLD. A multimedia review journal.* 2016;7(4):69-72.
2. Charlton MR, Kondo M, Robert SK, Steers JL, Krom RA, Wiesner RH. Liver transplantation for cryptogenic cirrhosis. *Liver Transpl Surg.* 1997;3(4):359-64.
3. Abu-Hilal M, Tawaker J. Portal hypertension secondary to myelofibrosis with myeloid metaplasia: A study of 13 cases. *World J Gastroenterol.* 2009;15(25):3128-3133.
4. Tefferi A. Primary myelofibrosis: 2017 update on diagnosis, risk-stratification, and management. *Am J Hematol.* 2016;91(12):1262-71.
5. Barraco D, Mudireddy M, Shah S, CA Hanson, RP Ketterling, N Gangat, et al. Liver function test abnormalities and their clinical relevance in primary myelofibrosis. *Blood Cancer Journal.* 2017;7(4):e557.
6. Pereira A, Bruguera M, Cervantes F, Rozman C. Liver involvement at diagnosis of primary myelofibrosis: A clinicopathological study of twenty-two cases. *Eur J Haematol.* 1988;40(4):355-61.
7. Shaldon S, Sherlock S. Portal hypertension in the myeloproliferative syndrome and the reticuloses. *Am J Med.* 1962;32:758-64.
8. Ligumski M, Polliack A, Benbassat J. Nature and incidence of liver involvement in agnogenic myeloid metaplasia. *Scand J Haematol.* 1978;21(2):81-93.