



Multiple Schwannomas of the Posterior Tibial Nerve: Report of a Rare Case of Schwannomatosis

Pérez-Sánchez I*, Ausina-Gómez S, Izquierdo-Plazasa L and Cerrolaza-Uristoa N

Department of Orthopedic Surgery, Musculoskeletal Tumor Unit, University Hospital of Saint John of Alicante, Spain

Abstract

Schwannoma is the most common peripheral nerve sheath tumor. However, its localization in the foot is rare, affecting primarily the posterior tibial nerve. Although it usually occurs as a solitary idiopathic lesion, detection of multiple schwannomas has been described and requires a diagnostic study to rule out neurofibromatosis, given the association between these two entities. We describe the case of a 44-year-old man with multiple schwannomas located along the posterior tibial nerve with no other associated manifestations, presenting as a painful mass, located at the retromalleolar level and with associated hypoesthesia and dysesthesia. Surgical excision was performed, resecting a total of 18 lesions and preserving the complete integrity of the nerve. Histopathological study of the tumors confirmed the diagnosis of schwannoma. Eight months after the operation, the patient was asymptomatic and had no associated major sequela.

Although it is not a very common lesion, schwannoma should always be considered in the differential diagnosis of a soft-tissue mass affecting extremities. Surgical enucleation and decompression of the affected nerve are the recommended treatments in this type of tumor, particularly when neurogenic pain is present. This excision must be precise, as preservation of the adjacent nerve fascicles is key to avoid further neurological complications.

Keywords: Schwannoma; Posterior tibial nerve; Peripheral nerve sheath tumor; Neurofibromatosis; Schwannomatosis; Soft-tissue tumors

OPEN ACCESS

*Correspondence:

Iván Pérez Sánchez, Department of Orthopedic Surgery, Musculoskeletal Tumor Unit, University Hospital of Saint John of Alicante, Alicante, Spain,
E-mail: ivanperezsanchez12@gmail.com

Received Date: 13 Feb 2023

Accepted Date: 10 Mar 2023

Published Date: 17 Mar 2023

Citation:

Pérez-Sánchez I, Ausina-Gómez S, Izquierdo-Plazasa L, Cerrolaza-Uristoa N. Multiple Schwannomas of the Posterior Tibial Nerve: Report of a Rare Case of Schwannomatosis. *Ann Surg Case Rep.* 2023; 6(1): 1067.

Copyright © 2023 Pérez-Sánchez I. This is an open access article distributed under the Creative Commons Attribution License, which permits unrestricted use, distribution, and reproduction in any medium, provided the original work is properly cited.

Introduction

Schwannoma, also called neurilemoma, is a benign tumor derived from the myelin-producing Schwann cells of peripheral nerves. It is the most common peripheral nerve sheath tumor, comprising 5% of all soft tissue tumors. However, this tumor accounts for only 2% to 3% of all lesions involving the foot and ankle, affecting primarily the posterior tibial nerve [1-4].

Schwannomas occur as solitary idiopathic lesions in 90% of cases. Detection of multiple schwannomas is an infrequent condition but requires a diagnostic work-up to rule out Neurofibromatosis (NF), given the association between these two entities [4-6]. Schwannomatosis has been recognized as a third major form of NF (after NF type 1 and type 2). It is characterized by the presence of multiple non-intradermal schwannomas in the absence of associated vestibular tumors. It is a rare condition, accounting for 2% of all surgically resected schwannomas [3-6].

Despite their benign nature, surgical excision and referral of the specimen for pathological examination is the management of choice for this type of lesion, in order to obtain an immunohistochemical diagnosis and achieve an improvement in the symptoms derived from nerve compression [2,4].

This article describes a rare case of multiple schwannomas involving the posterior tibial nerve in a middle-age man without other manifestations of neurofibromatosis.

Case Presentation

A 44-year-old man was referred to our Musculoskeletal Tumor Unit with a 4-month history of pain in the right foot associated with a soft tissue tumor in the medial retromalleolar region. He had no history trauma.

Physical examination demonstrated a poorly delimited mobile soft-tissue mass in the right ankle, immediately posterior to the medial malleolus. The patient reported hypoesthesia of the posterior aspect of the ankle and Tinel's sign was positive along the posterior tibial nerve. No trophic or

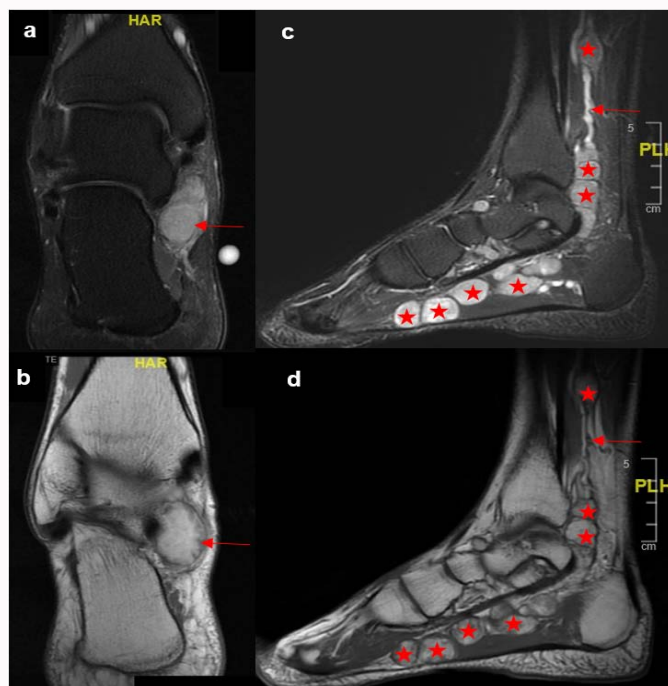


Figure 1: Multiple schwannomas. a-b) Coronal MRI images; c-d) Sagittal MRI images.

(a) STIR image shows homogeneous high-intensity lesions (arrow) located inferomedial to medial malleolus. (b) T1-weighted image shows the lesion (arrow) as nodular and low-intensity. (c) STIR image shows numerous well-defined high-intensity masses (stars) dependent on the posterior tibial nerve (arrow). (d) T2-weighted image shows that these masses (stars) extended along the path of this nerve (arrow), from the distal third of the posteromedial aspect of the tibia to the base of the first metatarsal.

skin coloring changes were noted and foot and ankle function was preserved.

Plain radiographs of the right ankle did not show any bony abnormality. Magnetic resonance imaging showed multiple well-defined oval nodular lesions along the course of the posterior tibial nerve. These masses extended from the base of the first metatarsal to the distal third of the posteromedial aspect of the leg. All of them showed low-signal intensity on T1-weighted images and high-signal intensity in fat uptake and contrast uptake (Figure 1).

After reassessment of the case by our Musculoskeletal Tumor Committee, a suspected diagnosis of Schwannomatosis of the right posterior tibial nerve was established and marginal excision of all the lesions with no prior biopsy was considered. The patient was referred prior to the surgery to the neurology department to evaluate a case of neurofibromatosis, which was ruled out as he had no other manifestations apart from the described lesions.

Surgical Technique

The surgery was performed in supine position under spinal anesthesia. A curved skin incision was made on the medial retromalleolar aspect of the right ankle, over the posterior tibial nerve. The flexor retinaculum was incised to identify the posterior tibial neurovascular bundle, which was referenced with Vessel-Loop to protect it. The posterior tibial nerve was then exposed from immediately proximal to the flexor retinaculum to the base of the first metatarsal. Multiple nodular, lobulated, soft, encapsulated lesions were identified along its entire length. They were located on the periphery of the nerve without including it (Figure 2a).

By blunt dissection, 18 masses were enucleated from the nerve sheath (Figure 2b). After the excision, the nerve was intact

although thinned out (Figure 2c, 2d). All the lesions were referred for histopathological examination, which confirmed the diagnosis of schwannomatosis (Figure 3).

The patient was discharged from the hospital the day after surgery and was allowed to walk with partial weightbearing for 2 to 3 weeks. Postoperatively, the patient showed progressive improvement in pain and sensibility impairment. At the last follow-up at 8 months, he was asymptomatic and had no related sequela, except for hypoesthesia on the medial side of the plantar aspect of the right foot; the pain completely disappeared and he fully recovered to normal walking. There was no evidence of recurrence on follow-up MRI at that time.

Discussion

Schwannoma is a benign soft-tissue tumor composed by Schwann cells. It accounts for 5% of all soft-tissue tumors and degenerates into neurofibrosarcoma in less than 1% of cases. Although it is not a very common lesion, it should always be considered in the differential diagnosis of a soft-tissue mass affecting extremities, especially when associated with neurological symptoms and a positive Tinel sign [1,3,5,7].

Most of detected schwannomas are usually located in the head and neck, affecting brachial plexus and spinal nerves. They rarely appear in extremities, representing only 2% to 3% of all tumors detected in the foot. When located peripherally, they mainly affect sciatic, ulnar and posterior tibial nerves (as in our case) [1-4,8]. Carvajal et al. [9] analyzed a series of 137 peripheral nerve sheath tumors surgically treated at their hospital. Only 14 cases (10.2%) were located in the foot and ankle, being schwannoma the most frequent histological subtype.

The presence of multiple schwannomas is an uncommon

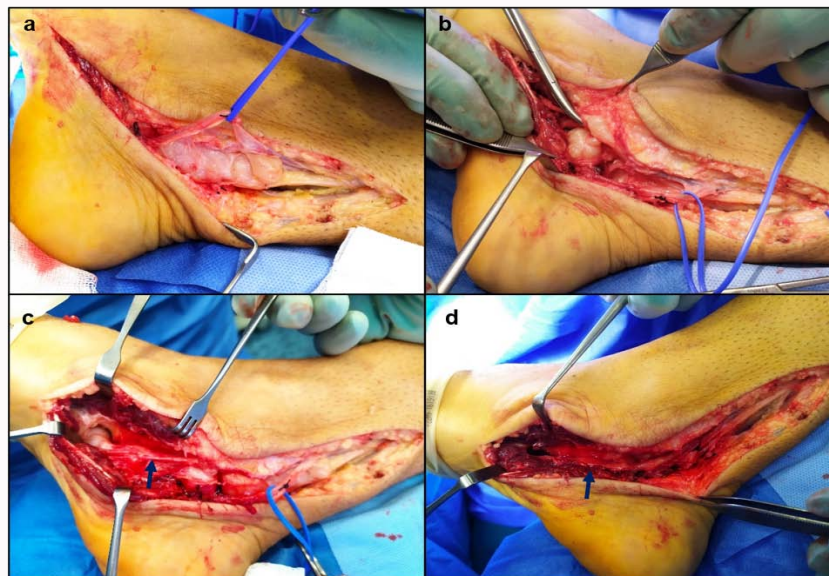


Figure 2: Intraoperative imaging of tumor excision. (a) Multiple nodular, lobulated, soft, encapsulated lesions were identified. The posterior tibial artery and vein were referenced with Vessel-Loop to protect them. (b) Meticulous dissection to isolate and release each mass from the nerve sheath while respecting the integrity of the posterior tibial nerve. (c, d) Posterior tibial nerve was intact but thinned (arrow) in the areas where the tumors were located.

condition that suggests a genetic tumor predisposition disorder and justifies a diagnostic work-up aimed at detecting possible associated Neurofibromatosis (NF). NF are a diverse group of genetic conditions that share a predisposition to the development of sheath nerve tumors. Schwannomatosis has been recognized as a third major form of NF (after NF type 1 and type 2). Definitive diagnosis of schwannomatosis is made after confirming histologically the presence of two or more schwannomas and ruling out the existence of other symptoms of NF type 1 (café au lait spots, ephelides, Lisch nodules, optic glioma, affected relatives, etc.) or NF type 2 (presence of vestibular tumors in individuals over 18 years of age). In our case, the patient was referred before the surgery to the neurology department, where NF was ruled out as there were no other findings apart from the lesions located in the posterior tibial nerve.

It is a rare disorder, with an estimated incidence ranging from 1/40,000 to 1/1.7 million people. These patients account for 2.4% to 5% of all cases in which schwannoma excision is performed. Furthermore, one third of patients with multiple schwannomas have tumors limited to a single limb or spinal segment, as in the case of our patient [3,4,6,10,11]. Regarding its etiopathogenesis, several genetic disorders have been identified in this disease. These include germline mutations in SMARCB1 suppressor gene, as well as mutations leading to a loss of function of LZTR1 gene, both located on chromosome 22 [11,12].

Despite their low malignant potential, surgical excision and referral of the specimen for pathological examination is the management of choice for these lesions. This excision must be very precise so as to achieve enucleation of these lesions without damaging the adjacent nerve. If malignancy is suspected, a biopsy prior to excision would be indicated [1,2,9].

Several articles describe the presence of isolated schwannomas in the posterior tibial nerve [1,4,7,8,13-15]. However, there are few publications showing multiple schwannomatosis located in this nerve and, in no case, with a number of lesions as high as that seen in our patient. Only von Deimling et al. [16] described a similar

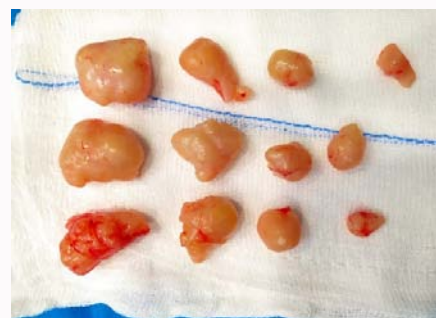

Figure 3: Macroscopic view of the lesions. Round/ovoid tumor pieces with a brownish-white nodular surface with a maximum diameter of 0.5 cm to 2.5 cm. On sectioning, the masses were solid and encapsulated and consisted of yellowish tissue of uniform appearance.

case to ours, reporting 18 peripheral schwannomas in a 46-year-old man. However, in that case these lesions were not dependent on the posterior tibial nerve but on the medial plantar nerve.

Conclusion

We present a case of schwannomatosis located along the posterior tibial nerve in a middle-age man who had no other stigmata characteristic of neurofibromatosis. Before surgical excision, an appropriate evaluation is essential, as the presence of multiple schwannomas justifies a diagnostic work-up aimed at detecting possible associated neurofibromatosis.

Surgical enucleation and decompression of the affected nerve are the recommended treatments in this type of tumor, particularly when neurogenic pain is present. This excision must be precise, as preservation of the adjacent nerve fascicles is key to avoid further neurological complications.

References

- Judd T, Jones T, Thornberry L. Schwannoma of the posterior tibial nerve. *J Am Podiatr Med Assoc.* 2014;104(5):539-43.

2. Nawabi DH, Sinisi M. Schwannoma of the posterior tibial nerve: The problem of delay in diagnosis. *J Bone Joint Surg Br.* 2007;89(6):814-6.
3. Bartolomé-García S, de la Cuadra-Virgili P, Jiménez-Cristóbal J. Schwannomatosis múltiple bilateral: A propósito de un caso. *Rev Esp Cir Ortop Traumatol.* 2011;55(3):220-3.
4. Schweitzer Jr KM, Adams Jr SB, Nunley 2nd JA. Multiple schwannomas of the posterior tibial nerve: A case series. *Foot Ankle Int.* 2013;34(4):607-11.
5. Galbiatti JA, Milhomens GRDS, Bertozzo LG, Escames L, Milhomens Neto PA, Galbiatti MGP. Retrospective analysis of 20 patients affected by schwannomas in the upper and lower limbs. *Rev Bras Ortop (Sao Paulo).* 2020;55(5):629-36.
6. Li XN, Cui JL, Christopasak SP, Kumar A, Peng ZG. Multiple plexiform schwannomas in the plantar aspect of the foot: Case report and literature review. *BMC Musculoskelet Disord.* 2014;15:342.
7. Joyce M, Laing AJ, Mullet H, Mofidi A, Tansey D, Connolly CE, et al. Multiple schwannomas of the posterior tibial nerve. *Foot Ankle Surg.* 2002;8:101-3.
8. Miranpuri S, Snook E, Vang D, Yong RM, Chagares WE. Neurilemoma of the posterior tibial nerve and tarsal tunnel syndrome. *J Am Podiatr Med Assoc.* 2007;97(2):148-50.
9. Carvajal JA, Cuartas E, Qadir R, Levi AD, Temple HT. Peripheral nerve sheath tumors of the foot and ankle. *Foot Ankle Int.* 2011;32(2):163-7.
10. MacCollin M, Chiocca EA, Evas DG, Friedman JM, Horvitz R, Jaramillo D, et al. Diagnostic criteria for schwannomatosis. *Neurology.* 2005;64:1838-45.
11. Tamura R. Current understanding of neurofibromatosis type 1, 2, and schwannomatosis. *Int J Mol Sci.* 2021;22(11):5850.
12. Herrero-San Martín A, Alcalá-Galiano A. Schwannoma of the posterior tibial nerve in a patient with schwannomatosis and a novel mutation of the LZTR1 gene. *Neurologia (Engl Ed).* 2020;35(9):657-9.
13. Fodor L, Samuila S, Bodog F. A rare case of schwannomatosis of the extremities. *J Int Med Res.* 2020;48(9):300060520952278.
14. Merrit G, Ramil M, Oxios A, Rushing C. Schwannoma of the plantar medial aspect of the foot: A case report. *Foot (Edinb).* 2019;39:85-7.
15. Watanabe K, Fukuzawa T, Mitsui K. Tarsal tunnel syndrome caused by a schwannoma of the posterior tibial nerve. *Acta Med Okayama.* 2018;72(1):77-80.
16. von Deimling U, Munzenberg KJ, Fischer HP. Multiple benign schwannomas of the foot. *Arch Orthop Trauma Surg.* 1996;115(3-4):240-2.