Journal of Heart and Stroke

Review Article
Published: 07 Dec, 2016

Mitral Valve Repair for Barlow's Disease: A Review of Repair Strategy Based on Long-Term Results

Akimasa Morisaki, Tadashi Isomura, Yasuhisa Fukada, Takuya Miyazaki, Minoru Yoshida and Masahiro Endo*

Department of Cardiovascular Surgery, Osaki Hospital Tokyo Heart Center, Japan

Abstract

Barlow's disease (BD) has a distinctive macroscopic appearance, which is characterized as an advanced stage of excess myxomatous degenerative leaflets, including bileaflet prolapse, billowing, chordal elongation, and considerable annular dilation with or without calcification. This is in contrast to fibroelastic deficiency, which mainly includes limited prolapsing segments. Therefore, BD requires a more difficult surgical repair strategy, including anterior and posterior leaflet repair, compared with fibroelastic deficiency. The present review evaluates which mitral valve repair for BD has better long-term results. Recent studies have reported that mitral valve repair with resection-and-suture, neo chordal repair (or the loop technique), and the Alfieri stitch provide comparable long-term results. However, a simple repair technique is not favorable. This is because studies that obtained excellent long-term results used combined repair technique sowing to the fact that BD consists of complex lesions. Moreover, redundant leaflets should be removed and elongated chorda should not be used because lesions may develop recurrent regurgitation. In mitral annuloplasty, recent studies have reported that non-use of a ring was a risk factor of recurrent regurgitation in the long term and a small-sized ring was associated with anterior systolic motion. Therefore, a large-sized ring is recommended for preventing systolic anterior motion and recurrent regurgitation. Comprehensive repair procedures that consist of resection of redundant leaflets with neo chordal repair, or the Alfieri stitch with leaflet resection or cleft plasty, and using a large annuloplasty ring for BD, may be ideal. These procedures can obtain robust long-term results similar to repair for fibroelastic deficiency.

OPEN ACCESS

Correspondence:
Akimasa Morisaki, Department of Cardiovascular Surgery, Osaki Hospital Tokyo Heart Center, 5-4-12Kitashinagawa, Shinagawa-ku, Tokyo 141-0001, Japan, Tel: +81-3-5789-8100;
E-mail: m3_514@yahoo.co.jp

Received Date: *15 Nov 2016*
Accepted Date*: 05 Dec 2016*
Published Date*: 07 Dec 2016*

Citation:
Morisaki A, Isomura T, Fukada Y, Miyazaki T, Yoshida M, Endo M. Mitral Valve Repair for Barlow's Disease: A Review of Repair Strategy Based on Long-Term Results. J Heart Stroke. 2016; 1(2): 1010.

Introduction

Mitral valve (MV) disease consists of various pathogenic mechanisms that affect the strategy of MV repair. Primary MV regurgitation is mainly caused by degenerative disease with or without calcified generative disease, and is classified by Carpentier's surgical classification type I or II [1]. Mitral degenerative disease consists of two or four principal types of pathogenic mechanisms as follows. Carpentier classified two types consisting of fibroelastic deficiency (FED) and Barlow's disease (BD). Anyanwu and Adams classified four types consisting of FED, advanced FED, forme fruste and BD [1-3].

BD has a distinctive macroscopic appearance, which is characterized as an advanced stage of excess myxomatous degenerative leaflets, including bileaflet prolapse, billowing, chordal elongation, and annular dilation with or without calcification. This is in contrast to FED, including limited prolapsing segments. These segments are mainly caused by chordal rupture in normal or thin leaflets with or without regional thickening or expansion and slight annular dilation, except for forme fruste [1-3] (Figure 1). These macroscopic characteristics in BD have been shown by pathological hallmarks consisting of myxoid infiltration, which destroys the three-layer leaflet architecture, and alterations in collagen [4]. FED results from connective tissue deficiency, resulting in thinning of leaflets with a preserved, three-layer architecture of the leaflet tissues [4]. Regional thickening and expansion of leaflets may result from a secondary pathological change in prolapsing segments with myxoid deposition [5].These findings of BD reflect different physical findings as mid systolic click and late systolic murmur in auscultation, with a relatively younger age at onset than common MV regurgitation in older patients [3].

According to the characteristics mentioned above, BD requires a more difficult surgical repair strategy compared with MV regurgitation caused by FED. This is because of specific appearances, including bileaflet prolapse with billowing leaflets and a considerably dilated mitral annulus in BD.

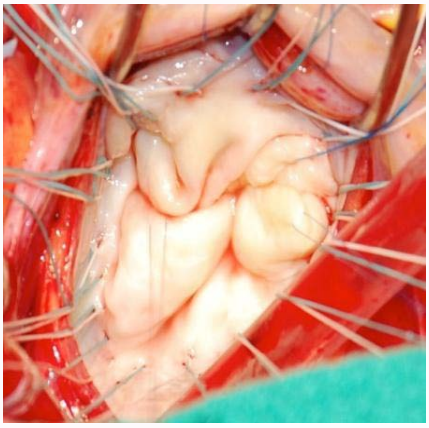

Figure 1: These macroscopic characteristics in BD.

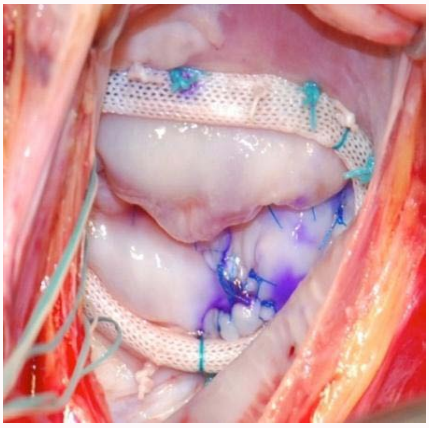

Figure 2: Composite MV repair for BD.

A previous study reported that MV repair for BD had worse long-term outcomes compared with FED [6], which indicated the difficulty of MV repair for BD. However, recently, a successful repair rate and good long-term results in MV repair for BD have been reported [7]. The present study reviews the long-term outcomes of MV repair for BD in recent studies.

Mitral Valve Repair for Barlow's Disease

Transthoracic or transesophageal echocardiography (TEE) provides important information that affects operative procedures. TEE reveals more detail of MV complexity compared with transthoracic echocardiography. Three-dimensional TEE is more useful and beneficial for obtaining accurate localization of MV regurgitation in complex lesions compared with two-dimensional TEE [8,9]. Therefore, before MV repair, evaluation of MV regurgitation by two- or three-dimensional TEE is needed to maintain a high quality of MV repair for preventing residual MV regurgitation and obtaining favorable long-term results.

The performance goal of MV repair is durable and robust long-term outcomes over the results of MV replacement. Since the superiority of early and long-term outcomes, including mortality rate, after MV repair compared with MV replacement has been reported [10-12], various data of MV repair has dramatically increased. Many studies have reported favorable results of MV repair that consisted of a high reparability rate (>95%) of the MV for MV diseases with a low mortality rate [10,13-15]. This has led to an era in which almost all patients have successful results after MV repair. Moreover, recent reports have shown greater than 90% freedom from reoperation for longer 15 years after MV repair for degenerative disease [16-18].

However, MV repair is still not able to provide a complete lack of recurrence of MV regurgitation. Flameng and colleagues reported that freedom from reoperation for BD was significantly worse (86.1% at 10 years) compared with that for FED (96.6% at 10 years) [6]. They also showed that freedom from failing repair (MV regurgitation > 2) was significantly associated with BD with 64.9%±5.6% freedom from MV regurgitation >2 at 10 years in the entire group [6]. Moreover, David and colleagues reported 701 cases with posterior, anterior, and bileaflet prolapse, and compared freedom from reoperation and moderate or severe MV regurgitation at 12 years [13]. They found significantly lower freedom from reoperation of anterior prolapse (88%±4%) compared with posterior (96%±2%) and bileaflet prolapse (94%±2%). They also found significantly lower freedom from moderate or severe MV regurgitation of anterior (65±8%) and bileaflet (67±6%) prolapse than from moderate or severe MV regurgitation of posterior prolapse (80±4%). This study suggested that MV repair for anterior and bileaflet prolapse required a certain amount of experience because most repair failure of anterior leaflet and bileaflet prolapse occurred in the first decade of experience. Therefore, BD requires more advanced surgical techniques and experience compared with FED, which mainly consists of simple posterior leaflet repair. This is because BD has multi-segmental myxomatous degenerative leaflets, including anterior leaflet or bileaflet prolapse. Therefore, MV repair for BD should be performed by mitral surgeons in centers with special expertise [19].

Recently Borger and Mohr et al. reported the excellent long-term results of MV repair for BD with 93.8%±2.6% freedom from reoperation and 88.4%±3.9% freedom from greater than 2+ MV regurgitation at 10 years [7]. O. c and colleagues also showed that MV repair with the Alfieri stitch for BD provided good mid-term results with 94.0%±4.4% freedom from reoperation and 90.6%±5.1% freedom from greater than 2+ MV regurgitation at 5 years [20]. These data suggest that surgeons can treat MV regurgitation caused by BD with robust mid- and long-term outcomes.

Mitral Valve Leaflet and Subvalvular Repair

The concept of MV repair is to maintain the coaptation surface (height and width) and align the height of bileaflets. Many types of MV repair, such as resection-and-suture, including triangular, quadrangular, sand-clock, and the sliding techniques, neo chordal repair, the loop technique, transposition of chorda, edge-to-edge suturing (Alfieri stitch), and commissuroplasty suturing, have been established. In 1983, Carpentier and colleagues introduced the French correction that consists of a multi component philosophical and surgical approach to MV disease, including the resection-and-suture technique [21]. Resection and suture of posterior leaflets for MV regurgitation is still the gold standard technique because it is a simple and reliable procedure. However, recently, there has been a new shift in paradigm. Perier and colleagues postulated the concept of "respect rather than resect" of the posterior leaflet for preserving a good coaptation surface and satisfactory MV function instead of resection, which is associated with distortion of the MV annulus [22]. The results of respect rather than resect showed satisfactory long-term results, with a greater than 93% freedom from reoperation rate. Furthermore, Lawrie and colleagues showed that anterior leaflet repair with polytetrafluoroethylene (PTFE) reconstruction,

the so-called American correction, can provide reproducibility with the same results as posterior leaflet repair [23]. Additionally, Opell and Mohr invented the loop technique with PTFE for anterior and posterior mitral leaflets, which facilitated neochordal repair in American correction [24]. Edge-to-edge repair, the so-called Alfieri stitch, for MV regurgitation has been proposed, and is a simple and reproducible technique [25]. Recently, long-term outcomes of the three techniques of resection-and-suture, the neochordal repair, and the Alfieri stitch, for MV regurgitation were reported. There were excellent equivalent results between resection and the neochordal repair (>90% freedom from reoperation 15 years after the operation) [26]. However, the results of MV repair with the resection technique were derived from a larger number of patients and a longer period of time compared with those of the neochordal repair [26]. In the Alfieri stitch, greater than 90% freedom from reoperation in 17 years has been reported [18]. Therefore, surgeons may decide on either technique based on their own experience and perpetuated knowledge [26].

In BD, MV repair techniques that produce robust, good, long-term results have not been established yet. Recently, Borger and Mohr et al. [7]. reported good long-term results in MV repair with composite procedures consisting of the loop technique, resection-and-suture, and the Alfieri stitch, especially under recommended aggressive resection for redundant leaflets [7]. Castillo et al. [15]. Also showed favorable results of MV repair combined with neo chordal repair (or loop), chordal transfer, and the posterior leaflet flip technique [15]. Rocha and colleagues reported the outcomes of MV repair with the simple loop technique or simple Alfieri stitch for BD [27]. Although the results of both procedures were comparable, the loop technique had relatively more early reoperations compared with the Alfieri stich. Therefore, the simple loop technique for BD may lead to a high failure rate of repair. Moreover, Maisano and Alfieri recommended that wide clefts or previously unrecognized leaflet prolapse in segments other than central leaflet prolapse should be corrected with cleft closure or leaflet resection, and not only undergo the Alfieri stitch [28]. Flameng and colleagues reported that performing chordal shortening and non-use of sliding plasty were more significantly associated with recurrence of MV regurgitation in BD compared with FED [6]. A previous report also showed that neo chordal repair was superior to chordal shortening in repair of the anterior leaflet [29]. These results suggest that the redundant leaflet should be removed and elongated chorda should not be used for preventing recurrent MV regurgitation. Additionally, chordal transfer may not be favorable, because in BD, there is the possibility of the disease spreading to other chordae. These results suggest that comprehensive repair procedures, such as resection of a redundant posterior leaflet with or without neo chordal repair, neo chordal repair of anterior leaflets with or without resection of redundant leaflets, and the Alfieri stitch with or without leaflet resection, may be ideal procedures owing to robust long-term results. We recommend combined MV repair that emphasizes resection of redundant leaflets because of the characteristics of excess redundant leaflets in BD in contrast to FED (Figure 2 shows composite MV repair for BD).

In MV techniques, prolapse and billowing width can determine the type of resection-and-suture and neo chordal repair technique. In the resection technique for posterior leaflets, quadrangular resection or the sliding technique is appropriate rather than triangular resection because BD has excess billowing leaflets. For anterior leaflets, only triangular resection of the rough zone is recommended because resection of the clear zone and wide resection may lead to distortion associated with loss of coaptation. By contrast, in neochordal repair, the loop technique may lead to a better contribution as below mentioned in wide prolapse segments than in isolated neo chordal repair. The loop technique has several advantages, such as easily determining the length of neo chorda with or without a loop in the loop technique, easily re-fixing the loop to adequate prolapsing segments, and shortening of the operation time by premade loops [30]. However, coexisting prolapse of commissural lesions is a weakness of the loop technique. Therefore, commissuroplasty suturing may also be needed to improve distortion and obtain good coaptation, ensuring complete repair.

The water saline test and TEE findings are important for determining the success of repair, which is associated with long-term outcomes after MV repair [31-33]. More than mild residual MV regurgitation after MV repair is associated with recurrent greater than moderate MV regurgitation and reoperation [32,33]. Therefore, no leakage by the water saline test and less than trivial MV regurgitation by TEE after MV repair may improve and provide good long-term results without reoperation.

Systolic anterior motion (SAM) consists of dynamic anterior mitral leaflet movement toward the interventricular septum during systole with left ventricular outflow tract obstruction. This condition is a considerable complication associated with residual MV regurgitation after MV repair. SAM is treated by medical therapy, including intravascular volume load, discontinued inotropic drugs, and administration of beta-blockers after weaning from an extracorporeal circuit. However, some patients still have SAM and require re-surgical interventions [34]. Risks of SAM after MV repair are excess posterior leaflet tissue, a short distance between the leaflet coaptation point and the interventricular septum, a thick basal interventricular septum, a long secondary chorda, inadequate resection of the posterior leaflet, and using a small-sized annuloplasty ring [34-36].Almost BD has excess redundant and billowing posterior leaflet that are strongly associated with SAM. Therefore, the redundant posterior leaflet should be resected to prevent SAM. However, some patients develop SAM after MV repair with resection-and-suture for BD [16]. The reasons for SAM in such patients may be inadequate resection of the posterior leaflet or using an undersized annuloplasty ring. Therefore, leaflet resection with sliding plasty of less than 15mm in height of the posterior leaflet accompanied by upsized annuloplasty ring insertion may reduce SAM [35]. In contrast, studies of the loop technique or neo chordal repair for degenerative disease have reported little SAM [14,37]. The neo chordae may effectively pull the posterior leaflet down to the papillary muscle, which is associated with preventing SAM. Kudo and colleagues reported that the loop technique is a simple method for preventing SAM [38]. Furthermore, in patients who have a high risk of SAM and severe conditions in which a second pump run was avoided, a simple Alfieri stitch fixing the free edge of the anterior leaflet may conveniently eliminate SAM with a shortening in operation time [27,28,39].

Mitral Valve Annuloplasty

BD has a considerably larger MV annulus that requires a large mitral annuloplasty ring than FED [40]. Previous studies have shown that non-use of a mitral annuloplasty ring is significantly associated with recurrence of MV regurgitation, and a mitral annuloplasty ring provides good coaptation [6,32]. Therefore, a mitral annuloplasty ring is required to prevent recurrent mitral regurgitation.

The type and size of an annuloplasty ring are important factors for determining favorable long-term results after MV repair. In a review of mitral valve annuloplasty for degenerative disease, a flexible annuloplasty ring may improve left ventricular systolic function, but does not translate into better clinical outcomes compared with a semi-rigid or rigid annuloplasty ring [41]. Recently, a propensity-matched cohort study reported that there were no significant differences in ejection fraction and end-systolic/end-diastolic dimension between semi-rigid and flexible annuloplasty rings [42]. In BD, a flexible ring and semi-rigid ring also provide comparable long-term results. However, a complete semi-rigid ring was used in a relatively large number of studies without disturbing MV function owing to prevention of annular dilatation and reshaping the mitral annulus [7,14,15,20,27,43]. Therefore, the type of annuloplasty ring may not affect long-term results. In annular sizing, the inter commissural distance and mitral anterior leaflet dimension are measured by mitral annular sizes. Using a small-sized ring increases the risk of causing SAM, whereas a large-sized ring helps minimize the risk of SAM [40]. Therefore, annuloplasty rings just over the size of the intercomissural distance or anterior leaflet dimension should be chosen with the bias of choosing larger size among the available sizes for preventing SAM.

Severe mitral annular calcification is a common finding in approximately 24% of patients with BD who undergo MV repair. This finding increases the difficulty of MV procedures and sometimes requires MV replacement [44]. Removal of extensive mitral annular calcification is associated with risks of posterior atrioventricular groove rupture and circumflex coronary artery injury. A surgical mortality rate of up to 9% has been reported for patients undergoing extensive decalcification procedures [45,46]. Recently, Morisaki and colleagues reported that MV repair without artificial ring implantation and decalcification could regulate MV regurgitation [47]. This report suggested that an extensively calcified annulus, a so-called natural artificial ring, will not dilate in the future. Additionally, MV repair without artificial ring implantation may be feasible in these patients because a calcified annulus may prevent dilatation. Moreover, without ring implantation, wide triangular- or quadrangular-shaped resection leads to shortening of the mitral leaflets without shrinking of the mitral annulus by extensive calcification. This calcification causes MV regurgitation because of a reduced coaptation zone. Therefore, in patients who have extensive mitral annular calcification, comprehensive MV repair without a wide resection technique may be required to maintain good coaptation of the MV and obtain good long-term results because of no MV annuloplasty.

Minimally Invasive Mitral Valve Repair

Recently, minimally invasive MV surgery has been increasingly performed along with development of devices and establishing safe techniques for minimally invasive cardiac surgery. Recent studies have indicated that minimally invasive MV surgery can provide equivalent results compared with conventional MV surgery with several associated clinical benefits [48,49]. These benefits included cosmetic acceptance, decreasing the hospital stay, and avoiding mediastinitis. However, minimally invasive MV surgery causes stress to surgeons because of a narrow and deep operative field that necessitates more difficult operative maneuvers and specific instruments. However, an endoscopic view and thoracotomy approach provide good exposure because the sideways view provides direct vision in front of the MV compared with the conventional approach. There is a certain learning curve to achieve stable outcomes and a steady operation time because of difficult operative maneuvers [50]. Therefore, the first step of minimally invasive MV surgery should be undergone in non-complex MV disease, such as FED.

Minimally invasive MV repair for BD is more challenging than repair for FED because repair for BD requires many operative maneuvers. MV repair of BD is usually performed via median sternotomy instead of left mini-thoracotomy. After experience of successfully performing minimally invasive MV repair for FED, cardiac surgeons may be able to undergo minimally invasive MV repair for BD as the next stage. Lapenna and colleagues reported that MV insufficiency due to BD can be effectively corrected by minimally invasive MV repair with the edge-to-edge technique via a small right anterolateral thoracotomy [51]. They reported a 100% success rate of less than mild residual MV regurgitation. Furthermore, Speziale and colleagues compared minimally invasive MV repair with conventional open repair for BD in 70 patients [52]. They found that the results of minimally invasive MV repair, which was mainly performed with neo chordal repair rather than quadrangular resection or edge-to-edge approximation, were equal to conventional repair (minimally invasive versus conventional, 98.5% versus 100% success rate; 98% versus 97% freedom from moderate or severe MV regurgitation). Additionally, Muneretto and colleagues reported that minimally invasive MV repair using neo chordal repair with resection provided good mid-term results [53]. They found 95.7% freedom from reoperation at 3 years and 100% freedom from more than moderate MV regurgitation after the operation. Da Rocha and colleagues also reported that 4 years freedom from reoperation was 92.8%±5.0% in the repair group using the Alfieri stitch compared with 90.9%±4.6% in the loop technique [27]. Recently, Borger and colleagues reported excellent long-term outcomes at 10 years, including 93.8%±2.6% freedom from reoperation and 88.4±3.9% freedom from greater than moderate MV regurgitation in minimally invasive MV repair [7]. They used composite techniques that consisted of the loop technique, resection-and-suture, the Alfieri stitch, and commissuroplasty. These results suggest that BD can be treated by minimally invasive MV repair using various techniques. In particular, composite MV repair with an easy, simple technique, such as the Alfieri stitch or loop technique, may be acceptable in initial minimally invasive MV repair for BD. This is because a narrow and deeper operative field restricts complicated maneuvers.

Conclusion

BD has characteristic macroscopic findings that consist of an advanced stage of excess myxomatous degenerative leaflets, including bileaflet prolapse, billowing, and chordal elongation. These features require more comprehensive operative techniques that are different from those for FED, which mainly includes limited prolapsing segments. There are mainly three MV repair techniques, including resection-and-suture, neo chordal repair (or the loop technique), and the Alfieri stitch. Each technique provides comparable and excellent long-term results with a low rate of freedom from reoperation and more than moderate recurrent regurgitation, similar to FED. However, using only a simple repair technique is not favorable. Previous studies that obtained excellent long-term results used combined MV repair techniques because BD consists of complex lesions. Additionally, redundant leaflets should be removed and elongated chorda should not be used because the lesions may develop recurrent MV regurgitation. In MV annuloplasty for BD with alarge annulus, a large-sized ring is recommended to prevent systolic anterior

motion and recurrent MV regurgitation in the long term after repair. Therefore, comprehensive repair procedures that consist of resection of redundant leaflets with neo chordal repair or the Alfieri stitch with leaflet resection or cleft plasty, and using a large annuloplasty ring for BD may be ideal. These procedures are recommended to obtain robust long-term results similar to repair for FED.

References

1. Carpentier A, Chauvaud S, Fabiani JN, Deloche A, Relland J, Lessana A, et al. Reconstructive surgery of mitral valve incompetence: ten-year appraisal. J Thorac Cardiovasc Surg. 1980; 79: 338-348.
2. Carpentier AF, Lessana A, Relland JY, Belli E, Mihaileanu S, Berrebi AJ, et al. The "physio-ring": an advanced concept in mitral valve annuloplasty. Ann Thorac Surg. 1995; 60: 1177-1185.
3. Anyanwu AC, Adams DH. Etiologic classification of degenerative mitral valve disease: Barlow's disease and fibroelastic deficiency. Semin Thorac Cardiovasc Surg. 2007; 19: 90-96.
4. Fornes P, Heudes D, Fuzellier JF, Tixier D, Bruneval P, Carpentier A. Correlation between clinical and histologic patterns of degenerative mitral valve insufficiency: a histomorphometric study of 130 excised segments. Cardiovasc Pathol. 1999; 8: 81-92.
5. Carpentier AF, Pellerin M, Fuzellier JF, Relland JY. Extensive calcification of the mitral valve anulus: pathology and surgical management. J Thorac Cardiovasc Surg. 1996; 111: 718-729.
6. Flameng W, Meuris B, Herijgers P, Herregods MC. Durability of mitral valve repair in Barlow disease versus fibroelastic deficiency. J Thorac Cardiovasc Surg. 2008; 135: 274-282.
7. Borger MA, Kaeding AF, Seeburger J, Melnitchouk S, Hoebartner M, Winkfein M, et al. Minimally invasive mitral valve repair in Barlow's disease: early and long-term results. J Thorac Cardiovasc Surg. 2014; 148: 1379-1385.
8. Muller S, Muller L, Laufer G, Alber H, Dichtl W, Frick M, et al. Comparison of three-dimensional imaging to transesophageal echocardiography for preoperative evaluation in mitral valve prolapse. Am J Cardiol. 2006; 98: 243-248.
9. Chikwe J, Adams DH, Su KN, Anyanwu AC, Lin HM, Goldstone AB, et al. Can three-dimensional echocardiography accurately predict complexity of mitral valve repair? Eur J Cardiothorac Surg. 2012; 41: 518-524.
10. Gillinov AM, Cosgrove DM, Blackstone EH, Diaz R, Arnold JH, Lytle BW, et al. Durability of mitral valve repair for degenerative disease. J Thorac Cardiovasc Surg. 1998; 116: 734-743.
11. Suri RM, Schaff HV, Dearani JA, Sundt TM, Daly RC, Mullany CJ, et al. Survival advantage and improved durability of mitral repair for leaflet prolapse subsets in the current era. Ann Thorac Surg. 2006; 82: 819-826.
12. Daneshmand MA, Milano CA, Rankin JS, Honeycutt EF, Swaminathan M, Shaw LK, et al. Mitral valve repair for degenerative disease: a 20-year experience. Ann Thorac Surg. 2009; 88: 1828-1837.
13. David TE, Ivanov J, Armstrong S, Christie D, Rakowski H. A comparison of outcomes of mitral valve repair for degenerative disease with posterior, anterior, and bileaflet prolapse. J Thorac Cardiovasc Surg. 2005; 130: 1242-1249.
14. Lawrie GM, Zoghbi W, Little S, Shah D, Ben-Zekry Z, Earle N, et al. One hundred percent reparability of degenerative mitral regurgitation: intermediate-term results of a dynamic engineered approach. Ann Thorac Surg. 2016; 101: 576-583.
15. Castillo JG, Anyanwu AC, El-Eshmawi A, Adams DH. All anterior and bileaflet mitral valve prolapses are repairable in the modern era of reconstructive surgery. Eur J Cardiothorac Surg. 2014; 45: 139-145.
16. Salvador L, Mirone S, Bianchini R, Regesta T, Patelli F, Minniti G, et al. A 20-year experience with mitral valve repair with artificial chordae in 608 patients. J Thorac Cardiovasc Surg. 2008; 135: 1280-1287.
17. David TE, Armstrong S, Ivanov J. Chordal replacement with polytetrafluoroethylene sutures for mitral valve repair: a 25-year experience. J Thorac Cardiovasc Surg. 2013; 145: 1563-1569.
18. De Bonis M, Lapenna E, Taramasso M, La Canna G, Buzzatti N, Pappalardo F, et al. Very long-term durability of the edge-to-edge repair for isolated anterior mitral leaflet prolapse: up to 21 years of clinical and echocardiographic results. J Thorac Cardiovasc Surg. 2014; 148: 2027-2032.
19. Adams DH, Rosenhek R, Falk V. Degenerative mitral valve regurgitation: best practice revolution. Eur Heart J. 2010; 31: 1958-1966.
20. Oc M, Doukas G, Alexiou C, Oc B, Hadjinikolaou L, Sosnowski AW, et al. Edge-to-edge repair with mitral annuloplasty for Barlow's disease. Ann Thorac Surg. 2005; 80: 1315-1318.
21. Carpentier A. Cardiac valve surgery--the "French correction". J Thorac Cardiovasc Surg. 1983; 86: 323-337.
22. Perier P, Hohenberger W, Lakew F, Batz G, Urbanski P, Zacher M, et al. Toward a new paradigm for the reconstruction of posterior leaflet prolapse: midterm results of the "respect rather than resect" approach. Ann Thorac Surg. 2008; 86: 718-724.
23. Lawrie GM, Earle EA, Earle NR. Feasibility and intermediate term outcome of repair of prolapsing anterior mitral leaflets with artificial chordal replacement in 152 patients. Ann Thorac Surg. 2006; 81: 849-856.
24. von Oppell UO, Mohr FW. Chordal replacement for both minimally invasive and conventional mitral valve surgery using premeasured Gore-Tex loops. Ann Thorac Surg. 2000; 70: 2166-2168.
25. Alfieri O, Maisano F. An effective technique to correct anterior mitral leaflet prolapse. J Card Surg. 1999; 14: 468-470.
26. Tourmousoglou C, Lalos S, Dougenis D. Mitral valve repair of isolated posterior leaflet prolapse: resect or respect? Interact Cardiovasc Thorac Surg. 2014; 19: 1027-1035.
27. da Rocha ESJG, Spampinato R, Misfeld M, Seeburger J, Pfanmuller B, Eifert S, et al. Barlow's mitral valve disease: acomparison of neochordal (loop) and edge-to-edge (Alfieri) Minimally invasive repair techniques. Ann Thorac Surg. 2015; 100: 2127-2133.
28. Maisano F, Schreuder JJ, Oppizzi M, Fiorani B, Fino C, Alfieri O. The double-orifice technique as a standardized approach to treat mitral regurgitation due to severe myxomatous disease: surgical technique. Eur J Cardiothorac Surg. 2000; 17: 201-205.
29. Phillips MR, Daly RC, Schaff HV, Dearani JA, Mullany CJ, Orszulak TA. Repair of anterior leaflet mitral valve prolapse: chordal replacement versus chordal shortening. Ann Thorac Surg. 2000; 69: 25-29.
30. Shibata T, Kato Y, Motoki M, Takahashi Y, Morisaki A, Nishimura S, et al. Mitral valve repair with loop technique via median sternotomy in 180 patients. Eur J Cardiothorac Surg. 2015; 47: 491-496.
31. Maisano F, Caldarola A, Blasio A, De Bonis M, La Canna G, Alfieri O. Midterm results of edge-to-edge mitral valve repair without annuloplasty. J Thorac Cardiovasc Surg. 2003; 126: 1987-1997.
32. Hata H, Fujita T, Shimahara Y, Sato S, Ishibashi-Ueda H, Kobayashi J. A 25-year study of chordal replacement with expanded polytetrafluoroethylene in mitral valve repair. Interact Cardiovasc Thorac Surg. 2015; 20: 463-468.
33. De Bonis M, Lapenna E, Maisano F, Barili F, La Canna G, Buzzatti N, et al. Long-term results (</=18 years) of the edge-to-edge mitral valve repair without annuloplasty in degenerative mitral regurgitation: implications for the percutaneous approach. Circulation. 2014; 130: S19-S24.
34. Alfieri O, Lapenna E. Systolic anterior motion after mitral valve repair: where do we stand in 2015? Eur J Cardio Thorac Surg. 2015; 48: 344-346.

35. Varghese R, Itagaki S, Anyanwu AC, Trigo P, Fischer G, Adams DH. Predicting systolic anterior motion after mitral valve reconstruction: using intraoperative transoesophageal echocardiography to identify those at greatest risk. Eur J Cardiothorac Surg. 2014; 45: 132-137.

36. Roshanali F, Naderan M, Shoar S, Vedadian A, Sandoughdaran S, Shoar N, et al. Length of second-order chordae as a predictor of systolic anterior motion of the mitral valve. Interact Cardiovasc Thorac Surg. 2016; 23: 280-285.

37. Seeburger J, Falk V, Borger MA, Passage J, Walther T, Doll N, et al. Chordae replacement versus resection for repair of isolated posterior mitral leaflet prolapse: à ègalité. Ann Thorac Surg. 2009; 87: 1715-1720.

38. Kudo M, Yozu R, Kokaji K, Kimura N. A simple method of prevention for systolic anterior motion in mitral valve repair by loop technique method. Ann Thorac Surg. 2009; 87: 324-325.

39. Myers PO, Khalpey Z, Maloney AM, Brinster DR, D'Ambra MN, Cohn LH. Edge-to-edge repair for prevention and treatment of mitral valve systolic anterior motion. J Thorac Cardiovasc Surg. 2013; 146: 836-840.

40. Adams DH, Anyanwu AC, Rahmanian PB, Abascal V, Salzberg SP, Filsoufi F. Large annuloplasty rings facilitate mitral valve repair in Barlow's disease. Ann Thorac Surg. 2006; 82: 2096-2100.

41. Chee T, Haston R, Togo A, Raja SG. Is a flexible mitral annuloplasty ring superior to a semi-rigid or rigid ring in terms of improvement in symptoms and survival? Interact Cardiovasc Thorac Surg. 2008; 7: 477-484.

42. Manabe S, Kasegawa H, Fukui T, Tabata M, Shinozaki T, Shimokawa T, et al. Do semi-rigid prosthetic rings affect left ventricular function after mitral valve repair? Circ J. 2013; 77: 2038-2042.

43. De Paulis R, Maselli D, Salica A, Leonetti S, Guerrieri Wolf L, Weltert L, et al. Mitral repair with the sole use of a semi-rigid band in a sub-population of patients with Barlow's disease: a 4-year follow-up with stress echocardiography. Interact Cardiovasc Thorac Surg. 2015; 21: 316-321.

44. Fusini L, Ghulam Ali S, Tamborini G, Muratori M, Gripari P, Maffessanti F, et al. Prevalence of calcification of the mitral valve annulus in patients undergoing surgical repair of mitral valve prolapse. Am J Cardiol. 2014; 113: 1867-1873.

45. Carpentier AF, Pellerin M, Fuzellier JF, Relland JY. Extensive calcification of the mitral valve anulus: pathology and surgical management. J Thorac Cardiovasc Surg. 1996; 111: 718-729.

46. Feindel CM, Tufail Z, David TE, Ivanov J, Armstrong S. Mitral valve surgery in patients with extensive calcification of the mitral annulus. J Thorac Cardiovasc Surg. 2003; 126: 777-782.

47. Morisaki A, Kato Y, Takahashi Y, Shibata T. Mitral valve repair without mitral annuloplasty with extensive mitral annular calcification. Interact Cardiovasc Thorac Surg. 2014; 19: 1080-1082.

48. Seeburger J, Borger MA, Falk V, Kuntze T, Czesla M, Walther T, et al. Minimal invasive mitral valve repair for mitral regurgitation: results of 1339 consecutive patients. Eur J Cardiothorac Surg. 2008; 34: 760-765.

49. Goldstone AB, Atluri P, Szeto WY, Trubelja A, Howard JL, MacArthur JW, et al. Minimally invasive approach provides at least equivalent results for surgical correction of mitral regurgitation: a propensity-matched comparison. J Thorac Cardiovasc Surg. 2013; 145: 748-756.

50. Holzhey DM, Seeburger J, Misfeld M, Borger MA, Mohr FW. Learning minimally invasive mitral valve surgery: a cumulative sum sequential probability analysis of 3895 operations from a single high-volume center. Circulation. 2013; 128: 483-491.

51. Lapenna E, Torracca L, De Bonis M, La Canna G, Crescenzi G, Alfieri O. Minimally invasive mitral valve repair in the context of Barlow's disease. Ann Thorac Surg. 2005; 79: 1496-1499.

52. Speziale G, Nasso G, Esposito G, Conte M, Greco E, Fattouch K, et al. Results of mitral valve repair for Barlow disease (bileaflet prolapse) via right minithoracotomy versus conventional median sternotomy: a randomized trial. J Thorac Cardiovasc Surg. 2011; 142: 77-83.

53. Muneretto C, Bisleri G, Bagozzi L, Repossini A, Berlinghieri N, Chiari E. Results of minimally invasive, video-assisted mitral valve repair in advanced Barlow's disease with bileaflet prolapse. Eur J Cardiothorac Surg. 2015; 47: 46-50.