



‘Meshed Enhanced Hammock’ or ‘Tent’: A New Patient Centred Pre-Pectoral One-Stage Immediate Breast Reconstruction Technique for Varying Ptosis

Gerald Gui* and Fiona J Tsang

Department of Academic Surgery, The Royal Marsden NHS Trust, UK

Abstract

Acellular Dermal Matrices (ADM) have revolutionized direct-to-implant breast reconstruction, particularly in the pre-pectoral approach, with reduced post-operative pain and early hospital discharge, lower analgesic requirements, limited muscle dysfunction and reduction in animation. We describe a ‘meshed enhanced hammock’ or ‘tent’ technique for recreating breasts with varying degrees of ptosis using a meshed biological ADM derived from fetal calf skin, with good aesthetic outcome, low complication risks and implant loss. This technique utilizes the tensile strength of a meshed ADM in a one-stage direct to fixed implant pre-pectoral breast reconstruction. The creation of ptosis to match the contralateral breast reduces the need for additional symmetrisation surgery and allows the formation of a more natural reconstructed breast.

Keywords: Breast cancer; Breast reconstruction; Acellular dermal matrix; Breast implant; Direct to implant

Introduction

When Acellular Dermal Matrices (ADM) were first introduced, the fundamental application was as an adjunct to sub-muscular implant placement, thus broadening the indications for direct-to-implant reconstruction with acceptable complication rates [1-7]. Whilst there is a finite learning curve, experienced surgeons achieve reliable results using both biologic ADMs and synthetic meshes [6,8-18].

In the pre-pectoral approach, avoidance of raising the pectoralis major reduces post-operative pain, lowers analgesic requirements, allows early discharge protocols, limits muscle dysfunction and reduces animation. Early results have shown acceptable levels of complication rates, low implant loss rates, and good aesthetic outcomes [19-22]. Braxon was the first ADM to be manufactured for pre-pectoral implant reconstruction [23] and is based on ‘wrap’ technique with entire implant coverage in the subcutaneous mastectomy pocket. This technique is most effective in reconstructing non-ptotic breasts.

SurgiMend® PRS (Integra Life Sciences, New Jersey, USA) introduced a new meshed ADM derived from foetal calf skin in September 2017. We describe our experience of using SurgiMend® PRS meshed to recreate breasts with varying degrees of ptosis, using concepts we believe have not been previously reported.

Case Presentation

Preparation of the mesh

The sterile packaging should only be opened once the mastectomy is complete and the implant pocket is ready. The ADM is rehydrated in normal saline at room temperature on a freshly prepared sterile trolley and is fully stretched by three sustained pulling actions; this takes less than one minute. The stretched biological mesh can be easily draped over a 500 to 550 cc fixed-volume implant; even with high projection. The authors trim the superior, lateral and medial edges over a sizer. The remaining inferior edge can either be trimmed to fit the inferior pole snugly as a ‘tent’ or kept long as an ‘extended hammock’. Care is taken to minimize manipulation of the mesh and implant to prevent contamination. The ADM mesh is orientated with the direction of stretch aligned along the cranio-caudal axis for optimum implant support.

OPEN ACCESS

*Correspondence:

Gerald PH Gui, Department of Academic Surgery, The Royal Marsden NHS Trust, 203 Fulham Road, London SW3 6JJ, UK,

E-mail: gerald.gui@rmh.nhs.uk

Received Date: 17 Apr 2019

Accepted Date: 13 May 2019

Published Date: 24 May 2019

Citation:

Gui G, Tsang FJ. ‘Meshed Enhanced Hammock’ or ‘Tent’: A New Patient Centred Pre-Pectoral One-Stage Immediate Breast Reconstruction Technique for Varying Ptosis. *Ann Plast Reconstr Surg.* 2019; 3(1): 1026.

Copyright © 2019 Gerald Gui. This is an open access article distributed under the Creative Commons Attribution License, which permits unrestricted use, distribution, and reproduction in any medium, provided the original work is properly cited.

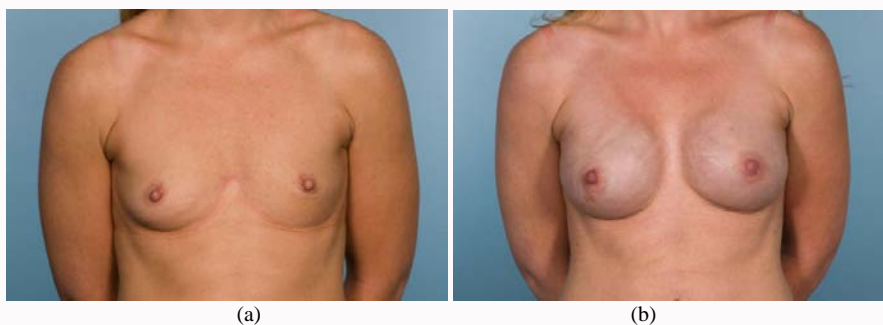


Figure 1: (a) Pre and (b) post-operative pictures showing maintenance of the nipple position and creation of a full upper pole using the tent technique after nipple sparing mastectomy in a patient with non-ptotic breasts.

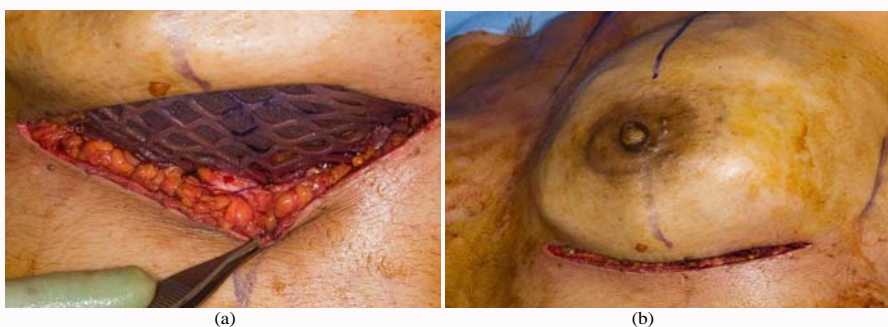

Figure 2: Intra-operative photograph of (a) the snug fit tent technique and (b) after skin-draping in the recreation of non-ptotic breasts.




Figure 3: Line drawing of (a) tent technique used conventionally to create a non-ptotic smaller breast shown in Figure 1; (b) enhanced hammock technique which we describe to create a larger pseudo-ptotic breast in our patient shown in Figure 4.

Tent technique in the recreation of non-ptotic breasts

This technique is used when a youthful appearance is desired (Figure 1a and b). Interrupted 3/0 PDS sutures are placed around the periphery of each of the superior, lateral, medial and inferior edges, suturing the ADM to the pectoralis fascia along the original mastectomy footprint. The sutures are placed through the spaces in the mesh or through the ADM substance itself, with the knots facing downwards and are thus covered by the ADM. The lateral position of the ADM controls the cleavage position of the implant and can be designed to match the contralateral breast. The inferior edge of the ADM is the aperture through which the implant is placed for central and inframammary crease incisions. For lateral incisions, the superior, medial and inferior surfaces are closed first, leaving the lateral aperture as the access site.

When inserting the implant, superior displacement of the mesh can be prevented by grasping the ADM mesh against the mastectomy skin flap between thumb and forefinger, and then inserting a Deaver retractor. The final mesh edge is then closed. At the inferior edge, the

dense fascial layer that forms the condensation of the superficial and deep lamellae can be used to re-enforce or repair the inframammary crease to prevent caudal displacement (Figure 2a,b and 3a). Three sutures are placed at each of the ADM edges to secure implant position.

Enhanced hammock technique in the recreation of ptotic breasts

In the example provided, the patient has previously had an implant assisted latissimus dorsi flap to treat a right breast cancer when aged 40 years (Figure 4a). At age 52 years, she developed a left breast cancer and the reconstructive aim was to create a similar breast. This would not be achieved by using a pre-pectoral mesh in the conventional way as a “tent” approach (Figure 1a,b and 3a).

In order to create ptosis the surface markings of the implant foot print must be placed lower on the chest wall, with the superior suture line often just above the level of an idealized nipple position in a non-ptotic breast on the trunk (Figures 3b and 4b). As this

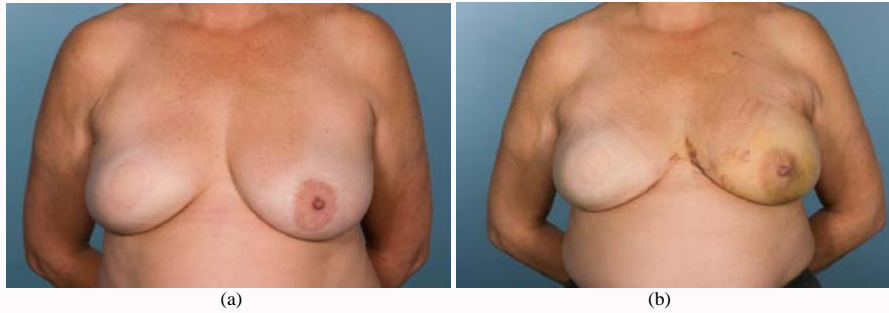


Figure 4: (a) Pre and (b) post-operative pictures showing the creation of a ptotic left breast using the extended hammock technique to match a contralateral pre-existing right implant assisted latissimus flap.

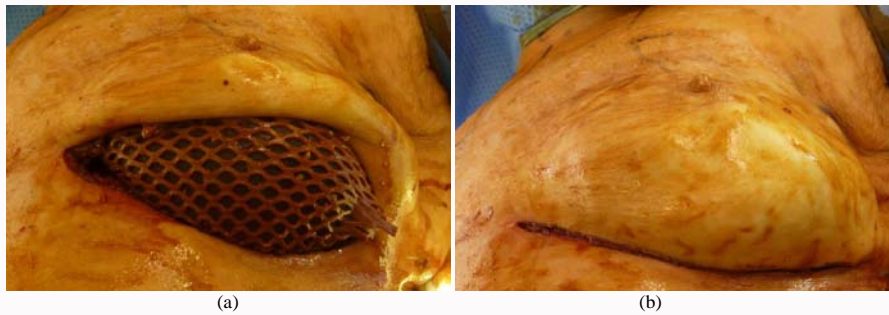


Figure 5: Intra-operative photograph of (a) extended hammock technique and (b) after skin-draping in creating a ptotic breast.

upper boundary does not usually match the mastectomy footprint, more sutures are placed on the superior border to prevent cranial dislocation of the implant, followed by standard lateral and medial sutures. Once the implant is introduced into the pocket, the patient is sat up on the operating table, and the skin envelope is draped over the implant to match the contralateral side. The lower boundary of the implant is intended to lie below the inframammary crease in this position (Figure 5a and 5b). True ptosis is created by suturing the free inferior ADM edge approximately one-third up the posterior implant length on the pectoralis fascia, thus creating an enhanced hammock. The patient is returned to the supine position to suture this inferior edge, suturing away from the implant to prevent iatrogenic injury. The final position of the implant is checked with the patient upright again before final three-layer closure.

Discussion

Surgimend® PRS meshed is a biological ADM designed for pre-pectoral implant reconstruction. The natural versatility allows it to either snugly fit the implant for non-ptotic breast reconstructions or extended as a hammock with the implant placed low on the chest wall to create ptotic breasts. Although it is possible to fold the ADM around the entire implant periphery, the authors prefer minimizing the amount of implanted ADM to just the inferior hammock, as there is no additional benefit from posterior coverage. The avoidance of ADM pleating at the suture points ensures efficient mesh integration and avoids palpable nodules through the skin, particularly in thin patients.

The creation of a hammock takes advantage of the tensile strength of a biological meshed ADM and allows the mastectomy skin envelope, ADM and implant to move as one composite unit. Suturing the ADM with the stretched axis in the cranio-caudal axis contributes to the elasticity and natural positional movement of the

breast reconstruction. The ability to create ptosis with a direct-to-implant technique expands the repertoire of implant reconstruction and reduces the need for contralateral symmetrisation.

The pre-pectoral approach is the natural successor to sub-pectoral implant breast reconstruction. As with all forms of breast reconstruction, the key to successful outcomes is patient selection, good quality mastectomy skin flaps, with particular care in smokers and patients with significant comorbidities. Surgimend® PRS meshed is easy to handle with versatile application and is a further tool in the kit-box of the reconstructive surgeon.

References

1. Namnoum JD. Expander/implant reconstruction with AlloDerm: Recent experience. *Plast Reconstr Surg.* 2009;124(2):387-94.
2. Schefflan M, Colwell AS. Tissue reinforcement in implant-based breast reconstruction. *Plast Reconstr Surg Glob Open.* 2014;2(8):e192.
3. Ball JF, Sheena Y, Tarek Saleh DM, Forouhi P, Benyon SL, Irwin MS, et al. A direct comparison of porcine (Strattice) and bovine (Surgimend) acellular dermal matrices in implant-based immediate breast reconstruction. *J Plast Reconstr Aesthet Surg.* 2017;70(8):1076-82.
4. Salzberg CA. Nonexpansive immediate breast reconstruction using human acellular tissue matrix graft (AlloDerm). *Ann Plast Surg.* 2006;57(1):1-5.
5. Tasoulis MK, Iqbal FM, Cawthorn S, MacNeill F, Vidya R. Subcutaneous implant breast reconstruction: Time to reconsider? *Eur J Surg Oncol.* 2017;43(9):1636-46.
6. Bertozzi N, Pesce M, Santi P, Raposio E. One-stage immediate breast reconstruction: A concise review. *Biomed Res Int.* 2017;2017:6486859.
7. Negenborn VL, Dikmans REG, Bouman MB, Winters HAH, Twisk JWR, Ruhe PQ, et al. Predictors of complications after direct-to-implant breast reconstruction with an acellular dermal matrix from a multicentre randomized clinical trial. *Br J Surg.* 2018;105(10):1305-12.

8. Lardi AM, Ho-Asjoe M, Mohanna PN, Farhadi J. Immediate breast reconstruction with acellular dermal matrix: Factors affecting outcome. *J Plast Reconstr Aesthet Surg.* 2014;67(8):1098-105.
9. Potter S, Chambers A, Govindajulu S, Sahu A, Warr R, Cawthorn S. Early complications and implant loss in implant-based breast reconstruction with and without acellular dermal matrix (TecnoSS Protexa(R)): a comparative study. *Eur J Surg Oncol.* 2015;41(1):113-9.
10. Vardanian AJ, Clayton JL, Roostaeian J, Shirvanian V, Da Lio A, Lipa JE, et al. Comparison of implant-based immediate breast reconstruction with and without acellular dermal matrix. *Plast Reconstr Surg.* 2011;128(5):403e-10e.
11. Headon H, Kasem A, Manson A, Choy C, Carmichael AR, Mokbel K. Clinical outcome and patient satisfaction with the use of bovine-derived acellular dermal matrix (SurgiMend) in implant based immediate reconstruction following skin sparing mastectomy: A prospective observational study in a single centre. *Surg Oncol.* 2016;25(2):104-10.
12. Negenborn VL, Young-Afat DA, Dikmans REG, Smit JM, Winters HAH, Don Griot JPW, et al. Quality of life and patient satisfaction after one-stage implant-based breast reconstruction with an acellular dermal matrix versus two-stage breast reconstruction (BRIOS): Primary outcome of a randomised, controlled trial. *Lancet Oncol.* 2018;19(9):1205-14.
13. Sorkin M, Qi J, Kim HM, Hamill JB, Kozlow JH, Pusic AL, et al. Acellular dermal matrix in immediate expander/implant breast reconstruction: A multicenter assessment of risks and benefits. *Plast Reconstr Surg.* 2017;140(6):1091-100.
14. Onesti MG, Maruccia M, Di Taranto G, Albano A, Soda G, Ballesio L, et al. Clinical, histological, and ultrasound follow-up of breast reconstruction with one-stage muscle-sparing "wrap" technique: A single-center experience. *J Plast Reconstr Aesthet Surg.* 2017;70(11):1527-36.
15. Forsberg CG, Kelly DA, Wood BC, Mastrangelo SL, DeFranzo AJ, Thompson JT, et al. Aesthetic outcomes of acellular dermal matrix in tissue expander/implant-based breast reconstruction. *Ann Plast Surg.* 2014;72(6):S116-20.
16. Salzberg CA, Dunavant C, Nocera N. Immediate breast reconstruction using porcine acellular dermal matrix (Strattice): long-term outcomes and complications. *J Plast Reconstr Aesthet Surg.* 2013;66(3):323-8.
17. Haynes DF, Kreithen JC. Vicryl mesh in expander/implant breast reconstruction: long-term follow-up in 38 patients. *Plast Reconstr Surg.* 2014;134(5):892-9.
18. Tessler O, Reish RG, Maman DY, Smith BL, Austen WG Jr. Beyond biologics: Absorbable mesh as a low-cost, low-complication sling for implant-based breast reconstruction. *Plast Reconstr Surg.* 2014;133(2):90e-9e.
19. Paydar KZ, Wirth GA, Mowlds DS. Prepectoral breast reconstruction with fenestrated acellular dermal matrix: A novel design. *Plast Reconstr Surg Glob Open.* 2018;6(4):e1712.
20. Kankam HKN, Hourston GJM, Fopp LJ, Benson JR, Benyon SL, Irwin MS, et al. Trends in post-mastectomy breast reconstruction types at a breast cancer tertiary referral centre before and after introduction of acellular dermal matrices. *J Plast Reconstr Aesthet Surg.* 2018;71(1):21-7.
21. Cattelani L, Polotto S, Arcuri MF, Pedrazzi G, Linguadoca C, Bonati E. One-step prepectoral breast reconstruction with dermal matrix-covered implant compared to submuscular implantation: Functional and cost evaluation. *Clin Breast Cancer.* 2018;18(4):e703-e11.
22. Reitsamer R, Peintinger F. Prepectoral implant placement and complete coverage with porcine acellular dermal matrix: A new technique for direct-to-implant breast reconstruction after nipple-sparing mastectomy. *J Plast Reconstr Aesthet Surg.* 2015;68(2):162-7.
23. Berna G, Cawthorn SJ, Papaccio G, Balestrieri N. Evaluation of a novel breast reconstruction technique using the Braxon ((R)) acellular dermal matrix: A new muscle-sparing breast reconstruction. *ANZ J Surg.* 2017;87(6):493-8.