



Mesenteric Teratoma in Adult Female: A Rare Case

Cesar Oropeza-Duarte¹, Daniel Monraz-Alvarez¹, Karla Leonher-Ruezga¹, Daniela Suarez-Velazquez¹, Karlagarcia-Moran¹, Maria Fernanda Garcia-Colunga¹ and Quitzia Libertad Torres-Salazar^{2*}

¹Department of General Surgery, Hospital Dr. Valentin Gomez Farias, Institute of Safety and Social Services for State Workers, Mexico

²Department of General Surgery, Juarez University of the State of Durango, Mexico

Abstract

Background: Mesenteric teratomas are considered rare intra-abdominal tumors with minimum clinical symptoms, which turn difficult their preoperative diagnosis. They represent a poorly studied pathology that has been established with 1 in 26,794 to 250,000 frequencies of hospital admissions. It is not frequent to think about this kind of lesion in a preoperative period, and the symptoms it presents can be very ambiguous. Therefore, in this study we present a case of acute abdomen, in a 65-year-old Mexican woman, in which a mesenteric teratoma was obtained as a surgical finding.

Case Report: 65-year-old woman who presented a clinical picture of abdominal pain and distention, nausea and constipation, as well as absence of gas channeling in the last 24 h. After 48 h of conservative management, without favorable results and with a diagnosis of acute abdomen, surgery was entered to perform exploratory laparotomy and an intraoperative finding of mesenteric teratoma was made. Two ovoid specimens were extracted and sent to the pathology area, who confirms the diagnosis of mature cystic teratoma.

Conclusion: Teratoma is commonly a germ cell tumour that originates in the gonads and is detected in women of reproductive age. This is extremely rare, with an estimated 21 cases reported to date. Despite the low frequency, it is suggested to it considered these teratomas in the differential diagnosis against other pathologies, especially if they do not show a very clear data.

Keywords: Case report; Mesenteric teratoma; Dermoid cyst; Mature cystic teratoma

Abbreviations

H&E: Hematoxylin and Eosin; CT scan: Computed Axial Tomography; MRI: Magnetic Resonance Imaging

Background

Mature cystic teratomas are benign neoplasms of germ cell tumors that occur most frequently at gonadal sites [1]. Tumors generally contain 2 or 3 well-differentiated elements of endodermal, ectodermal, and mesodermal origin. Although it is relatively rare, teratomas can be composed of mature tissue that originates from a single layer of germ cells. This is known as a monodermal teratoma.

The term teratoma derives from the Greek "teras" (terat) which means monster, and the suffix "oma" which is used to form nouns indicating disease, tumors or masses. This word was proposed by Rudolf Virchow in 1869 given the diversity of the anatomical component in the sacrococcygeal type [2]. The first description of a mesenteric cyst was made by Beneviene in 1507, during the autopsy of an eight-year-old boy [3].

Various authors have taken on the task of publicizing the cases they have diagnosed and treated, or making a retrospective compilation of their hospital centers (Table 1) [1,4-9].

The best current definition of this term, is the one given by Willis: "Teratomas are tumors or neoplasms formed by various foreign tissues that arise in an abnormal location; this is different from cases that contain recognizable immature organs developed within the mass, as a result of the separation of the fertilized ovum early in pregnancy called fetus from fetus" [2].

These tumors commonly occur in childhood or adolescence, and the gonads are the main common site of its appearance. Mesenteric teratomas are extremely rare, and its frequency has

OPEN ACCESS

*Correspondence:

Torres-Salazar QL, Department of General Surgery, Juarez University of the State of Durango, Calle Paloma No.806, Colonia Fatima, 34060 Durango, Dgo, Mexico, Tel: +52 618 8230924;

E-mail: quitzia.torres@gmail.com

Received Date: 11 Feb 2022

Accepted Date: 15 Mar 2022

Published Date: 31 Mar 2022

Citation:

Oropeza-Duarte C, Monraz-Alvarez D, Leonher-Ruezga K, Suarez-Velazquez D, Karlagarcia-Moran, Garcia-Colunga MF, et al. Mesenteric Teratoma in Adult Female: A Rare Case. *J Plast Surg.* 2022; 2(1): 1010.

Copyright © 2022 Quitzia Libertad Torres-Salazar. This is an open access article distributed under the Creative Commons Attribution License, which permits unrestricted use, distribution, and reproduction in any medium, provided the original work is properly cited.

Table 1: List of reported mesenteric teratoma cases.

Author	Year of Publication	Diagnosis
Jones & Burns et al. [4]	2013	Retroperitoneal teratomas
Lakshman et al. [5]	2018	Maturecystic teratoma of mesentery
Loh Z et al. [6]	2020	Mesenteric metastases from mature teratoma of the testis
Tanaka Y et al. [1]	2014	Mesenteric teratoma
Neeralagi CS et al. [7]	2017	Maturecystic teratoma of mesentery
Ayas MF et al. [8]	2020	Mesenteric Cyst Mimicking a Biloma
Papakonstantinou E et al. [9]	2011	Extraovarian mature cystic teratoma of the mesentery

been established from 1/26,794 to 1/250,000 of hospital admissions; however, statistics are scarce [10].

Various modalities of mesenteric cysts can be described, such as the following: 1) cyst of lymphatic origin (simple lymphatic cysts and lymphangiomas); 2) cysts of mesothelial origin (simple mesothelial cyst, benign cystic mesothelioma and malignant cystic mesothelioma); 3) cysts of enteric origin (enteric cysts and enteric duplication cysts); 4) cysts of urogenital origin; 5) mature cystic teratoma (dermoid cysts); and 6) pseudocysts (infectious and traumatic cysts) [11,12]. Three clinical forms are recognized, depending on the location, size of the tumor and the relationship with neighboring organs: 1. Incidental form, 2. Non-specific clinical picture, and 3. Acute abdomen syndrome [13].

Case Presentation

A 65 year old Mexican patient who attended the surgery service for stabbing abdominal pain, located in the mesogastrium and of variable intensity, reaching an 8/10 on the visual analogue pain scale. She also presented dissident abdominal pain and nausea, as well as absence of actions or gas channeling since the last 24 h prior to her evaluation. The patient has long-term chronic hypertension, G3 P3 without previous surgical interventions, and does not refer to other important clinical history.

On physical examination, she presented dehydrated mucosa, abdominal distension, slightly increased peristalsis in frequency of intensity, slightly depressible soft abdomen with diffuse pain on medium and deep palpation, and a negative rebound, without wall resistance.

Conservative management begins with gastric decompression using a nasogastric tube, fasting, and fluid replacement. We decided to perform the management with an exploratory laparotomy due to lack of improvement in the patient after the first 48 h. The final diagnosis was an acute abdomen. The hematological and biochemical

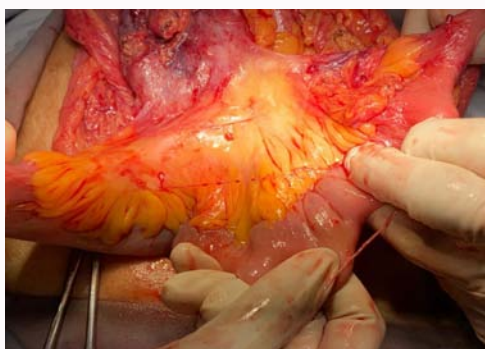


Figure 1: A tumour dependent on the mesentery is observed.

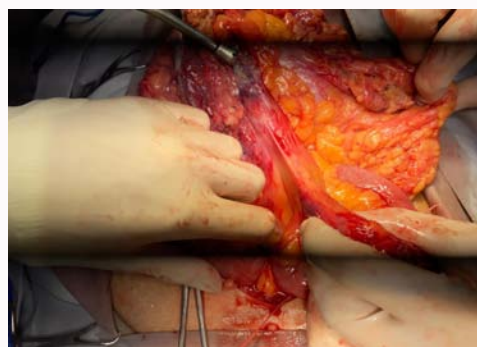


Figure 2: During blunt dissection of a tumour adhering to the mesentery, there is rupture of the same with purulent matrix leakage and hair content is observed.

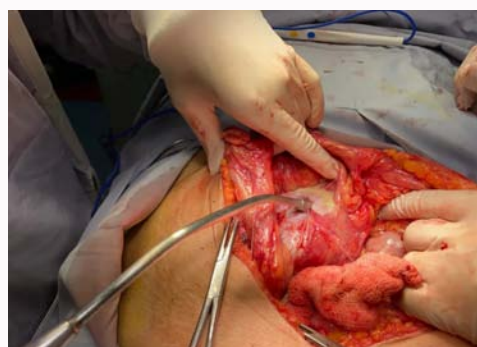

Figure 3: Blunt dissection and aspiration of purulent material.

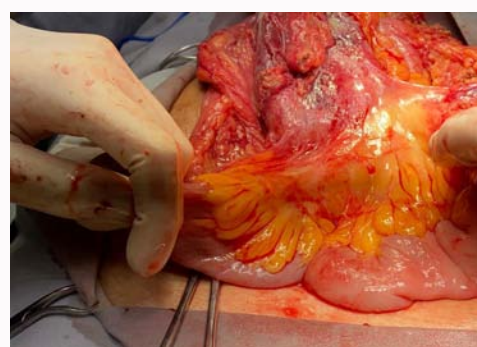


Figure 4: Dissection and demonstration of a tumour of mesenteric origin, without compromising intestinal irrigation.

parameters were within normal limits.

Surgical Technique

Under balanced general anesthesia, in the supine position,

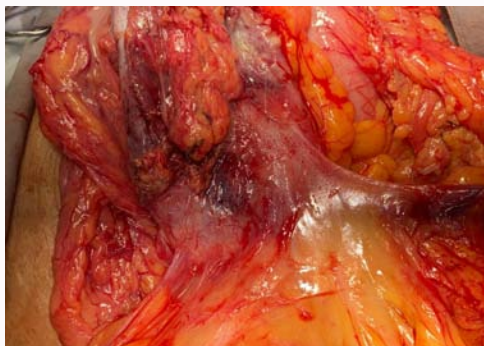


Figure 5: Completely dissected tumour ready for total resection.

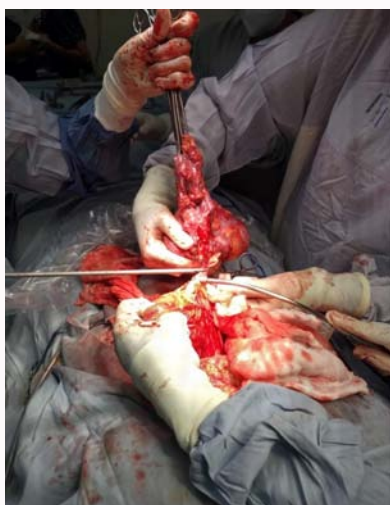

Figure 6: It is finished drying with a harmonic scalpel from its nutrient artery.

asepsis, antisepsis and placement of sterile curtains were performed. An incision was made in the supra and infraumbilical midline and dissected by planes with electrocautery in the opening of the abdominal cavity. A citrine free liquid leakage occurred; approximately 200 cc are aspirated, and 10 cc were sent to cytology or cytochemistry.

Proximally dilated loops of the small intestine were identified.

Next, evisceration is performed, identifying two tumors at the level of the mesentery in small intestine (Figure 1), approximately 130 cc from Treitz angle. The first one of an estimated size of 20 cm × 15 cm, with adherence on omentum; and the second one with an ovoid shape with approximately 6.5 cm of diameter.

Adherenciolysis is performed with a cold cut and a harmonic scalpel. The tumor is skirted and dissected, nevertheless, there is an accidental breakage with leakage of purulent material and the existence of hair is observed (Figure 2). A cross stitch is placed to close the tumor and control the secretion and the dissection continues (Figure 3).

Consequently, the root of the tumour and the nutrient vessel from the mesentery are identified (Figure 4, 5). The tumour is resected with a harmonic scalpel and the surgical specimen is extracted (Figure 6). It is sent to pathology routinely, then, hemostasis is verified with no evidence of bleeding or intestinal injury and metastatic disease in the liver is intentionally searched sliding, annexes, without alterations. A textile count is requested from the nursing staff, reporting complete, cavity closure, and anterior aponeurosis with vicryl from 1 continuous surgete, subcutaneous cellular tissue with vicryl from 2-0 continuous surgete, and skin with nylon from 3-0 medium Sarnoff points. A sterile dressing is placed, ending the surgical procedure without incidents or accidents and minimal bleeding. Patient goes to recovery under residual effects of anesthesia.

The pathology report confirms the reception of two specimens. The first one, ovoid with a smooth external surface and integrates that measures 6.5 cm in diameter. When we proceeded to cut it, it presented a cystic appearance and contains abundant thick and grey material and hair. Its internal surface was smooth, with a central area irregular and nodular 3 cm in diameter made up of bone tissue. The second one was an ovoid specimen with a gray, rough and integral external surface measuring 15 cm × 11 cm; it was cystic and contained brown and thick material with hair, the internal surface is rough with solid focal areas. The lamellae were stained with H&E. Microscopic observation revealed histological sections of the wall of a cyst lined

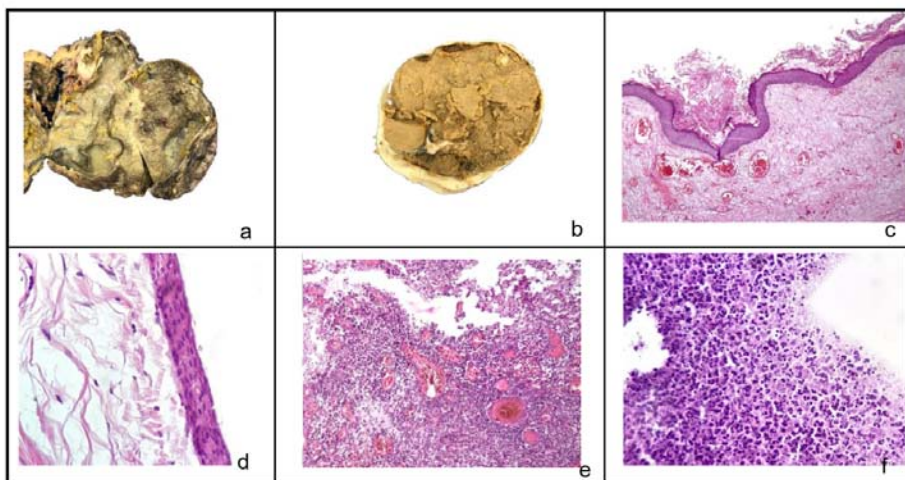


Figure 7: a) Cystic specimens sectioned in half, the largest measuring 15 cm × 11 cm and the smallest b) 6.5 cm in diameter. Both contain thick material, gray and hair. c) Histological section of the wall of one of the cystic teratomas lined by keratinizing squamous epithelium. d) At higher magnification, the epithelial cells do not show atypia changes. e) The major cyst presents extensive areas of epithelial ulceration and a mixed inflammatory infiltrate. f) Cytological smears contain abundant polymorphonuclear cells and cellular debris. No microorganisms are identified.

by stratified squamous epithelium with superficial keratinization and squamous cells without data of cellular atypia, supported by a fibrous and dense stroma. There was bone tissue in the minor cyst and extensive ulceration with a mixed and intense inflammatory infiltrate with congestion in the larger specimen (Figure 7). The histopathological diagnosis is as follows: Two mature cystic teratomas, with no evidence of immature elements or malignancy.

Discussion

A teratoma is commonly a germ cell tumour that originates in the gonads and is usually found in women during their reproductive age. Teratomas in the gastrointestinal tract are rare. Teratomas are usually found in the sacrococcygeal area (47.2%), in the gonads (31.6%) and less frequently in other areas, and rarely in the mesentery [14].

During development, the germ cell migrates from the yolk sac to the genital ridge through the hindgut (mesentery pathway); this explains its development in an abnormal location such as the mesentery [15].

Most mesenteric cysts are benign and those that are considered malignant represent less than 3% [11]. It is an infrequent entity with slow growth without pathognomonic clinical data, whose diagnosis is not considered in the preoperative period and is generally diagnosed as an imaging finding.

Despite the above, it is considered that regardless of its low frequency, this must be considered in the differential diagnosis. Cases such as the one reported by Vallejo-Soto et al. [16], in which the presence of a giant mesenteric cyst is described that was confused with a liver problem generated by ascites and intractable, can be emphasized. Mesenteric teratomas can occur at any age, from newborns to adult patients, the same trend seen in the previously reported literature on mesenteric cysts. According to a review by Tanaka et al. [1], the average tumor size is approximately 10 cm in most cases, indicating that mesenteric teratomas are undetectable unless they grow to a considerable size and cause the patient various symptoms.

There is no consensus regarding standard of diagnosis and open or endoscopic surgical treatment for these teratomas [10]. In some hospital units in our country, ultrasound may be a more accessible method. However, it should not be overlooked that CT scan can provide more information to assess the convenience of the surgical technique to be performed.

Unfortunately, in urgent cases such as the one presented in the patient, the dilemma of waiting times is interposed. This, in order to perform the CT scan and being able to have a timely admission to the ward, avoiding potential complications.

This case presented is consistent with other reports in the literature where it has been described that, although images such as CT scan or MRI can facilitate the diagnosis of mesenteric teratomas, only 4 of 21 patients (19%) have been diagnosed before surgery [17,18].

Conclusion

An abdominal teratoma is an extremely rare abnormality. However, it is considered that it should be taken into account as

one of the differential diagnosis of abdominal mass, although it is usually benign. There is no consensus regarding standard of diagnosis and open or endoscopic surgical treatment for these teratomas. Nevertheless, its total excision is the mainstay of treatment, in addition to a careful histopathological examination and a mandatory close follow-up.

References

1. Tanaka Y, Koyama S, Shiki Y. Hand-assisted laparoscopic surgery for a mesenteric teratoma. *JLS*. 2014;18(1):160-4.
2. Al-Salem A, Hamchou M, Nawaz A, Matta H. Teratoma in infants and children. *Continuing Medical Education. Curr Opin Pediatr*. 2015;9(2):1-12.
3. Al-Mulhim AA. Laparoscopic excision of a mesenteric cyst during pregnancy. *JLS*. 2003;7(1):77-81.
4. Jones VS, Burns CR. Operative considerations in pediatric retroperitoneal teratomas--a review. *Eur J Pediatr Surg*. 2013;23(4):265-9.
5. Lakshman V, Chikkannaiah P, Venkataramappa S. Mesenteric cystic teratoma masquerading as acute abdomen. *J Gastrointest Cancer*. 2018;49(4):522-4.
6. Loh Z, Manning TG, O'Brien JS, Perera M, Lawrentschuk N. Mesenteric metastases from mature teratoma of the testis: A case report. *Asian J Urol*. 2020;7(3):322-5.
7. Neeralagi CS, Surag KR, Kumar Y, Lakkanna S, Raj P. Mesenteric teratoma in elderly female: A rare case report. *J Clin Diagn Res*. 2017;11(1):PD01-2.
8. Ayas MF, Affas S, Hoilat GJ, Kassab I, Barawi M. A case of a mesenteric cyst mimicking a biloma. *Gastroenterology Res*. 2020;13(6):279-82.
9. Papakonstantinou E, Iavazzo C, Hasiakos D, Kleantith CK, Fotiou S, Kondi-Pafiti A. Extraovarian mature cystic teratoma of the mesentery. A case report and literature review. *Clin Exp Obstet Gynecol*. 2011;38(3):291-3.
10. Granados-Romero J, Valderrama J, Sevilla-Dominbgo M. Mesenteric cyst approach, a not so uncommon entity. Presentation of a case. *Endoscopic Surgery*. 2014;14(1):34-8.
11. De Perrot M, Brundler MA, Totsch M, Mentha G, Morel P. Mesenteric cyst. Toward less confusion? *Dig Surg*. 2000;17(4):323-8.
12. Sosa HR, Sanchez PC, Simon RL. Cyst of the mesentery: Report of a case and review of the literature. *Rev Cubana Cir*. 2007;46(4):1561.
13. Rivera MM, Barrera JA, Basavilvazo RA. Mesenteric cysta case report. *Rev Med Inst Mex Seg Soc*. 2008;46(10):423-6.
14. Abdullatif AA, Shawarby Mohammad AE, Mulhim Fatma AA, Amer AL. Mesenteric cystic teratoma in children. *Saudi Med J*. 2003;24(12):1388-90.
15. Nischal R, Vidyadish S. Case report: A case of jejunal mesenteric teratoma in adult male: A rare case. *Indian J Surg Oncol*. 2020;11(2):193-5.
16. Soto MV, Simental SO. A giant mesenteric cyst mimicking untreatable ascites. *Rev Gastroenterol Mex*. 2017;82(4):348-51.
17. Marcolongo A, Divirgilio G, Bettini G, Camoglio FS, Fasoli L, Marradi P, et al. Immature mesenteric teratoma in a male newborn infant: Prenatal ultrasonographic diagnosis and surgical treatment. *Prenat Diagn*. 1997;17(7):686-8.
18. Rattan KN, Ratan SK, Jhanwar A, Kaushik V, Magu S. Immature mesenteric teratoma causing intestinal obstruction. *Indian J Pediatr*. 2007;74(2):207-8.