



Management of Penetrating Carotid Artery Injury due to Blast in Hospital Premises

Prashant Moon*

Department of Plastic and Reconstructive Surgery, Krishna Hospital and Research Centre, India

Abstract

Penetrating common carotid injuries are life threatening and requires urgent intervention. Early diagnosis of injury and prompt treatment is required to save life of the patient and prevent neurovascular damage due to ischemia to brain. We are presenting a case of penetrating carotid artery injury due to blast of an outdoor unit of AC while repairing. Here, we report on management of unilateral common carotid artery injury in zone II with Micro vascular repair technique using vein graft.

Keywords: Carotid artery; Blast injury; Penetrating injury; Micro-vascular repair

Introduction

Penetrating injury to the carotid artery is very rare injury. Prompt measure to control bleeding and to establish vascular continuity is required to save life and optimal brain function. Due to its high blood flow, ruptures caused by accidents such as stab wounds, gunshot wounds, car accident injuries can cause rapid and massive blood loss in a short period, which can be lethal cases without timely treatment [1]. Many times, diagnostic work up is not possible due to profuse bleeding. We are reporting a case of penetrating carotid artery injury in zone II of the neck due to accidental blast injury from outdoor unit of air conditioner in hospital premises.

Case Presentation

35 year old man had sustained injury to his neck due to blast of outdoor unit of air conditioner in the hospital. Patient had developed a profuse bleeding from neck followed by collapse. Patient was immediately carried out to the casualty of a hospital where compression has been applied. Patient's vitals on arrival were blood pressure 90/60 mmhg, pulse 118/min, respiratory rate was 34/min. Patients GCS at the time of arrival was 7/15. Patient had an entry wound in zone II of left side of neck with spurting of fresh blood from the wound. Bleeding initially managed with finger compression from the entry wound. Due to continual blood loss entry wound was packed with gauze and closed with suture (Figure 1). Patient was directly taken to operation theatre. Central line was inserted and blood transfusion has been started. General anaesthesia was given and exploration of wound was done with inverted 'T' incision (Figure 2). On exploration there was an oblique near total laceration to common carotid artery in zone II. Proximal and distal carotid artery carefully dissected and controlled with silicon vessel loop. Left great saphenous vein harvested from left leg and reversed. Complete transaction of carotid artery was done and reverse interposition vein graft was used to re-establish carotid artery continuity (Figure 3). Sharp metal piece was removed from sterno-thyroid muscle. Trachea was found to be intact. Complete hemostasis achieved and closure was performed in layer. Patient was shifted to intensive care unit for further management. Three unit of whole blood and three unit of fresh frozen plasma were given to the patient in post operative period. Patient had a superficial burn over face and upper chest which was managed conservatively with dressing. Rest of post operative recovery was uneventful. Patient was discharge on 9 post operative day (Figure 4). No anticoagulation was used in post operative period. Patient had not sustained any neurovascular deficit in post operative period (Figure 5).

Discussion

Anatomy of neck is very complicate and understanding of structure passing through neck is very important. The common carotid artery starts from the brachiocephalic trunk from right side and from the aortic arch on left side. Carotid artery enclosed in a sheath called carotid sheath. Carotid sheath also contains internal jugular vein and vagus nerve [1]. At approximately the level of the fourth cervical vertebra, the common carotid artery bifurcates into an internal carotid artery

OPEN ACCESS

*Correspondence:

Prashant Moon, Department of Plastic and Reconstructive Surgery, Krishna Hospital and Research Centre, Haldwani, Uttarakhand, India, Tel: 9100423529;

E-mail: prashantmoon@gmail.com

Received Date: 12 Apr 2019

Accepted Date: 29 Jul 2019

Published Date: 01 Aug 2019

Citation:

Moon P. Management of Penetrating Carotid Artery Injury due to Blast in Hospital Premises. *Ann Plast Reconstr Surg.* 2019; 3(3): 1034.

Copyright © 2019 Prashant Moon. This is an open access article distributed under the Creative Commons Attribution License, which permits unrestricted use, distribution, and reproduction in any medium, provided the original work is properly cited.

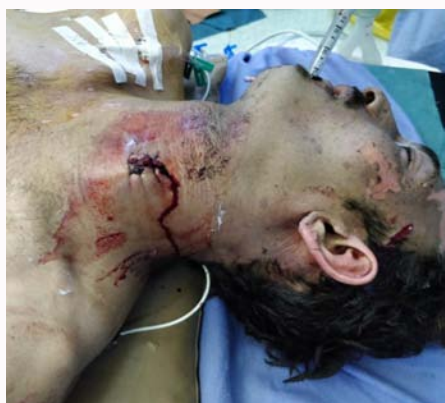

Figure 1: Initial resuscitation and packing of neck wound.

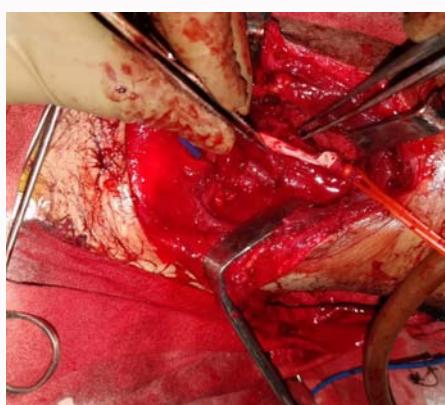


Figure 2: Carotid artery injury more than 75% of its circumference.

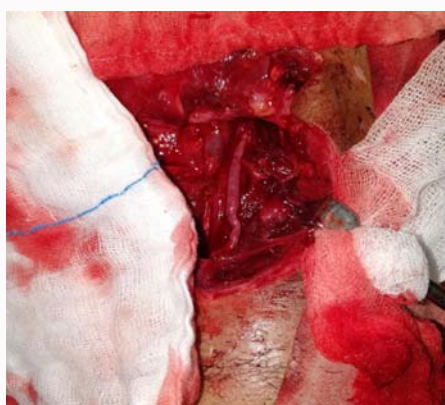


Figure 3: Interposition vein graft for Carotid artery repair.

and an external carotid artery in the carotid triangle. External Carotid Artery (ECA) is the chief artery of head and neck region. It begins lateral to upper border of thyroid cartilage, level with disc between the third and fourth cervical vertebrae. At its origin, it is in the carotid triangle and lies antero-medial to internal carotid artery but becomes anterior and lateral to it as it ascends [2,3].

Vascular trauma to the neck is classified into two major categories, namely blunt or penetrating, according to the mechanism of vascular injury [4]. Penetrating vascular trauma of the neck is observed mainly in males, and in 70% to 90% of all carotid injuries the damage is located in the common carotid artery [5].

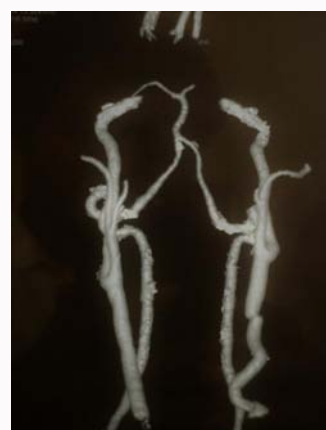

Figure 4: CT angiogram showing Patent.

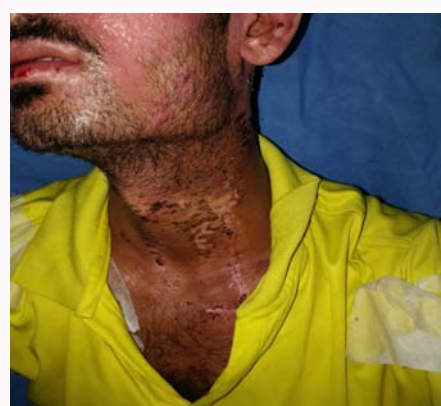

Figure 5: Post operative result.

Morbidity and mortality is very high in penetrating artery injury if not treated immediately. Other injuries associated with common carotid artery are tracheal injury, oesophagus injury, recurrent laryngeal nerve injury and brachial plexus injury [6].

Carotid artery injury is classified three zones. Zone 1 starts from clavicle and sterna notch to the cricoid cartilage. Zone 2 starts from cricoids cartilage to the angle of mandible. Zone 3 starts from angle of mandible to base of skull [7].

Clinical examination of patient is very crucial in penetrating neck injury. Direction of injury, mechanism of injury and instrument causing injury is very important. When Patient presents in casualty with pulsatile bleeding from neck wound, immediate tamponade should be applied over bleeding neck wound by pressing carotid artery against vertebral column [8]. In our patient we have tried to apply finger pressure over carotid artery through penetrating wound. Due to repeated slippage and bleeding, we packed the cavity with gauze and over suture the skin over penetrating wound after taking airway control by endotracheal tube [9]. Too light application can lead to excess haemorrhage while too tight compression may cause compression over trachea and great vessels in the neck.

Open surgical procedure is the gold standard for management of all zones of penetrating carotid injuries and there is currently a rising trend to the combined endovascular and open surgical approach [8,9].

Most of penetrating injuries in Zone II need to be investigated on

the operating table. According to Reva et al. [9] surgical repair should be pursued even in asymptomatic patients with a penetrating injury. CT angiography, DSA and oesophageal study can be done in patients who are hemodynamically stable and equivocal signs suggestive of carotid artery injury.

Surgical repair of penetrating injuries includes primary suturing, end-to-end anastomosis, suturing of a venous patch or interposition of a venous or synthetic graft when the carotid wall is significantly damaged (Grades III-V) [10,11]. In our case carotid artery was cut obliquely in more than 75% of its circumference hence complete transection and repair with reverse saphenous vein graft was done.

Anaesthesia and critical care in such patient is very crucial. Immediate intubation in emergency room and early ambulation of patient to operating room lead to better outcome. Maintenance of deep level of sedation, local hypothermia and lower blood pressure in peri-operative period is helpful in decreasing cerebral ischemia during operation [12].

In early post operative period neck movement should be prevented with soft neck collar. Angiography should be done in early postoperative period for evaluation of continuity of carotid artery. Closed monitoring should be done for two week to identify any complication like infection, carotid blow out, and pseudoaneurysm formation.

To summarise, we are presenting an uncommon case of penetrating injury to common carotid artery. Though such arterial injury is result in immediate death or cerebral ischemia and stroke, this did not occur in our case. Immediate control of life threatening bleeding, early ambulation to operating room and immediate exploration and restoration of continuity helps in salvage of patient's life and prevention of a cerebrovascular event.

References

1. Gao N, Zhao Y, Zhang L, Wu W, Zhang J, Yang X. Treatment strategies for carotid artery penetrating injury: a case report and literature review. *Chinese Neurosurgical Journal*. 2017;3:37.
2. Chitra R. Trifurcation of the right common carotid artery. *Indian J Plast Surg*. 2008;41(1):85-8.
3. Richard SA, Zhang CW, Wu C, Ting W, Xiaodong X. Traumatic penetrating neck injury with right common carotid artery dissection and stenosis effectively managed with stenting: A case report and review of the literature. *Case Rep Vasc Med*. 2018;2018:4602743.
4. Lee TS, Ducic Y, Gordin E, Stroman D. Management of Carotid Artery Trauma. *Craniofac Trauma Reconstr*. 2014;7(3):175-89.
5. Kim JP, Park JJ, Won SJ, Woo SH. Penetrating Carotid Artery Injuries Treated by an urgent endovascular stent technique: Report of two cases. *Chonnam Med J*. 2011;47(2):134-7.
6. Varghese A. Penetrating neck injury: A case report and review of management. *Indian J Surg*. 2013;75(1):43-6.
7. Perinjelil V, Mercer L, Daoud FA, Nigan T, Marshall B, Khan SN, et al. Ligate to live: Stab wound to the neck with major vascular injuries. *J Surg Emerg Med*. 2017;1:11.
8. Mahmoodie M, Sanei B, Moazeni-Bistgani M, Namgar M. Penetrating neck trauma: Review of 192 cases. *Arch Trauma Res*. 2012;1(1):14-8.
9. Reva VA, Pronchenko AA, Samokhvalov IM. Operating management penetrating carotid artery injuries. *Eur J Vasc Endovasc Surg*. 2011;42(1):16-20.
10. Lichtenfels E, Cardozo MA, Erling N, Aerts NR. Endovascular treatment of iatrogenic penetrating trauma of the carotid artery: Case report. *J Vasc Brasil*. 2014;13(2):155-8.
11. Galyfos G, Stefanidis I, Kerasidis S, Stamatatos I, Geropapas G, Giannakakis S, et al. Carotid artery injury: Up-to-date management. *J Trauma Treat*. 2016;5:283.
12. Huh H, Han JH, Chung JY, Yi JW, Lee BJ, Kim DO, et al. Anesthetic management of penetrating neck injury patient with embedded knife - a case report. *Korean J Anesthesiol*. 2012;62(2):172-4.