



Lupoid Cutaneous Leishmaniasis due to *Leishmania major*, a Great Mimicker of Lupus Vulgaris in Sanliurfa, Turkey: A Case Report

Nebiye Yentur Doni^{1*}, Gulcan Gurses², İsa An³, Akın Yigin⁴ and Fadile Yildiz Zeyrek¹

¹Department of Medical Microbiology, Harran University, Sanliurfa, Turkey

²Department of Medical Microbiology, Vocational School of Health Services, Harran University, Sanliurfa, Turkey

³Ministry of Health, Health Sciences University, Sanliurfa Training and Research Hospital, Dermatology Clinic, Sanliurfa, Turkey

⁴Department of Veterinary Medicine, Harran University, Turkey

Abstract

A 24 year old man presented with a 3 to 5 months history of a well defined erythematous plaque extended to involve the whole left hand middle finger, resembling lupus vulgaris. He also presented 1 ulcerated lesion on his left shoulder, and 1 papulonodular lesion on his left arm. He was a textile worker. He could not use his left hand due to the huge lesion on his middle finger. Lupoid Cutaneous Leishmaniasis (LCL) is a clinical form of CL characterized by a chronic relapsing course, unusual clinical features, and a unique granulomatous lesion. Lupoid cutaneous leishmaniasis is identified by a broad range of clinical presentation with brown to red papules, yellowish-brown papules and, apple-jelly papules. A punch biopsy aspiration fluid from lesions was used, and a part of the exudate of fluid of the lupoid lesion was used for the identification of *Leishmania* species by Real Time PCR.

Keywords: Lupoid cutaneous leishmaniasis; Lupus vulgaris; *Leishmania major*

OPEN ACCESS

*Correspondence:

Nebiye Yentur Doni, Department of Medical Microbiology, Harran University, Sanliurfa, Turkey, Tel: +90 414 3180000 2333; Fax: +90 414 3182333; E-mail: n_doni@hotmail.com

Received Date: 13 Sep 2021

Accepted Date: 22 Oct 2021

Published Date: 01 Nov 2021

Citation:

Doni NY, Gurses G, An İ, Yigin A, Zeyrek FY. Lupoid Cutaneous Leishmaniasis due to *Leishmania major*, a Great Mimicker of Lupus Vulgaris in Sanliurfa, Turkey: A Case Report. *Am J Clin Microbiol Antimicrob.* 2021; 4(2): 1057.

Copyright © 2021 Nebiye Yentur Doni. This is an open access article distributed under the Creative Commons Attribution License, which permits unrestricted use, distribution, and reproduction in any medium, provided the original work is properly cited.

Introduction

Cutaneous Leishmaniasis (CL) is a dermal infection caused mostly by *Leishmania major*, *Leishmania tropica*, and *Leishmania infantum*, is transmitted to humans by the bite of Sandfly. Cutaneous leishmaniasis is polymorphic and may result in lesions characterized by different clinical features. Cutaneous leishmaniasis is also characterized by acute or chronic course. Lupoid Cutaneous Leishmaniasis (LCL) is a clinical form of CL characterized by a chronic relapsing course, unusual clinical features, and a unique granulomatous lesion [1].

Lupoid cutaneous leishmaniasis is identified by a broad range of clinical presentation with brown to red papules, yellowish-brown papules and, apple-jelly papules. These papulesen large to plaques, and develop into granulomatous and crusted ulcers, which are as similar as cutaneous lesions of lupus vulgaris. Here in, we report a patient with lupoid CL mimicking lupus vulgaris to high light the unusual clinical spectrum of CL.

Case Presentation

Clinical findings

A 24 year old man presented with a 3 to 5 months history of a well-defined erythematous plaque extended to involve the whole left-hand middle finger, resembling lupus vulgaris. He also presented 1 ulcerated lesion on his left shoulder, and 1 papulonodular lesion on his left arm. He was a textile worker. He could not use his left hand due to the huge lesion on his middle finger. While, his general physical examination and systemic examination were normal. The patient had no familial history for the development of CL. He had no travel to her CL endemic provinces. The patient had applied to different medical clinics in non-endemic provinces for CL for the diagnosis of the lesions he had. He was diagnosed as "lupus vulgaris" but he had not been treated for lupus vulgaris or CL. Then the patient applied to our dermatological clinic in Sanliurfa, a hyper-endemic province for CL.

Histopathological findings

Direct smears from the exudate of fluid of the lupoid lesion were stained with special stains

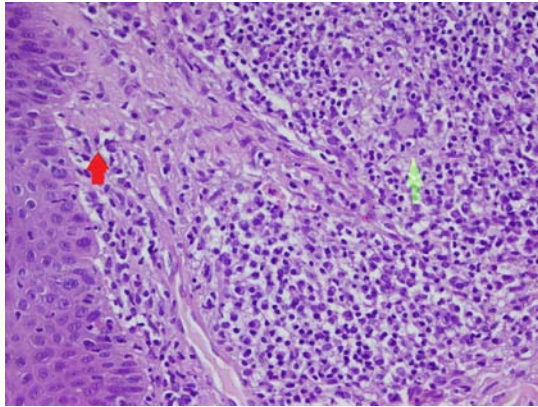


Figure 1: Non-caseified granulomas including giant cells (green arrow) and *Leishmania* amastigotes (red arrow) were seen in dermis (Hematoxylin-eosin, X200).

Gram, Erlich-Ziehl-Nielsen (EZN), Periodic Acid-Schiff (PAS), and Giemsa for detection of bacteria, mycobacteria, fungi and *Leishmania* amastigotes, respectively. A punch biopsy aspiration fluid from lesions was used, and a part of the exudate of fluid of the lupoid lesion was used for the identification of *Leishmania* species by Real Time PCR. Application of real time PCR that targeted the ITS1 region of *Leishmania* species using the DNAs obtained from the lesion of the patient. In this real time PCR, melting temperature of *L. major* reference control and sample is 85°C as described previously [2].

Results

Written informed consent to enroll the study and use clinical images in case report was obtained from the patient. Granuloma structures characterized by epithelioid histiocytes in the dermis were observed in the prepared sections. Langerhans-type multinucleate giant cells were noteworthy which were found in granulomas suggestive of leishmaniasis, tuberculosis with Hematoxylin-eosin staining (200x) (Figure 1). Intense mononuclear inflammatory cells surrounding the granuloma infiltrate the granuloma was also noteworthy. Granulomas were mostly observed in the dermis. The histomorphologically findings seemed to be compatible with lupus vulgaris. However, a definitive differential diagnosis could not be performed. No bacteria were observed with Gram staining, no Mycobacteria were observed with EZN staining and no fungal organism was observed with PAS staining. A few amastigotes of *Leishmania* were observed with Giemsa staining. Detection of *Leishmania* amastigotes by the microscopic examination of the direct smears exudative fluid of the lesions strictly supported the definitive differential diagnosis of lupoid CL. It has been reported that *Leishmania* amastigotes are usually absent on microscopy, thus, PCR is especially recommended for diagnosis of CL to prevent the delayed diagnosis or clinical and histological misdiagnosis often with Lupus vulgaris [3]. In light of this data, Real Time PCR was used to identify the *Leishmania* species, which was found to be *L. major* (Figure 2).

Identification of polymerase chain reaction products with melting temperature analysis of two *L. Major* sample sand two samples of *Leishmania major* be longed to the patient. The melting temperature is 85°C for *L. Major* MHOM/SR/2015/HRURFA012.

The patient with lupoid CL (Figure 3) was treated with intralesional meglumine antimoniate (Glucantime®) injections twice a week (Monday to Thursday) for four weeks. After four weeks, the

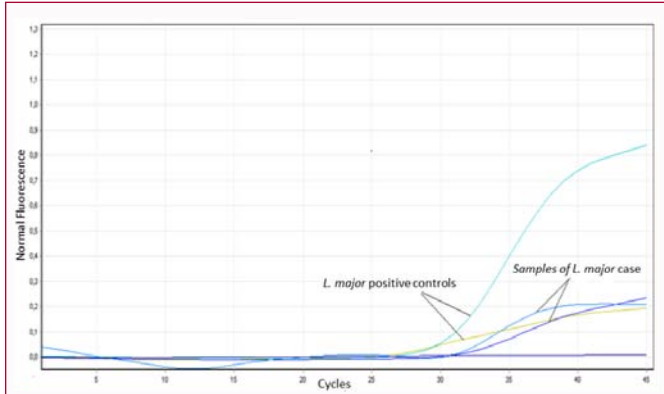


Figure 2: Real-time PCR analysis of *Leishmania major* infection in lesion of the patient.

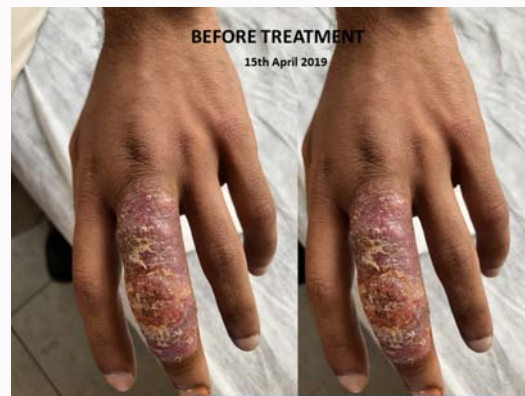

Figure 3: Lesion of the lupoid CL before treatment.

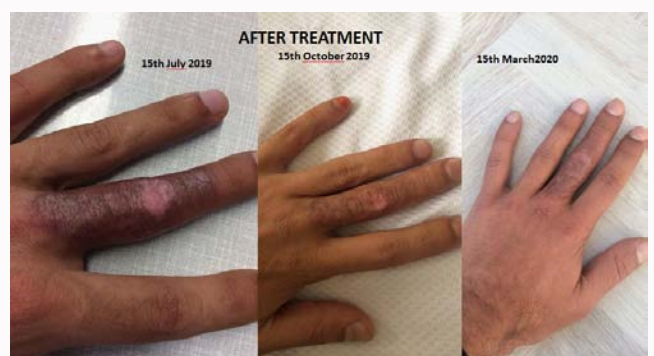

Figure 4: Lupoid CL, after treatment of the lesion with intra lesion almeoglumine antimoniate (Glucantime®).

patient was called monthly for control the healing of the lesion for one year, it was seen that the lesion was regressed (Figure 4).

The plaque ectype occurred over the finger and presented clinically as well-defined erythematous plaques that sometimes extended to involve the whole finger resembling lupus vulgaris.

Discussion

Leishmaniasis is a neglected vector-borne disease caused by protozoan parasites belonging to *Leishmania* genus and endemic in all WHO regions, including Turkey. There are 4 main clinical classifications of the leishmaniasis, visceral, post-kala-azar dermal, Cutaneous (CL) and mucocutaneous. Turkey is considered to have a high burden country for CL [4]. Although a National control program

has been established, CL is still a serious public health problem with increasing the number of CL cases due to the Syrian conflict in Turkey, particularly in Southeastern and Southern regions of the country. Sanliurfa is a hyper-endemic province of CL in Southeastern region of Turkey. Various clinical presentations of CL including papule, nodule, ulcerative, noduloul creative, and recidivans forms have been reported in Sanliurfa [5-8]. Noduloul creative form, classically known as oriental sore, is the most common form in study area.

To the best of our knowledge, lupoid CL mimicking lupus vulgaris has not been reported from Sanliurfa, Southeastern Region of Turkey. However, a few lupoid CL cases have been reported in different provinces of Turkey [9,10]. Of all CL cases the incidence of Leishmaniasis recidivans has been reported with 0.5% to 6.2% in the Middle East and Afghanistan [11]. In a recent study carried out in Tunisia, lupoid CL represented 9% of cases in adults [12]. It has been reported that in lupoid CL, the *Leishmania* amastigotes are usually absent or rare on a microbiological smear [13-15]. The paucity of *Leishmania* amastigotes in the lesion samples and in direct smears might lead to misdiagnosis with lupus vulgaris [11,13-15]. Since, it has been reported that clinically and histologically, lupoid leishmaniasis is similar to lupus vulgaris, which is considered as the most important differential diagnosis [16,17]. Contrary to other studies [13-15], we detected fortunately *Leishmania* amastigotes in direct smears of the lesion of the patient. This can be explained by the short duration of the patient's lesions (approximately 3 to 5 months) at the moment of diagnosis. We detected also *Leishmania* DNA by ITS 1 PCR and identified by Real time PCR. We found that *L. major* is responsible agent for this LCL case, which is compatible with the other studies [14,18,19]. *Leishmania tropica* is considered to be the most common, and *L. major* is the rare causative agent of lupoid CL [11,14,15,20]. In a study it has been reported species-specific PCR analysis is sensitive in cases of acute cutaneous leishmaniasis, but in lupoid leishmaniasis it is less sensitive [14].

There is no standardized treatment for this condition and thus multiple treatments have been reported with varying degrees of success. Treatment options include cryotherapy, topical antimonies compounds and intralesional pentavalent antimony. This patient was treated with intralesional meglumine antimoniate (Glucantime) injections twice a week for four weeks with marked improvement of clinical features.

Conclusion

Lupoid CL can be manifested as an uncommon form that can mimic many other skin disorders as lupus vulgaris. Hence, the physicians living in no endemic areas should never overlook that many unusual lesions might be caused by *Leishmania*. Any ignoring may be resulted in missed and delay the precise diagnosis, submitting the patients to inappropriate prescribing of drugs, increased resistance to treatment, worsening the clinical presentation, and contributing to the transmission chain of the parasite. Correct and reliable identification of parasite might contribute for breaking the chain of transmission of the parasite and decrease the prevalence. Diagnosis of CL should be performed in all patients from endemic areas of Leishmaniasis by both microscopic examination of Giemsa stained smears and PCR and identified of *Leishmania* species by using a PCR-RFLP technique.

Author Contribution

This study was primarily carried out at Harran University.

Funding acquisition: Nebiye Yentur Doni.

References

- Mlika RB, Hammami H, Sioud A, Mokhtar I, Fenniche S: Lupoid leishmaniasis of the nose responding well to cryotherapy. *Dermatol Ther.* 2011;24(3):378-9.
- Owino BO, Matoke-Muhia D, Alraey Y, Mwangi JM, Ingonga JM, Ngumbi PM, et al. Association of *Phlebotomus guggisbergi* with *Leishmania major* and *Leishmania tropica* in a complex transmission setting for cutaneous leishmaniasis in Gilgil, Nakuru county, Kenya. *PLoS Negl Trop Dis.* 2019;13(10):e0007712.
- WHO: World Health Organization. Report of a meeting of the WHO Expert Committee on the Control of Leishmaniases, Geneva. *WHO Tech Series.* 2010;(949):23-129.
- WHO: Weekly Epidemiological Record. Leishmaniasis in high-burden countries: An epidemiological update based on data reported in 2014. 2014;91(22):286-96.
- Aksoy M, Doni N, Ozkul HU, Yesilova Y, Ardic N, Yesilova A, et al. Pediatric cutaneous leishmaniasis in an endemic region in Turkey: A retrospective analysis of 8786 cases during 1998-2014. *PLoS Negl Trop Dis.* 2016;10(7):e0004835.
- Gurses G, Ozaslan M, Zeyrek FY, Kilic IH, Doni NY, Karagoz ID, et al. Molecular identification of *Leishmania* spp. isolates causes Cutaneous Leishmaniasis (CL) in Sanliurfa Province, Turkey, where CL is highly endemic. *Folia Microbiol (Praha).* 2018;63(3):353-59.
- Turan E, Ye ilova Y, Surucu HA, Ardic N, Doni N, Aksoy M, et al. A comparison of demographic and clinical characteristics of Syrian and Turkish patients with cutaneous leishmaniasis. *Am J Trop Med Hyg.* 2015;93(3):559-63.
- Yentur Doni N, Gurses G, Dikme R, Simsek Z, Muratoglu M, Yildiz Zeyrek F, et al. Investigation of cutaneous leishmaniasis by active screening in primary schools in Sanliurfa, Turkey. *Mikrobiyol Bul.* 2016;50(4):559-68.
- Cingöz K, Türel Ermertcan A, Temiz P: Cutaneous leishmaniasis mimicking lupus vulgaris. *DOD Clin Case Rep.* 2018;2:23-6.
- Ferahbas A, Mistik S, Utas S, Yaman O, Canoz O, Doganay M, et al. Cutaneous lupoid leishmaniasis: A case report. *Cutis.* 2006;77(1):25-8.
- Gurel MS, Ulukanligil M, Ozbilge H. Cutaneous leishmaniasis in Sanliurfa: Epidemiologic and clinical features of the last four years (1997-2000). *Int J Dermatol.* 2002;41(1):32-7.
- Zaraa I, Ishak F, Kort R, El Euch D, Mokni M, Chaker E, et al. Childhood and adult cutaneous leishmaniasis in Tunisia. *Int J Dermatol.* 2010;49(7):790-3.
- Masmoudi A, Boudaya S, Ayadi N, Bouassida S, Khabir A, Meziou TJ, et al. Clinical and histological study of lupoid cutaneous leishmaniasis (16 cases). *Presse Medicale.* 2007;36(12):1738-42.
- Momeni AZ. Chronic Lupoid Leishmaniasis. *Arch Dermatol.* 1996;132(2):198-202.
- Ul Bari A, Raza N. Lupoid cutaneous leishmaniasis: A report of 16 cases. *Indian J Dermatol Venereol Leprol.* 2010;76(1).
- Nilfroushudeh MA, Sadeghian G, Jaffary F, Ziaei H, Shirani-Bidabad L, Mahzoni P. Successful treatment of lupoid cutaneous leishmaniasis with glucantime and topical trichloroacetic acid (a case report). *Korean J Parasitol.* 2008;46(3):175-7.
- Herrmann A, Wohlrab J, Sudeck H, Burchard GD, Marsch WC. Chronic lupoid leishmaniasis. A rare differential diagnosis in Germany for erythematous infiltrative facial plaques. *Hautarzt.* 2007;58(3):256-60.
- Khaled A, Goucha S, Trabelsi S, Zermani R, Faza'a B. Lupoid cutaneous leishmaniasis: A case report. *Dermatol Ther (Heidelb).* 2011;1(2):36-41.

19. Sadeghian G, Ziaei H, Shirani-Bidabadi L, Nilforoushzadeh MA. Lupoid leishmaniasis due to *Leishmania* major with remaining large scars: Report of 2 cases. Eastern Mediterr Health J. 2010;16(3):344-5.
20. Narang T, Dogra S, Kanwar AJ, Radotra BD. Disfiguring ulcerated plaques - Lupoid leishmaniasis. Clin Exp Dermatol. 2008;33(6):805-07.