



# Long-Term Survival in a 66-Year-Old Female with Metastatic Pancreatic Carcinoma after Sequential Chemotherapy

Veronika Kulla\*, Fabian Kütting, Annette Froitzheim, Hans-Michael Steffen and Dirk Waldschmidt

Department of Gastroenterology and Hepatology, University Hospital of Cologne, Germany

## Abstract

Pancreatic cancer is a dreadful disease with a very limited survival rate. For the majority of patients who were representing in a locally advanced stage or with distant metastases lifetime is significantly limited only to a few months. We decided to present this case due to the remarkable general condition of our patient over two years after the initial diagnosis of metastatic pancreatic cancer. We treated her with sequential chemotherapy and a close staging monitoring.

**Keywords:** Pancreatic cancer; Pancreatic cancer with distant metastases; Sequential chemotherapy; Long survival

## Introduction

We are reporting on a 66 years old female, who presented to her general practitioner with declining physical strength, annular pain in the upper abdomen, general fatigue and unintentional weight loss totaling three kilograms within the previous five months. She had been suffering from back pain for a period of ten months. The first blood workup showed elevated liver enzymes. Subsequently, a contrast-enhanced CT scan of the abdomen was performed, showing a tumor within the pancreatic body and tail as well as multiple hepatic lesions.

The patient was referred to the oncologic division of the Clinic of Gastroenterology and Hepatology at the University Hospital of Cologne.

Abdominal ultrasound also showed a tumor in the position of the pancreas (main tumor: 43x56x22 mm; Figure 1) with impression of the splenic vein and enclosure of a long section of the hepatic artery, as well as liver metastases (reference live lesions in segment VIII: 27x35x27 mm; Figure 2) and pathological lymph nodes. In order to confirm the diagnosis of suspected malignancy, a biopsy of one of the liver lesions was performed. The histopathological analysis resulted in an adenocarcinoma of the pancreatobiliary system. Immunohistochemical staining revealed a strong expression of CA 19-9 and CK 7. CK 20 and CDX2 were not detectable.

Due to the advanced stage, we sought to perform a palliative chemotherapy. Potential first-line therapy options at this point were FOLFIRINOX or gemcitabine combined with erlotinib. Current publications deemed both alternatives more favorable than gemcitabine monotherapy [5]. In the respective trials, the overall survival was 11.1 months for FOLFIRINOX, compared with 6.8 months for gemcitabine [6], while the combination of gemcitabine and erlotinib had an overall survival of 6.2 months, compared with 5.9 months in gemcitabine monotherapy [7]. While improving survival, FOLFIRINOX comes at the price of significantly increased toxicity [5]. Furthermore, patients who develop an erlotinib-related skin rash show an improved survival [5] compared to patients without a rash.

The patient was hesitant regarding the possible side effects of FOLFIRINOX and the implantation of a port system. A first-line therapy with gemcitabine and erlotinib was initiated and generally well-tolerated. Two weeks after the first dose of erlotinib, the patient developed a grade II skin rash. Using topical steroids, this side effect was manageable. Already after the first gemcitabine application, CA 19-9 levels as well as CEA levels began to decrease (Figure 3).

The first abdominal ultrasound control after 15 weeks showed a size reduction of the liver metastases (reference liver lesion in segment VIII: 19x23x19 mm; initial size: 27x35x27 mm; Figure

## OPEN ACCESS

### \*Correspondence:

Veronika Kulla, Clinic of Gastroenterology and Hepatology, University Hospital of Cologne, Kerpener Str. 62, DE-50937 Cologne, Germany, Tel: +49 221 478 86109; Fax +49 221 478 86581; E-mail: veronika.kulla@uk-koeln.de

Received Date: 24 Sep 2016

Accepted Date: 21 Nov 2016

Published Date: 23 Nov 2016

### Citation:

Kulla V, Kütting F, Froitzheim A, Steffen H-M, Waldschmidt D. Long-Term Survival in a 66-Year-Old Female with Metastatic Pancreatic Carcinoma after Sequential Chemotherapy. *J Gastroenterol Hepatol Endosc.* 2016; 1(1): 1002.

**Copyright** © 2016 Veronika Kulla. This is an open access article distributed under the Creative Commons Attribution License, which permits unrestricted use, distribution, and reproduction in any medium, provided the original work is properly cited.

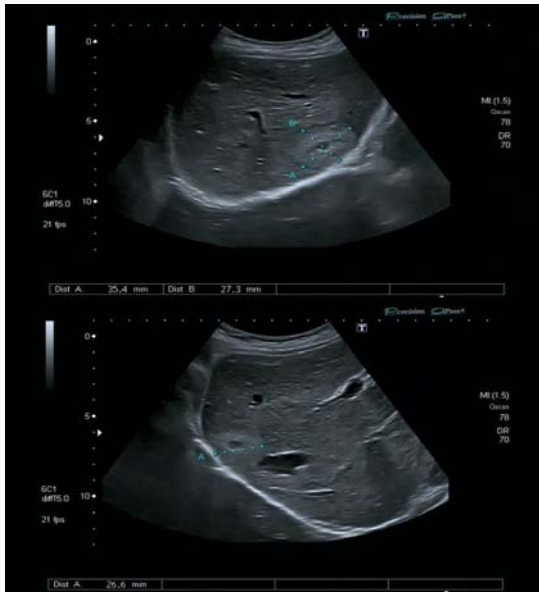

Figure 1: Initial main tumor.

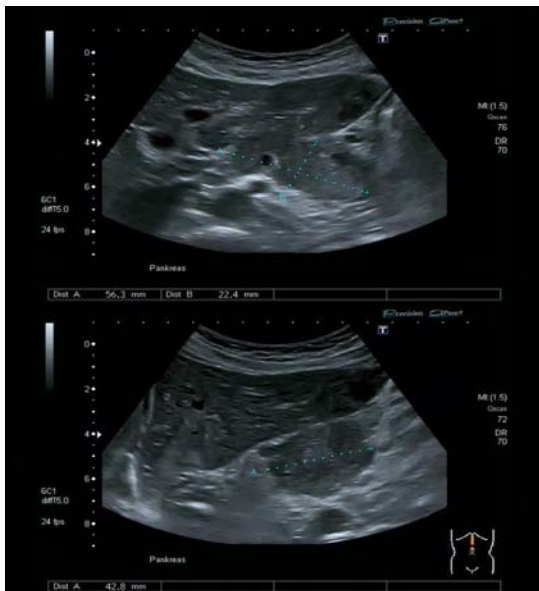

Figure 2: Initial reference liver lesion in segment VIII.

4), lymph nodes and the main tumor (main tumor: 33x27x24 mm; initial size: 43x56x22 mm; Figure 5). A longside chemotherapy, the patient began to engage in increased daily physical activity.

Six months after initiating medical treatment the tumor marker reached its lowest level (Figure 3). Ca 19-9 declined from 31,351 kU/l (10 October 2012) to 212 kU/l (23 April 2013).

Additionally, physical performance improved and her pain level was reduced. One month later, she began undertaking parts of the Way of St. James in France, resulting in a covered distance of 600 kilometers between May and July.

CA 19-9 and CEA levels slowly began to rise and the patient observed an increased need for analgesics. In contrast to the aforementioned symptoms, re-staging with contrast-enhanced CT and abdominal ultrasound revealed a size reduction of the main

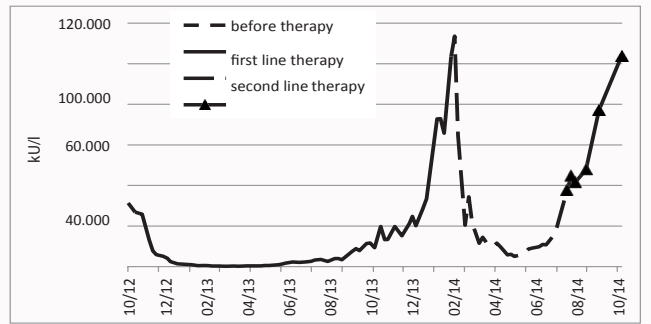


Figure 3: plasma levels of Ca19-9 during therapy.

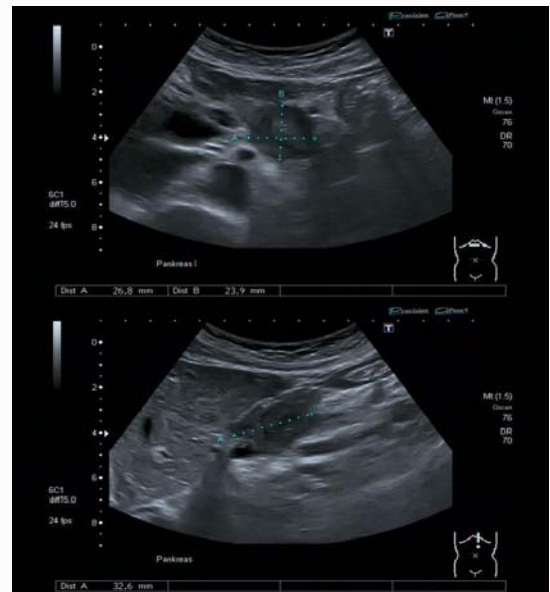


Figure 4: Reference liver lesion in segment VIII 15 weeks after first-line therapy.

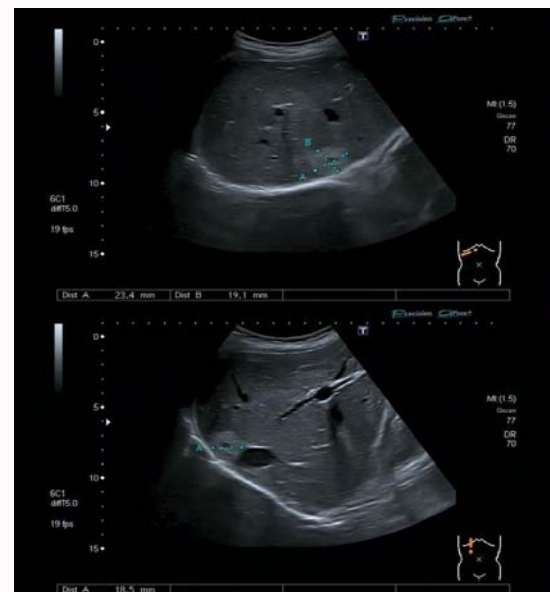


Figure 5: Main tumor 15 weeks after first-line therapy.

tumor, the lymph nodes and the liver metastases, one year after the initiation of the chemotherapy.

In the following months, the tumor marker continuously rose and the patient's general condition further declined. The intervals of sonographic control examinations were reduced to two months without evidence of tumor growth in the subsequent staging examinations.

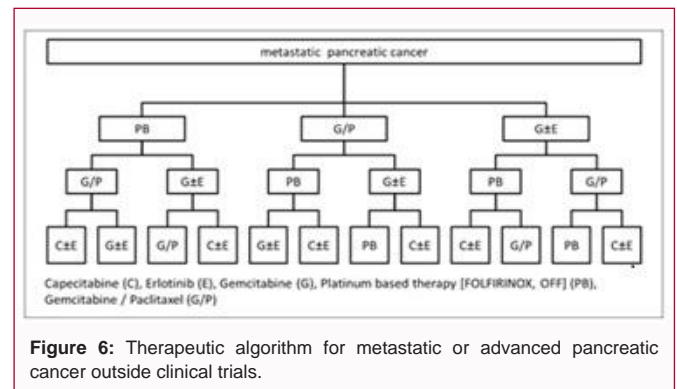
Twenty-one months after the initiation of gemcitabine/erlotinib, tumor progression became visible on abdominal ultrasound, indicated by a growth of the main tumor (main tumor: 37x36x30 mm; previous size: 33x27x24 mm) as well as the multiple liver lesions (reference liver lesion in segment VIII: 40x43x32 mm; previous size: 19x23x19 mm). In the meantime Ca 19-9 and CEA levels reached a temporary peak (Figure 3).

The possible treatment options for second-line therapy at this point were FOLFIRINOX or gemcitabine in combination with nab-paclitaxel, given that the patient was still in good overall health. Since the initiation of our palliative therapy, a combination of gemcitabine and nab-paclitaxel had proven advantageous compared to gemcitabine alone (overall-survival 8.5 months in nab-paclitaxel-gemcitabine group, 6.7 months in the gemcitabine group [8]). Nab-paclitaxel with gemcitabine tends to produce fewer side effects when compared to platinum-based regimens [8]. This combination was approved for clinical application as first line treatment of advanced pancreatic carcinoma in early 2014.

Hence, the patient was switched to gemcitabine/nab-paclitaxel which was well tolerated. This second-line therapy led to a decrease in CA 19-9 and CEA levels (Figure 3), and her symptoms showed a marked improvement. The patient was able to continue her daily workout and participated in a pancreatic cancer sports group. After five months Ca 19-9 slowly began to increase again. Eight months after the initiation of the second line therapy with gemcitabine/nab-paclitaxel, a second tumor progression was noticed. Platinum-based regimens or an oral treatment with capecitabine represent possible options for a third line therapy. In our case, we opted for capecitabine in combination with a re-exposure to erlotinib. One of the main reasons for this treatment was the fact that the patient feared the possible side effects of Platinum based regimens and the implantation of a port system. Three weeks after the beginning of re-exposure to erlotinib a skin rash grade I-II was visible, other side effects were low and the patient was in good general condition. Four months after the start of the third-line therapy a tumor progression was detected. The general condition declined rapidly, ascites appeared and the need of analgetics rose. Finally, the patient died thirty-three months after the initial diagnosis of a metastatic pancreatic cancer.

## Discussion

We decided to present this case due to the remarkable general condition of our patient over 2 years after the initial diagnosis of metastatic pancreatic cancer. Compared to median survival of three to six months for patients with metastatic disease [3], the case presented here gives reason for hope in the treatment of this dreadful disease. One reason for the currently good clinical condition of our patient is a repeated favourable tumor response to chemotherapy. A further reason is the absence of tumor cachexia in this case. Pancreatic cancer patients have the highest prevalence of tumor cachexia [9-11] totaling up to 70% to 80% of those afflicted [11]. This syndrome accounts for up to 80% of deaths in patients with advanced disease [12]. Moreover, tumor cachexia is associated with reduced survival [11], poor treatment response [10] and limited physical activity, [3]



which in turn further reduce the quality of life.

Prior to the initial diagnosis, our patient lost three kilograms, however, she was able to maintain her weight during therapy. Moreover, her favorable clinical condition can be attributed to her regular physical training which supports the conservation of muscles and counteracts tumor cachexia. Hence, cancer patients should be motivated to participate in sports groups and daily physical activity to prevent or ameliorate cachexia.

Furthermore, it should be kept in mind that frequent imaging, e.g. by abdominal ultrasound, can help to identify the right time for a therapy modification in patients that are eligible for treatment beyond first line therapy. Due to the fact that there are now several chemotherapy regimens at our disposition, utilizing the right agent at the right moment is becoming crucial. Because second line therapy is mainly based on individual treatment experience, controlled trials are needed to evaluate second and third line therapeutic options in metastatic and advanced pancreatic cancer.

During the preparation of this case report observations from a cohort study with 57 patients have been presented at the annual American Society of Clinical Oncology (ASCO) meeting in 2015 by A. Portal et al. [13]. The abstract details a median overall survival of 18 months using FOLFIRINOX and gemcitabine/nab-Paclitaxel sequentially. Following a model of sequential chemotherapy for colorectal cancer by Schmoll et al. [14], we propose a similar therapeutic therapy algorithm as presented in Figure 6.

## Disclosure Statement

V.K.: honoraria for travel grants from Celgene; F.K.: honoraria for travel grants from Celgene and Novartis; D.W.: honoraria for travel grants, accommodations and expenses from Celgene, Roche and Bayer.

## References

- Malvezzi M, Bertuccio P, Levi F, La Vecchia C, Negri E. European cancer mortality predictions for the year 2013. *Ann Oncol.* 2013; 24: 792-800.
- Vincent A, Herman J, Schulick R, Hruban RH, Goggins M. Pancreatic cancer. *Lancet.* 2011; 378: 607-620.
- Ronga I, Gallucci F, Riccardi F, Uomo G. Anorexia-cachexia syndrome in pancreatic cancer: Recent advances and new pharmacological approach. *Adv Med Sci.* 2014; 59: 1-6.
- Burris HA, Moore MJ, Andersen J, Green MR, Rothenberg ML, Modiano MR, et al. Improvements in survival and clinical benefit with gemcitabine as first-line therapy for patients with advanced pancreas cancer: a randomized trial. *J Clin Oncol.* 1997; 15: 2403-2413.

5. Vaccaro V, Bria E, Sperduti I, Gelibter A, Moscetti L, Mansueto G, et al. First-line erlotinib and fixed dose-rate gemcitabine for advanced pancreatic cancer. *World J Gastroenterol.* 2013; 19: 4511–4519.
6. Conroy T, Desseigne F, Ychou M, Bouché O, Guimbaud R, Bécouarn Y, et al. FOLFIRINOX versus gemcitabine for metastatic pancreatic cancer. *N Engl J Med.* 2011; 364: 1817–1825.
7. Moore MJ, Goldstein D, Hamm J, Figer A, Hecht JR, Gallinger S, et al. Erlotinib plus gemcitabine compared with gemcitabine alone in patients with advanced pancreatic cancer: a phase III trial of the National Cancer Institute of Canada Clinical Trials Group. *J Clin Oncol.* 2007; 25: 1960–1966.
8. Von Hoff DD, Ervin T, Arena FP, Chiorean EG, Infante J, Moore M, et al. Increased Survival in Pancreatic Cancer with nab-Paclitaxel plus Gemcitabine. *N Engl J Med.* 2013; 369: 1691–1703.
9. Fearon KC, Baracos VE. Cachexia in pancreatic cancer: new treatment options and measures of success. *HPB (Oxford).* 2010; 12: 323–324.
10. Di Sebastiano KM, Yang L, Zbuk K, Wong RK, Chow T, Koff D, et al. Accelerated muscle and adipose tissue loss may predict survival in pancreatic cancer patients: the relationship with diabetes and anaemia. *Br J Nutr.* 2013; 109: 302–312.
11. Mueller TC, Burmeister MA, Bachmann J, Martignoni ME. Cachexia and pancreatic cancer: Are there treatment options? *World J Gastroenterol.* 2014; 20: 9361–9373.
12. Bachmann J, Heiligensetzer M, Krakowski-Roosen H, Büchler MW, Friess H, Martignoni ME. Cachexia worsens prognosis in patients with resectable pancreatic cancer. *J Gastrointest Surg.* 2008; 12: 1193–1201.
13. Portal A, Pernet S, Arbaud C, Tougeron D, Thiot-Bidault A, De La Fouchardiere C, et al. Nab paclitaxel plus gemcitabine for metastatic pancreatic adenocarcinoma after failure of folfirinnox: Results of an AGEO multicenter prospective cohort. *Br J Cancer.* 2015; 113: 989-995.
14. Schmoll H J, Van Cutsem E, Stein A, Valentini V, Glimelius B, Haustermans K, et al. ESMO Consensus Guidelines for management of patients with colon and rectal cancer. A personalized approach to clinical decision making. *Ann Oncol.* 2012; 23: 2479-2516.