



## Lipoplasty and Lipolysis: Negative Outcomes and Medicolegal Consequences

Michel Costagliola<sup>1\*</sup>, Bishara Atiyeh<sup>2</sup>, Florence Rampillon<sup>3</sup> and Benoit Chaput<sup>4</sup>

<sup>1</sup>Plastic, Reconstructive and Aesthetic Surgery, Toulouse University, Toulouse, France

<sup>2</sup>American University of Beirut Medical Center, Beirut, Lebanon

<sup>3</sup>Clinique du Parc, 33 rue des Bûchers, Toulouse, France

<sup>4</sup>Plastic and Reconstructive Surgery, Toulouse-Rangueil University Hospital, France

### Abstract

Liposuction (blunt suction lipectomy) is now a well-established technique which generally yields gratifying aesthetic results. Since it was first described in 1977 by Illouz, changes or improvements to the technique of liposuction have been introduced regarding instruments (cannulas, pumps, syringes, and various devices), depth of suctioning (deep or superficial), volume of fluid infiltration (wet, superwet, tumescent) and osmolarity (isotonic, more or less hypotonic). Many other changes or “innovations” have also been described that needs to be denounced. We report several complications resulting in severe skin necrosis following liposuction and lipolysis methods of questionable scientific merit: ultrasonic liposuction, infiltration of hypo-osmolar solution, lipolysis without aspiration, or, unfortunately, after accidental infiltration of hypertonic saline solution. The ensuing skin necrosis required surgical debridement followed by prolonged secondary wound healing, resulting in severe aesthetic and functional sequelae and the inevitable legal malpractice implications. It is essential that plastic surgeons be careful about using techniques widely advertised by the media but not yet scientifically validated. Basic precautionary principles must be respected (light hypo-osmolar infiltration about 200 mOsm is safe). Surgeons should not be dispensed from applying rigorous monitoring and strict safety measures in the operating room (check-list, traceability, qualification of nursing staff, etc.).

### OPEN ACCESS

#### \*Correspondence:

Michel Costagliola, Emeritus Professor of Plastic, Reconstructive and Aesthetic Surgery, Toulouse University, 3 rue du Languedoc, 31000 Toulouse, France, Tel: 0609722636;

E-mail: costagliola.m@wanadoo.fr

Received Date: 01 Apr 2017

Accepted Date: 13 Jun 2017

Published Date: 20 Jun 2017

#### Citation:

Costagliola M, Atiyeh B, Rampillon F, Chaput B. Lipoplasty and Lipolysis: Negative Outcomes and Medicolegal Consequences. *Ann Plast Reconstr Surg.* 2017; 1(1): 1003.

Copyright © 2017 Michel Costagliola.

This is an open access article distributed under the Creative Commons Attribution License, which permits unrestricted use, distribution, and reproduction in any medium, provided the original work is properly cited.

### Introduction

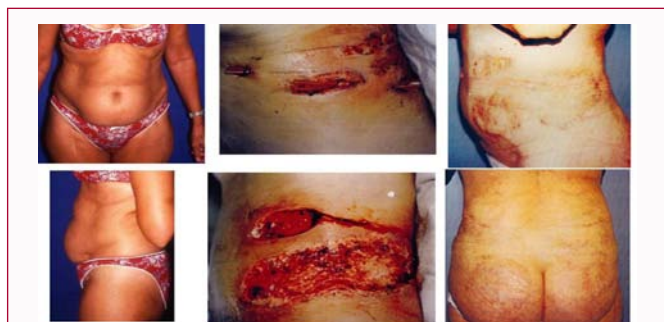Liposuction is a surgical procedure intended to remove fat deposits and shape the body. It is not trivial surgery, not always benign [1,2], nor is it entirely safe as claimed by glossy brochures. Nevertheless, since first described by Illouz in 1977 [3,4], liposuction has developed to become the most-performed plastic surgery procedure worldwide. The basic original technique has undergone numerous modifications and refinements regarding equipment (cannulas, infiltration pumps, aspiration syringes and machines), level of lipo-aspiration (deep or superficial), nature of the infiltration solution and the volume injected. A non-negligible incidence of complications, namely severe skin necrosis, has been reported following more or less scientifically validated liposuction procedures. Similar complications have also been reported after inadvertent infiltration with hypertonic solutions. Alternatively, numerous non-surgical lipolysis modalities have been proposed. Infiltration of hypo-osmolar solution without aspiration has not only proved ineffective, but it has resulted in severe complications such as infection and scarring. As new technologies are continually being described and introduced, the enthusiasm that they arouse must be tempered and only procedures with a solid scientific basis and proven efficacy must be performed [5].

This report, while it is not an inclusive review, is intended to highlight several serious side-effects of these procedures that we have observed in our role as medical experts in medico legal cases. Liposuction is now well codified and generally yields gratifying results. Simple precautionary principles must be respected to avoid these harmful effects. We consider that light hypo-osmolar infiltration followed by aspiration is the technique of choice, safe and effective. We describe this procedure at the end of our paper.

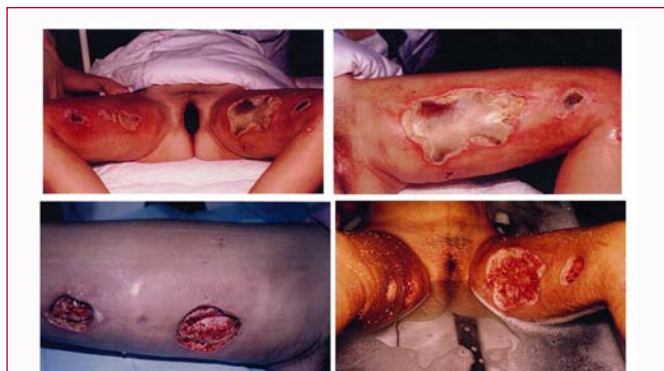### Cases

#### Ultrasound liposuction

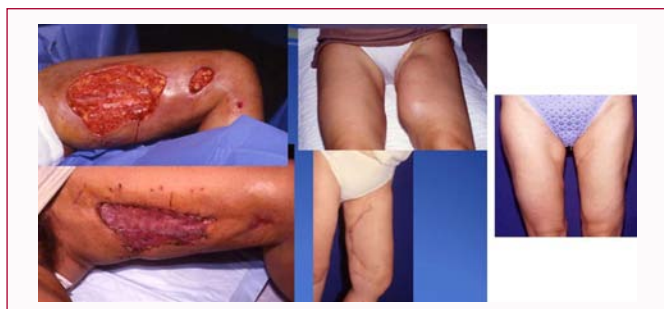
Ultrasound liposuction, also called ultrasonic assisted liposuction, or UAL for short, is one of the



**Figure 1:** Mrs C (44-y-old) pizzeria maid ultra-sonic liposuction under local anesthesia (3.5 h) burns right flank left flank j 7.



**Figure 2a:** 2 sessions of ultrasonic liposuction (36-year-old) deep burn.

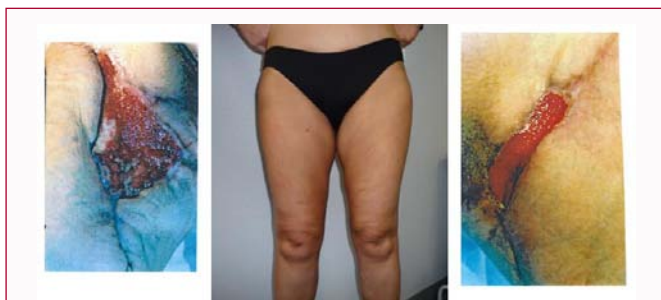


**Figure 2b:** Result after excision and graft skin expansion and scar result.

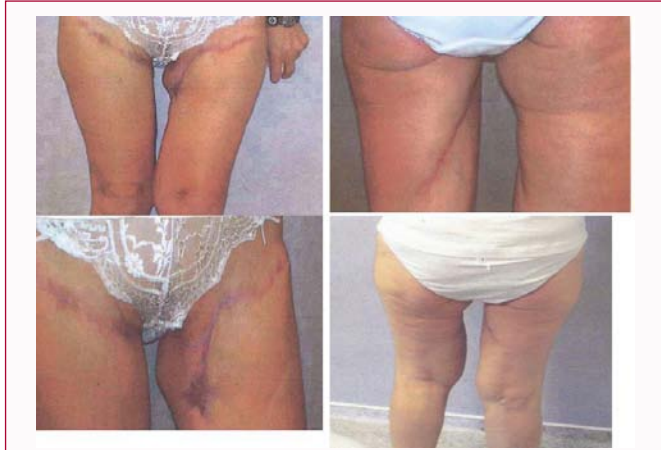latest developments in the field. Liposuction with focused ultrasound energy cannulas has many supporters in Europe (Zocchi in Italy) [6] and South America. However, it also has numerous opponents because its safety is still questionable. Fat is removed from under the skin using a vacuum-suction cannula or an ultrasonic probe that emulsifies the fat and then removes it with suction.

**Case 1:** A 44-year-old woman, an employee in a pizzeria, underwent ultrasound liposuction of the abdomen under local anesthesia by a general practitioner. The procedure duration was 3.5 h. On examination, a deep burn with extensive skin necrosis was observed on the left flank (Figure 1). The physician tried to justify this complication, though to no avail, by claiming that since the patient returned to work the following day, she was exposed to oven heat too soon after the procedure. Wound healing was not completed until 5 months and scarring was extensive.

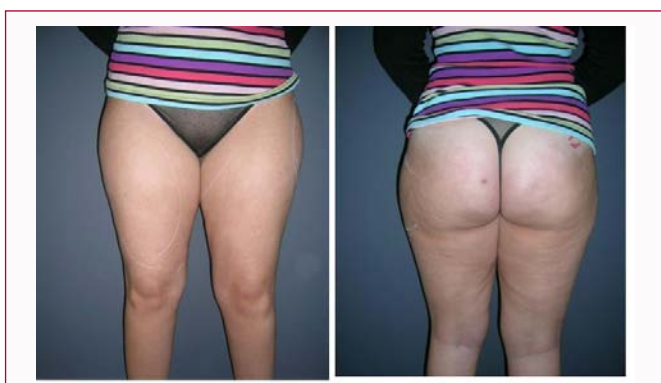**Case 2:** A 36-year-old woman underwent ultrasound liposuction by a general practitioner, resulting in serious burns of the inner thighs (Figure 2). Six months of conservative therapy were required for healing of the right thigh. The left thigh required a split-thickness



**Figure 3:** First case of skin necrosis after traditional liposuction.



**Figure 4:** Mrs D 7 months post op.



**Figure 5:** Second case Miss Sb (24-years-old) Dr. L in Oct 2010 liposuction only 3 weeks after the previous patient.

skin graft that was later excised following tissue expansion and scar revision with flaps. Nevertheless, the patient had marked scar sequelae on the medial aspect of the left thigh and lesser scarring on the right thigh (Figure 2a) [7].

In both cases, expert legal opinion confirmed the total responsibility of the two physicians.

**Liposuction following mistaken injection of hyperosmolar solution**

**Case 1:** A 44-year-old woman with medial upper thigh lipodystrophy underwent medial thigh lift with associated liposuction by a plastic surgeon. Within a few days, skin necrosis developed, more on the right side than the left, with obvious scars (Figure 3 and 4) [8].

**Case 2:** One month after the above case, a 24-year-old woman (Figure 5), was operated (liposuction only) by another well-

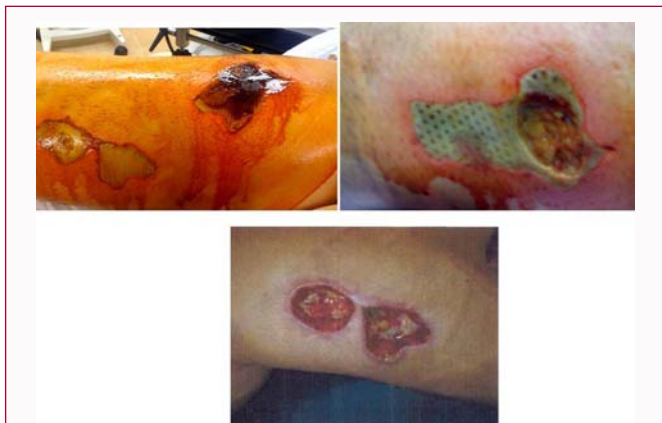

Figure 6: Second case right side.

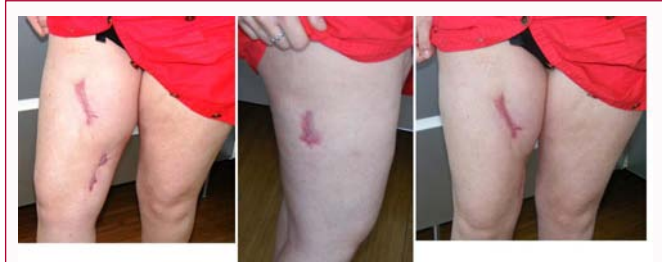

Figure 7: Second case sequelae: 7 months later.

experienced plastic surgeon in the same clinic and the same operating theater. Similarly, this patient rapidly developed skin necrosis over the right medial thigh (Figure 6) that slowly healed leaving serious scar sequelae 7 months later (Figure 7).

The occurrence of skin necrosis in two successive patients one month apart, operated by two different surgeons but in the same clinic and operating theater and with the same nurse, was highly suspicious. It was then found that the fluid used for infiltration had in fact been a 30% hyperosmolar solution usually used for treatment of hydatid cysts. Unfortunately, the iso-osmolar and hyperosmolar containers were placed on the same shelf in the pharmacy (Figure 8). The same temporary replacement nurse had prepared the infiltration solution in both cases. Apparently, hyperosmolar saline solution had been inadvertently injected.

In the second patient, skin necrosis was more pronounced on the left side, probably because liposuction was first performed on the right side, so earlier aspiration of infiltration solution on this side reduced its harmful effect. Expert legal opinion attributed blame to the nurse. The judge considered that the head of the treating team, namely the surgeon, had to instruct each member of the team about his or her duties. However, it was not possible for him to check the prepared solution and to be aware of its final composition before injection. This was an important legal consideration to declare that the surgeon was not guilty of negligence and that he did not commit any surgical error. The clinic, as employer of the temporary nurse, was held responsible. However, this ruling should not dispense the surgeon from pre-operative checking of all material used [9-11].

**Case 3:** It has previously been published in *Aesthetic Plastic Surgery* and is reported with the author's permission (D. Casanova, Marseille) [12]. The figures illustrate the result following inadvertent subcutaneous injection of hyperosmolar solution before aspiration.



Figure 8: Use of a 30% hypertonic solution and inadvertent subcutaneous injection of hypertonic saline solution.

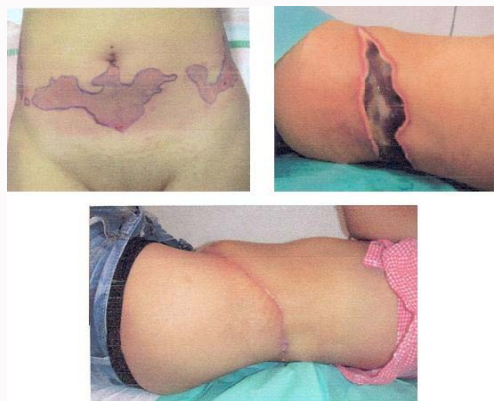

Figure 9: Inadvertent subcutaneous injection of hypertonic saline solution before liposuction for fat harvesting [12].

Necrotic tissues had to be subsequently excised (Figure 9).

**Lipolysis and lipotomie**

- Many lipolysis procedures are widely advertised in magazines for women. They promote non-surgical incisions, resulting in a dream body shape and a sublime silhouette. These are “lunch-time procedures” utilizing the latest technologies such as laser (thermal laser technologies: Lipo Laser, Micro Lipolaser, UltraPulse fractional laser) or ultrasound (focused external ultrasound or Ultrashape, external application of high-intensity focused ultrasound (HIFU) (Liposonix)) for body sculpting, and non-surgical ultrasound lipoplasty (Fodor) or cryolipolysis (selective cryolipolysis with controlled cooling of subcutaneous fat), infrared light, or lastly radiofrequency (BodyTite bipolar radiofrequency). All these non-surgical techniques aiming at localized adipolysis have never been validated scientifically. However, they have unfortunately been mentioned in official plastic surgery journals, reporting conflicting and poorly verifiable results.

- **Injection lipolysis:** These various procedures (injection of Lipodissolve, Lipostabil, or phosphatidylcholine) have many documented side-effects (pain and hyperpigmentation) and are not authorized in France [13].



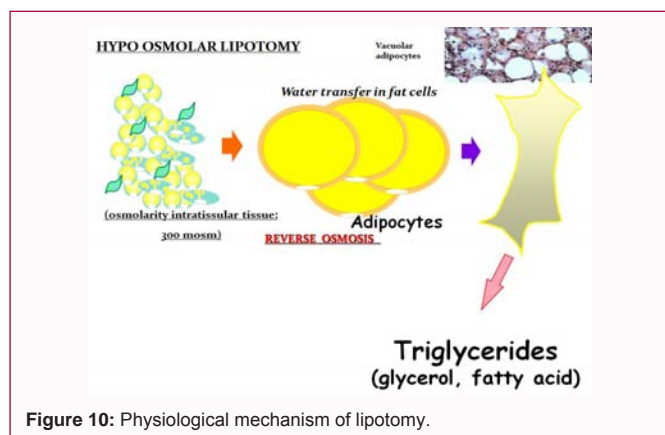


Figure 10: Physiological mechanism of lipotomy.

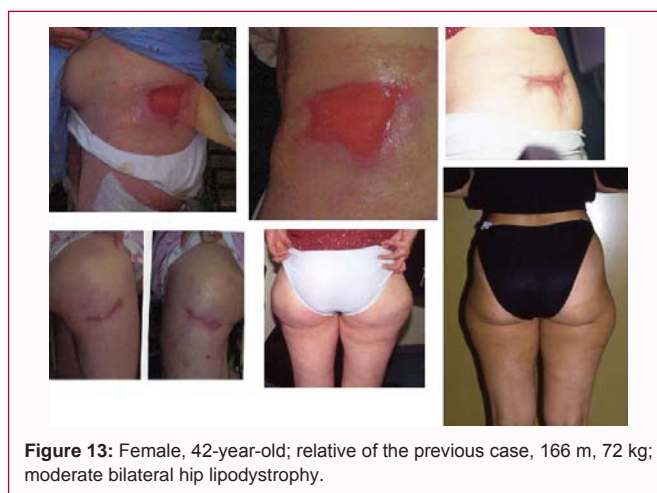

Figure 13: Female, 42-year-old; relative of the previous case, 166 m, 72 kg; moderate bilateral hip lipodystrophy.

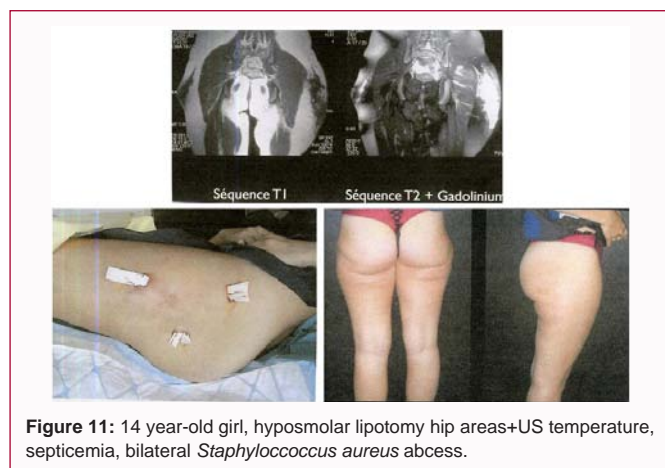


Figure 11: 14 year-old girl, hyposmolar lipotomy hip areas+US temperature, septicemia, bilateral *Staphylococcus aureus* abscess.

Table 1: Different names of lipotomy.

Hypo-osmolar mesodilution	Mesolipolysis
Lipotomy	Hydroliptomy
Hydrolipectomy	Lipodilution
Cellulysis	Osmolipolysis
Liporeduction	Lipostabilisation
Adipotomy	Adipocytolysis
Lipodissolution	Osmolipolysis

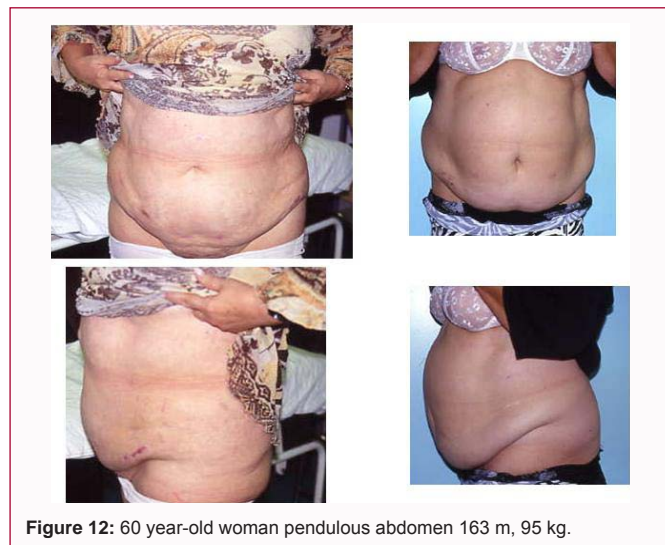

Figure 12: 60 year-old woman pendulous abdomen 163 m, 95 kg.

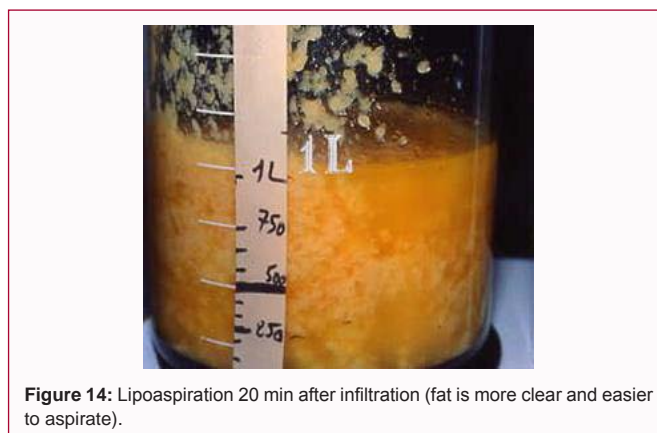


Figure 14: Lipoaspiration 20 min after infiltration (fat is more clear and easier to aspirate).

- **Lipotomy (hypo-osmolar lipotomy):** Adipocytolysis is presented by the authors as an alternative to liposuction, utilizing the physiological mechanism of osmosis.

What is osmosis? From the Greek osmos means pushing, it is a diffusion process (physiological fact). When two solutions with different concentrations are separated by a partially permeable membrane, there is a transfer from the hypotonic towards the hypertonic solution through this membrane (transfer of water only, but not dissolved substances).

**Principle and physical mechanism of lipotomy:** Normal

osmolar (isotonia) is about 300 mOsm. With a hypo-osmolar solution (90/150 mOsm), water is transferred into fat cells, and intra-membrane pressure increases (reverse osmosis). Swelling and cellular explosion with release of interstitial triglyceride residues (glycerol and fatty acids) is absorbed by lymph or eliminated in the urine (Figure 10). This theory is very controversial and the authors insist on associated measures such as musculation, sporting activities, or external ultrasound to eliminate free fatty acids. No fat aspiration is performed [14,15]. Lipotomy procedures may be known under different names (Table 1). These procedures are frequently followed by superficial burns, abscesses, oily collections, necrosis and severely impaired healing. We have published with L. Lantieri (Paris) many cases of complications:

- A clinical case of a young 14-year-old girl. The postoperative course was marked by a polymicrobial subcutaneous abscess that required two surgical evacuations. The aesthetic result was very poor (Figure 11) [16].



Figure 15: Post-operative period after light hypo osmolar technic.

- Two other cases had medicolegal implications. Firstly, a 60-year-old woman, 1.63 m and 95 kg after abdominal hypo-osmolar lipotomy, who had a very poor result after delayed healing (Figure 12). Secondly, a relative of the preceding patient aged 41, 1.60 m, 72 kg, who had bilateral hip lipodystrophy and was treated using the same technique. The post-operative course was marked by fever, abscess and necrosis. The result at five months and one year showed worsening of the lipodystrophy (Figure 13).

Lipolysis by hypo-osmolar lipotomy without liposuction is a non-invasive technique invented for medical practitioners. There have been no reliable scientific publications demonstrating its tolerance and effectiveness. Poor results and a risk of serious complications have been reported. This technique has not been validated in France.

#### Merits of light hypo-osmolar liposuction

Hypo-osmolar lipotomy (adipocytolysis without aspiration), whose harmful effects have been described, should not be confused with hypo-osmolar liposuction. In the latter, before aspiration a light hypotonic solution (200 mOsm to 220 mOsm) is infiltrated, so aspiration of burst adipocytes and liquefied fat is easier.

##### Some examples of hypotonic solutions:

- Saline 1,000 cc + distilled water 200 cc = 230 mOsm
- Saline 1,000 cc + distilled water 300 cc = 200 mOsm
- Saline 1,000 cc + distilled water 1,000 cc = 150 mOsm

##### Other authors' wetting solutions:

- The majority use isotonic solutions (Fournier, Klein, Mang, Cook, Asken, Hetter, Hunstadt, Avelar, Rebello, Georgiade).

- A minority use hypotonic solutions: light hypotonia, 230 mOsm (Illouz).

- Strong hypotonic solutions are used by Zocchi: 150 mOsm.

- Extreme hypotonic solutions: 90/150 mOsm as used by medical practitioners is very dangerous, because there is no aspiration, only biological reabsorption

##### Our wetting solution:

- Saline 1,000 cc + distilled water 300 cc + lidocaine and epinephrine, light hypo-osmolarity = 200 mOsm.

Our experience is based on more than 200 patients. Liposuction begins 20 min after infiltration. The solution is at room temperature, fat is clearer (Figure 14) and easier to aspirate. A medium quantity of fat is removed (3 L or 4 L) (Figure 15). Skin retraction is better, the patient returns to activity earlier, and we observe better results after one month.

The concept of hypo-osmolarity should not be rejected. Many plastic surgeons, adding water to their solution, are unknowingly using a hypo-osmolar procedure. Liposuction after moderate hypo-osmolar infiltration (about 200 mOsm) is a safe and efficient technique.

### Conclusions

- Care is required if using techniques that have not yet been validated, but advertised by the media.
- Simple precautionary principles must be respected (light hypo-osmolar solution followed by aspiration is safe).
- Rigorous monitoring and safety measures must be applied in the operating room (check-list, traceability, and qualified nursing staff).
- The medicolegal aspect must not be neglected and good insurance is a requisite.

### Note

The material in this paper is based on our chapter entitled 'Harmful Effects of Liposuction and Lipolysis Procedures, Questionable Safety and Scientific Validity: A Medico-Legal Perspective and Advantages of "Light" Hypo-Osmolar Liposuction' [18].

### References

1. Mole B. Liposuction and extensive cutaneous necrosis. Apropos of a clinical case. *Ann Chir Plast Esthet.* 1994;39(2):251-4.
2. Gibbons MD, Lim RB, Carter PL. Necrotizing fasciitis after tumescent liposuction. *Ann Surg* 1998;64(5):458-60.
3. Illouz YG. Surgical remodelling of the silhouette by aspiration lipolysis or selective lipectomy. *Aesthetic Plast Surg* 1985;9(1):7-21.
4. Illouz YG. Liposculpture and Silhouette Surgery. In: *EMC Surgical Techniques: Reconstructive and Aesthetic Plastic Surgery.* Paris: Elsevier Masson; 2008.
5. Stephan PJ, Kenkel JM. Updates and advances in liposuction. *Aesthet Surg J.* 2010;30(1):83-97.
6. Zocchi ML. Basic physics for ultrasound-assisted lipoplasty. *Clin Plast Surg.* 1999;26(2):209-20.
7. Grolleau JL, Rougé D, Chavoïn JP, Costagliola M. Severe cutaneous necrosis after ultrasound lipolysis. Medicolegal aspects and review. *Ann Chir Plast Esthet* 1997;42(1):31-6.
8. Chaput B, Fade G, André A, Grolleau JL, Garrido I. Liposuction: an exceptional case of skin necrosis secondary to an error of infiltration. *Plast Reconstr Surg.* 2012;129(4):765e-6e.
9. Campbell B, Callum K, Peacock NA. *Operating within the law. A practical guide for surgeons and lawyers.* London: Trinity Press; 2011.
10. Rougé D, Escat J, Costagliola M. *Medical liability: From surgery to aesthetics.* Paris: Arnette; 1992.
11. Costagliola M, Chaput B. What are the limits of the surgeon's responsibility in the operating theater? *Aesthetic Plast Surg.* 2014;38(4):830-1.
12. Kerfant N, Philandrianos C, Alliez A, Casanova D. Inadvertent

- subcutaneous injection of hypertonic saline solution during lipofilling. *Aesthetic Plast Surg* 2013;37(4):709-10.
13. <https://www.legifrance.gouv.fr/eli/decret/2011/4/11/2011-382/jo/texte>.
14. de Santé HA. Prohibition of adipocyte lysis techniques\* (Lipolysis) for aesthetic purpose.
15. Hoefflin SM. Lipoplasty with hypotonic pharmacologic lipo-dissolution. *Aesthet Surg J*. 2002;22(6):573-6.
16. Song AY, Bennett JM, Marra KG, Cimino WW, Rubin JP. Scientific basis for the use of hypotonic solutions with ultrasonic liposuction. *Aesthetic Plast Surg*. 2006; 30(2):233-8.
17. Benjoar MD, Lepage C, Hivelin M, Lantieri L. Complications of injections of hypoosmotic solutes in an underage patient. *Ann Chir Plast Esthet*. 2009;54(2):161-4.
18. Costagliola M, Atiyeh B, Rampillon F, Chaput B. Harmful effects of liposuction and lipolysis procedures, questionable safety and scientific validity: A medico-legal perspective and advantages of "Light" hypo-osmolar liposuction. In: Shiffman MA, di Giuseppe A, editors. *Liposuction: Principles and practice*. 2nd ed. Berlin: Springer-Verlag, Germany; 2016. pp. 833-47.