



Intraoperative Clinical Findings vs Completion Angiography during Thromboembolectomy for Acute Lower Limb Ischemia: Analysis of Outcomes

Francesco Zaraca^{1*}, Andrea Ponzoni², Carlo Stringari¹, Juliane A Ebner¹ and Heinrich Ebner¹

¹Department of Vascular and Thoracic Surgery, Regional Hospital Bozen, Italy

²Department of ICT, Institute Zooprofilattico Sperimentale delle Venezie, Italy

Abstract

Aim: Completion angiography is useful after thromboembolectomy for lower limb ischemia. In this study the authors prospectively assessed the vascular surgeon's accuracy in predicting the need for intraoperative angiography.

Methods: Details of patients with acute lower limb ischemia due to native vessel occlusion were prospectively recorded over a 4-year period in a central hospital vascular unit setting. The patients were prospectively randomised to perform either intraoperative angiography (group A) or not (group B). Eligible patients for randomisation had to meet the 3 predefined criteria to be enrolled: a good capillary refilling, at least one palpable arterial pulse of foot and a good foot skin hyperaemia after revascularization. The upper normal limit for capillary refill was considered 3 seconds. When the clinical appearance of the foot did not meet the predefined criteria the patients were not randomised and on-table angiography was directly performed (group C).

In order to calculate the positive and negative predictive values and sensitivity of intraoperative clinical findings in detecting residual clots, we compared groups A and C. In order to determine reliability of the intraoperative clinical factors in predicting outcome, results of the randomised groups (A and B) were analysed in terms of reocclusion, amputation and mortality at 24 months.

Results: A total of 102 consecutive patients underwent 110 lower limb thromboembolectomies for acute ischemia. 75 procedures were randomised in the present study: 36 were randomised to the intraoperative angiography group (group A) and 39 to no intraoperative angiography group (group B). 35 procedures were not randomised (group C). The positive and negative predictive values and sensitivity of the 3 intraoperative criteria were respectively 26%, 83% and 60%. In group a extension of the procedure, based on data acquired from the on table angiography, was necessary in 16.7% of patients (6/36). At 24 months after surgery, group A resulted in a lower incidence of reocclusion (8.3%) in comparison with group B (28.2%) ($p=0.02$), whereas there was no statistical difference between the 2 groups in terms of amputation (6.7% vs. 10.7%; $p=0.60$) nor of mortality (53.3% vs. 55.7%; $p=0.84$).

Conclusions: Intraoperative clinical findings are not reliable in predicting postoperative outcome during surgery for acute lower limb ischemia. The positive and negative predictive values and sensitivity of these intraoperative criteria compared to angiography are poor.

Routine use of intraoperative angiography after embolectomy for lower limb acute arterial occlusion, compared to selective use, results in a lower reocclusion rate at 24 months ($p=0.02$).

Keywords: Completion Angiogram; Acute Lower Limb Ischemia; Thromboembolectomy

Introduction

Intraoperative angiography is a rapid and reliable method for evaluation of the immediate results after thromboembolectomy with the Fogarty balloon catheter [1,2].

Many authors advocate intraoperative angiography as the most reliable method of ensuring that complete clearance of the whole arterial tree has been achieved [3,4,5]. Back bleeding is considered an unreliable guide to distal patency [5,6]. Information gained through an intraoperative study can lead to modifications at the time of initial operation that may prevent complications and obviate

OPEN ACCESS

*Correspondence:

Francesco Zaraca, Department of Vascular and Thoracic Surgery, Regional Hospital Bozen, L. Böhler Street no. 5, 39100, Italy, Tel: 0039 0471 909700; Fax: 0039 0471 909718; E-mail: francesco.zaraca@sabes.it

Received Date: 22 Nov 2017

Accepted Date: 06 Feb 2018

Published Date: 13 Feb 2018

Citation:

Zaraca F, Ponzoni A, Stringari C, Ebner JA, Ebner H. Intraoperative Clinical Findings vs Completion Angiography during Thromboembolectomy for Acute Lower Limb Ischemia: Analysis of Outcomes. *Ann Vasc Med.* 2018; 1(1): 1003.

Copyright © 2018 Francesco Zaraca. This is an open access article distributed under the Creative Commons Attribution License, which permits unrestricted use, distribution, and reproduction in any medium, provided the original work is properly cited.

Table 1: Patient demographics (102 patients).

	Group A (n = 35)	Group B (n = 37)	Group C (n = 30)	p
Age (mean, range)	82.6 (44-96)	79.3 (40-100)	77.3 (35-91)	0.68
Gender (M/F)	8/27	17/20	19/11	0.12
Hypertension	30 (85.7)	27 (73.0)	23 (76.7)	0.41
Clinical category				0.66
I	0	0	0	
IIA	22 (63)	20 (54)	18 (60)	
IIB	13 (37)	17 (46)	12 (40)	
III	0	0	0	
Atrial fibrillation	28 (80.0)	24 (64.9)	22 (73.3)	0.35
Diabetes	14 (40.0)	7 (18.9)	10 (33.3)	0.14
Hyperlipidaemie	12 (34.3)	9 (24.3)	9 (30.0)	0.65
Chronic ischemic coronaropathy	10 (28.6)	7 (18.9)	10 (33.3)	0.39
Peripheric arterial chronic disease	10 (28.6)	4 (10.8)	11 (36.7)	0.04
Smoke	10 (28.6)	16 (43.2)	13 (43.3)	0.35
Valvular defect	7 (20.0)	4 (10.8)	3 (10.0)	0.41
Congestive cardiac failure	6 (17.1)	3 (8.1)	2 (6.7)	0.32
Obesity	5 (14.3)	4 (10.8)	7 (23.3)	0.38
Chronic renal failure	5 (14.3)	4 (10.8)	3 (10.0)	0.84
Myocardial infarction	3 (8.6)	4 (10.8)	9 (30.0)	0.04
Ictus cerebri	2 (5.7)	2 (5.4)	3 (10.	0.72

Table 2: Lower limb thromboembolectomies (71 operations): details of reintervention following intraoperative angiography (group A vs. group C).

Group:	A	C	
N. interventions	36	35	
	n (%)	n (%)	p
Repeat ballon extraction from femoral access	1 (2.8)	1 (2.9)	0,98
Repeat ballon extraction from popliteal access	1 (2.8)	6 (17.1)	0,04
Fibrinolysis	1 (2.8)	1 (2.9)	0.98
Angioplasty	2 (5.6)	1 (2.9)	0,57
Stenting+Angioplasty	1 (2.8)	1 (2.9)	0,98
Total treated patients	6 (16.7)	9 (25.7)*	0,66

*In one patient we performed 2 different reprocudures.

the need for a second operation. This may involve further attempts to remove the distal clot, intraoperative transluminal angioplasty, on-table fibrinolysis [7] or by-pass surgery. A key question that remains unanswered regarding the use of intraoperative angiography after surgery for lower limb ischemia is whether surgeons can accurately predict when intraoperative angiography is necessary. If surgeons can accurately predict cases in which this mode of imaging will most likely alter the surgical course, its use can be reasonably restricted. Conversely, if surgeons cannot accurately predict the need for intraoperative angiography, its routine use is justified.

We showed in a previous study that routine use of completion angiography improves outcomes in non-traumatic acute arterial occlusions of lower limbs, where routine use of intraoperative angiography results in higher rates of extension of the procedure for residual lesion and in lower re-occlusion rates [8]. We deduced that a routine intraoperative policy is strongly indicated in both patients. We decided to perform a randomised trial in patients that underwent

Table 3: Lower limb thromboembolectomies (110 operations): number of reocclusions, amputations and deaths at 1 and 24 months of all patients (group A, B and C).

Group:	A	B	C
N. interventions	36	39	35
Reocclusion at 1 month	1	6	2
Reocclusion at 24 months	3	11	10
Amputation at 1 month	1	1	2
Amputation at 24 months	2	3	5
Deaths at 1 month	3	6	7
Deaths at 24 months	17	17	17

surgery for acute lower limb ischemia, in order to confirm the results of our previous study and to better understand the reliability and limits of the clinical findings as indication for need for intraoperative angiography.

We hypothesized that an experienced vascular surgeon can accurately predict the need for intraoperative angiography, analysing 3 predefined clinical findings: a good capillary refilling, at least one palpable arterial pulse of foot and a good foot skin hyperaemia. We selected that patient with embolic arterial occlusion where a normal vascular tree is more often present and therefore intraoperative clinical findings are better evaluable.

Materials and Methods

From January 2004 to December 2007, 102 consecutive patients were referred to the Department of Vascular and Thoracic Surgery of the Regional Hospital of Bolzano, with acute arterial occlusion of lower limb. Patients were eligible for the study if they were aged 18 years or older and were scheduled for thromboembolectomy. We excluded any individuals with known allergic hypersensitivity to

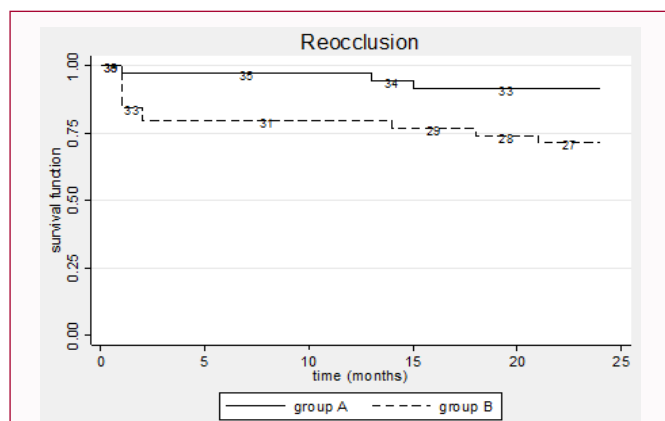


Figure 1: Reocclusion following thromboemblectomy for acute limb ischemia according to treatment group (actuarial survival curve) of patients enrolled in the randomised controlled trial (group A vs. group B).

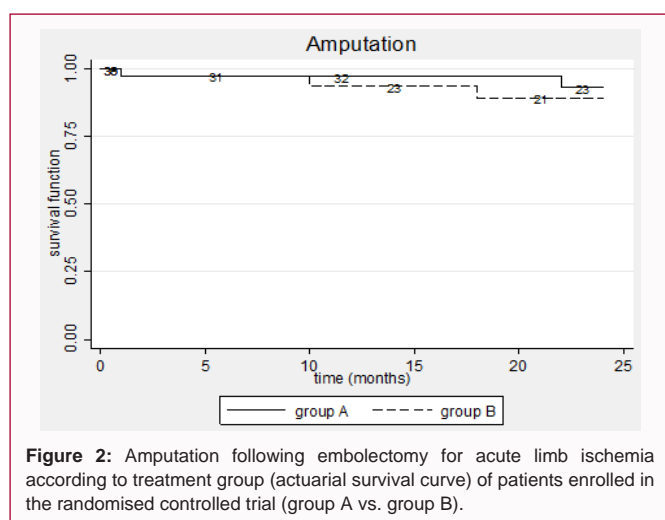


Figure 2: Amputation following embolectomy for acute limb ischemia according to treatment group (actuarial survival curve) of patients enrolled in the randomised controlled trial (group A vs. group B).

iodinated contrast.

All participants gave written informed consent. The study was approved by the local ethics committee.

The patients were prospectively randomised to perform either intraoperative angiography (group A) or not (group B). Eligible patients for randomisation had to meet the 3 predefined criteria to be enrolled: a good capillary refilling, at least one palpable arterial pulse of foot and a good skin foot appearance after revascularization. The upper normal limit for capillary refill was considered 3 seconds. On visual inspection 5 minutes after thromboemblectomy, a hyperemic appearance of the foot skin, in comparison with preoperative status, demonstrated a successful revascularization.

When the clinical appearance of the foot did not reach all the 3 predefined criteria, patients were not enrolled and completion angiography was directly performed (group C).

Randomization was performed prospectively using envelopes which were opened upon enrolment.

Acute ischemia was defined based on clinical and instrumental findings. A cold, pale leg with loss of motor function and reduced sensation, with absence of blood flow at the ankle as determined by Doppler flow study, was the indication for the intervention of arterial disobstruction. The differentiation between embolism and

acute thrombosis was based preoperatively on history and physical examination, and intraoperatively by the appearance of the clot. Significant factors for differentiation between acute arterial embolism and acute arterial thrombosis were: status of peripheral pulse on the contralateral limb, clinical risk factors of the two diseases, previous arterial embolism and clinical manifestation.

According to the reporting standards published in the literature (based on SVS/ ISCVS classification) we categorized the patient's level of lower limb ischemia as follows: category-I (viable), category-IIA (marginally threatened), category-IIB (immediately threatened), category-III (irreversible) [9].

Thromboemblectomies of the lower extremities were carried out through a common femoral arteriotomy. Intraoperative angiographies were performed by manual contrast injection through a cannula inserted into the common femoral artery, after closure of the arteriotomy and restoring the leg vessel patency.

Information was obtained whether an extended operation was performed following intraoperative angiography.

In order to calculate the positive and negative predictive values and sensitivity of intraoperative clinical findings in detecting residual clots, we compared groups A and C. Patients of group C had not satisfactory intraoperative clinical findings (positive test) and patients of group A had good foot clinical appearance (negative test). All these patients underwent intraoperative angiography.

In order to determine reliability of the intraoperative clinical factors in predicting outcome, results of the randomised groups (A and B) were analysed in terms of reocclusion, amputation and mortality at 24 months.

Generally considered for all patients that underwent embolectomy, lacking major contraindications (significant risk of falls or active or recent haemorrhage), warfarin anticoagulation was initiated on the second postoperative day with a long-term target international normalized ratio (INR) of 2 to 3. Therapeutic low-molecular-weight heparin (1 mg/kg/die) was used for most patients as a bridge (1-2 weeks) during early warfarin dosing after hospital discharge. Many patients with acute lower limb ischemia were continued on warfarin prescribed for other indications (atrial fibrillation, prosthetic cardiac valves, or a known hypercoagulable state). If contraindications to warfarin anticoagulation were present the patients were treated with antiplatelet agents (aspirin 300 mg/die or ticlopidine 250 mgX2/die).

Follow-up involved clinical examination and all thromboemblectomies were followed every 3 months during the first postoperative year and then every 6 months for the second year. Reconstruction patency was established in each patient by clinical examination and Doppler velocimetry. Duplex scan was undertaken on suspicion of reocclusion.

The binomial outcome measures were tested using chi square test (Fischer test and Pearson test); the numerical outcome measures were tested using Student's T test or Mann-Whitney test as appropriate. The survival analyses were conducted using Kaplan-Maier curves, log-rank test to detect significant differences in the curves. Differences were considered significant at the level of $p < 0.05$. A univariate analysis was performed to determine factors associated with reocclusion, amputation and mortality. The software Stata 9.0 (Stata Corp, College Station TX) was used for the statistical analysis.

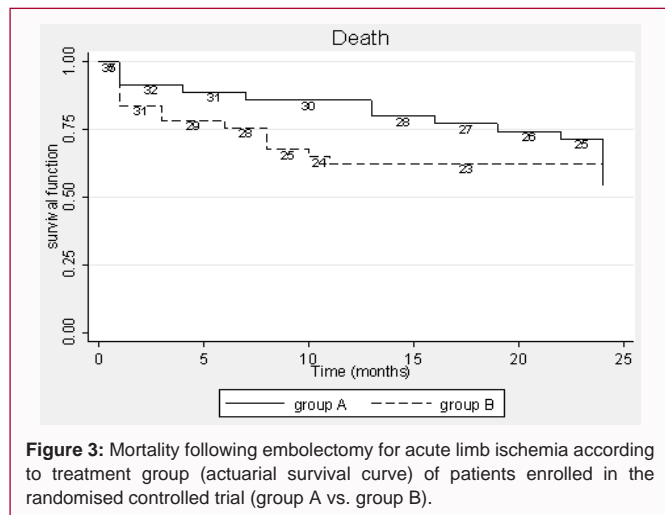


Figure 3: Mortality following embolectomy for acute limb ischemia according to treatment group (actuarial survival curve) of patients enrolled in the randomised controlled trial (group A vs. group B).

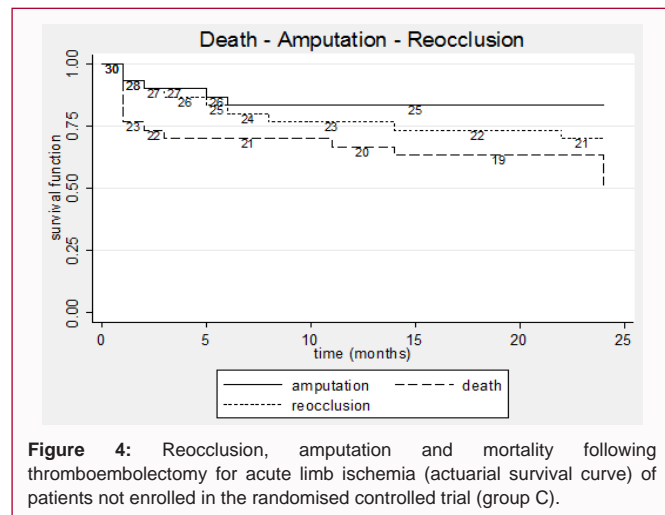


Figure 4: Reocclusion, amputation and mortality following thromboembolectomy for acute limb ischemia (actuarial survival curve) of patients not enrolled in the randomised controlled trial (group C).

Results

A total of 102 consecutive patients underwent 110 lower limb thromboembolectomies for acute ischemia. 75 procedures were randomised: 36 were randomised to the intraoperative angiography group (group A) and 39 to the no intraoperative angiography group (group B). All the 75 randomised procedures were embolectomies, carried out in 72 patients. 35 procedures did not meet the 3 intraoperative criteria and were not randomised and underwent directly intraoperative angiography (group C, 30 patients) (Table 1).

Analysing together group A and C, the positive and negative predictive value and sensitivity of the 3 intraoperative criteria (a good capillary refilling, at least one palpable arterial pulse of foot and a good foot skin hyperaemia) compared to intraoperative angiography were respectively 25.7%, 83.3% and 60.0%. The specificity of the clinical criteria used in this study was 53.6%.

Furthermore, in group a extension of the procedure, based on data acquired from the on table angiography, was necessary in 16.7% of patients (6/36). If we compare these results with the results of not randomised patients (group C), we find that in group C, 25.7% of patients (9/35) underwent a further intervention (p=0.66) (Table 2) shows the details of reintervention following intraoperative angiography after surgery in group A and C. The reprocedure that brought a statistical difference between the 2 groups was the repeat balloon extraction of thromboembolic material from popliteal access (11.1% vs. 25.7%; Chi-squared= 4.121, d.f.=1, p=0.04). The incidence of peripheral arterial chronic disease and of myocardial infarction were statistically higher in patients of group C than in those in randomised groups B (p= 0.04).

Comparing the randomised group, patients were equally distributed between the two groups of analysis in terms of median age (total median age 80,9 years, range from 40 to 100 years) and risk factors (Table 3) summarizes the demographic data of patients in the different treatment groups.

The incidence of diabetes was statistically higher in patients of group A (14/35 patients) than in those in group B (7/37 patients) (40.0% vs. 18.9%; p= 0.049).

At 24 months after surgery, group A resulted in a lower incidence of reocclusion (8.3%) in comparison with group B (28.2%) (p=0.02) (Figure 1), whereas there was no statistical difference between the 2

groups in terms of amputation (6.7% vs. 10.7%; p=0.60) (Figure2) nor of mortality (53.3% vs. 55.7%; p=0.84) (Figure 3).

At 24 months after surgery, in group C reocclusion, amputation and mortality rate were 30.0%, 16,7% and 50,0% respectively (Figure 4).

Postoperatively in group A, 22 (61,1%) patients were anticoagulated and 14 (38,9%) were treated with platelet inhibition therapy, whereas in group B, 27 (69,2%) patients were anticoagulated and 12 (30,8%) were treated with platelet inhibition therapy (p=0,46).

The limitation of this study is the small sample size of each group and therefore some differences between groups could not have reached statistical significance.

Discussion

There is little information on the incidence of acute leg ischemia, but a few national registries and regional surveys suggest that the incidence is around 140/million/year. Even with the extensive use of newer endovascular techniques including thrombolysis, most published series report a 10% to 30% 30-day amputation rate [10].

Completion angiogram may improve amputation rate and may reduce reocclusion rate at 24 months. Although the TASC recommendation number 32 [10] indicates that: “unless there is good evidence that adequate circulation has been restored, intraoperative angiography should be performed to identify any residual occlusion or critical arterial lesions requiring further treatment”, a completion angiogram is still not routinely used following thromboembolectomy, before the patient leaves the operating theatre [11-14].

In our retrospective study we found that especially after thrombectomy, the adoption of routine intraoperative angiography resulted in a statistically significant higher intraoperative reintervention rate than in selective (53.4% vs. 29.9%; p=0.003). Furthermore reocclusion rate at 24 months was lower in patients with routine intraoperative angiography than in selective, either after thrombectomy and after embolectomy, both with a statistical difference (p=0.02, p=0.04 respectively) [8].

Our randomised study therefore was undertaken in order to confirm these results. We wondered if a selective use of intraoperative angiography based on 3 clinical intraoperative findings (a good capillary refilling, at least one palpable arterial pulse of foot and a

good foot skin hyperaemia) could predict outcome.

Our results demonstrated that the positive and negative predictive value and sensitivity of these three intraoperative criteria compared to intraoperative angiography are poor (25.7%, 83.3% and 60.0%). The specificity of the clinical criteria used in this study was 53.6%.

Regarding prognosis, we compared group A and group B for three main outcomes: reocclusion, amputation and mortality rate. Our results showed a better prognosis, in terms of reocclusion rate at 24 months, in patients submitted to intraoperative arteriography as a routine procedure (group A) compared to selective intraoperative angiography (group B) ($p < 0.02$). However, this was not reflected in a statistically significant better amputation-free survival rate or a better mortality rate.

Postoperative pharmacotherapy of patients after thromboembolectomy may play an important role in either rethrombosis and re-embolization, but there was not statistical difference between group A and B in terms of number of patients treated with warfarin anticoagulation or with platelet inhibition.

Conclusion

Intraoperative clinical findings (a good capillary refilling, at least one palpable arterial pulse of foot and a good foot skin hyperaemia) are not reliable in predicting postoperative outcome during surgery for acute lower limb ischemia. The positive and negative predictive value and sensitivity of these intraoperative criteria compared to intraoperative angiography are poor.

Routine use of intraoperative angiography after embolectomy for lower limb acute arterial occlusion, compared to selective use, results in a lower reocclusion rate at 24 months. It leads principally to further attempts to remove the distal clot, intraoperative transluminal angioplasty and on-table fibrinolysis.

References

1. Green RM, DeWeese JA, Rob CG. Arterial embolectomy before and after the Fogarty catheter. *Surgery* 1975;77(1):24-33.

2. Bowald S, Eriksson I, Fagerberg S. Intraoperative angiography in arterial surgery. *Acta Chir Scand.* 1978;144(7-8):463-9.
3. Bosma HW, Jörning PJ. Intra-operative arteriography in arterial embolectomy. *Eur J Vasc Surg.* 1990;4(5):469-72.
4. Mavor GE, Walker MG, Dhall DP. Routine operative arteriography in arterial thromboembolectomy. *Br J Surg.* 1972;59:482-84.
5. Mc Kenzie FN, Wall WJ, Heimbecker RO. Value of intraoperative arteriography in arterial embolectomy surgery. *Can J Surg.* 1976;19:223-6.
6. Fogarty TJ, Amitava B. Acute arterial occlusion. In Sabiston DL editor *Textbook of Surgery*, 15th ed. Philadelphia: WB Saunders Company. 1997;1723-30.
7. Gonzalez-Fajardo JA, Perez-Burkhardt JL, Mateo AM. Intraoperative fibrinolytic therapy for salvage of limbs with acute arterial ischemia: an adjunct to thromboembolectomy. *Ann Vasc Surg.* 1995;9(2):179-86.
8. Zaraca F, Stringari C, Ebner JA, Ebner H. Routine versus selective use of intraoperative angiography during thromboembolectomy for acute lower limb ischemia: analysis of outcomes. *Ann Vasc Surg.* 2010;24(5):621-7.
9. Rutherford RB. Clinical staging of acute limb ischemia as the basis for choice of revascularization method: when and how to intervene. *Sem Vasc Surg.* 2009;22(1)22:5-9.
10. Norgren L, Hiatt WR, Dormandy JA, Nehler MR, Harris KA, Fowkes FGR. Inter-Society Consensus for the Management of Peripheral Arterial Disease (TASC II). *J Vasc Surg.* 2007;45 Suppl S:S5-67.
11. Dardik II, Ibrahim IM, Sprayregen S, Veith F, Dardik H. Routine intraoperative angiography. An essential adjunct in vascular surgery. *Arch Surg.* 1975;110(2):184-90.
12. Engelman RM, Clements JM, Herrmann JB. Routine operative angiography following vascular reconstruction. *Surg Gynecol Obstet.* 1969;128(4):745-52.
13. Fedde CW, James EC, Antico DA. Technique for intraoperative arteriography after arterial reconstruction of the lower extremity. *Surg gynecol Obstet.* 1977;145(3):427-9.
14. Parsons RE, Marin ML, Veith FJ, Sanchez LA, Lyon RT, Suggs WD, et al. Fluoroscopically assisted thromboembolectomy: an improved method for treating acute arterial occlusions. *Ann Vasc Surg.* 1996;10:201-10.