World Journal of Oral and Maxillofacial Surgery

Case Report
Published: 21 May, 2018

Intracranial Dislocation of Mandibular Condyle. An Unusual Clinical Situation. Case Report

Liceaga-Reyes R[1], Lomelí-Ramírez J[2], Acuña-González G[1] and Chávez-Santisbon Ch[1]*

[1]Department of Oral and Maxillofacial Surgery, General Hospital Specialties, México

[2]Department of Neurosurgery, General Hospital Specialties, México

Abstract

Intracranial dislocation of mandibular condyle is a rare condition that sometimes is misdiagnosed. Clinical findings may show hearing loss, facial nerve paralysis or paresis, hematorrhoea, leakage of cerebrospinal fluid and cerebral contusion among others. CT scan is the gold standard for diagnosis early treatment can be done with a closed reduction and inter maxillary fixation. Delay of the treatment or the fail in the closed reduction need and open approach mainly by a craniotomy or even a condilectomy to accomplish the reduction. Long term follow up is needed to avoid complications like ankylosis.

Introduction

Facial trauma frequently results in mandible fractures, usually in subcondilar, angle and body fractures. The anatomically location of the fracture is related to factors like the aethiology, biomechanics and the energy of the trauma. Condylar fractures (including intracapsular and extracapsular) represent from the 20% to 35% of all mandibular fractures. These fractures of the condyle dissipate energy and prevent injuries to the brain and skull. The most common injury us fracture of the mandibular condyle and have a medial displacement pulled by medial pterigoid muscle, but not displacement into the middle cranial fossa. Dislocation is the condition when the condyle head is out of the glenoid fossa but still remains within the capsule of the joint.

Dislocation of the mandible as result of facial trauma is uncommon, but mandibular condyle dislocation into the middle skull base with fracture of the glenoid fossa is even a rare event. Because the glenoid fossa is the weakest part of the skull base this displacement can happen [1]. The mandibular condyle can create a high amount of pressure into the glenoid fossa and break it. Dislocation of the intact mandibular condyle through the fossa is very rare. The absence of posterior teeth can play a role in this trauma mechanism. Patients related with high-speed accidents and with their mouths open possibly are susceptible to have these injuries [2].

It is difficult to fracture the roof of the glenoid fossa, but a high-energy trauma of a round condyle can penetrate this structure. The floor of the middle cranial fossa is very thin.

Other factor related to this condition is the increased pneumatization of the temporal bone, lack of posterior dentition, and mainly an open-mouth position upon impact. Most impacts to the mandible come from a frontal or lateral direction. These directions of force drive one or both of the condyles against the glenoid fossa, and because it is a dense area, the result is fracture of the neck of the condyle.

Condylar dislocation most commonly occurs to either side. Anterior, or anteromedial mainly or less common in the medial or posterior direction. Dislocations cranially through the glenoid fossa and into the middle cranial fossa are very rare.

The first case of condylar dislocation was described until 1963 by Dingman and Grabb [3]. There are many terms to refer for this condition in the literature, but “intracranial dislocation” or “central dislocations” are the two most used. Preauricular pain, laterognathism, and a limited range of motion without specific neurological signs or symptoms can be the usual clinical features. This condition is commonly misdiagnosed because of joint edema, joint “dislocation,” and are confused as a severe displacement of mandibular fracture with maloclussion and open bite.

Missed diagnosis of this injury may occur and can explain the low number of cases reported. Some of the clinical findings reported are intracranial hematomas, hearing loss, facial nerve

OPEN ACCESS

***Correspondence:**
Liceaga-Reyes R, Department of Oral and Maxillofacial Surgery, Hospital de Especialidades Dr. Javier Buenfil Osorio. Av. Lázaro Cárdenas #208, Las Flores, San Francisco de Campeche, Campeche, México,
E-mail: r_liceaga@hotmail.com

Received Date: *13 Mar 2018*
Accepted Date*: 18 May 2018*
Published Date*: 21 May 2018*

Citation:
Liceaga-Reyes R, Lomelí-Ramírez J, Acuña-González G, Chávez-Santisbon Ch. Intracranial Dislocation of Mandibular Condyle. An Unusual Clinical Situation. Case Report. World J Oral Maxillofac Surg. 2018; 1(2): 1006.

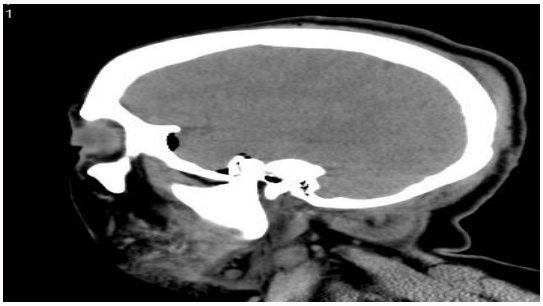

Figure 1: TC scan sagittal view shows left mandibular condyle inside the middle cranial fossa.

Figure 2: TC scan sagittal 3D reconstruction shows absence of left mandibular condyle and anterior open bite.

Figure 3: Intraoral view with arch bars showing anterior open bite. Manual and closed reduction of the intracranial luxation was not possible.

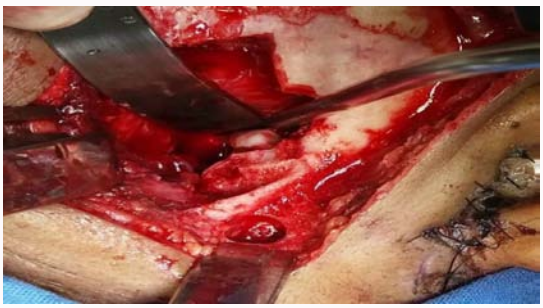

Figure 4: Intracranial aspect showing the mandibular condyle inside the middle cranial fossa. Open reduction was achieved.

paralysis or paresis, hematorrhoea, leakage of cerebrospinal fluid and cerebral contusion. Loss of consciousness, nausea, paresis or facial nerve damage and deafness can be neurologic signs of intracranial involvement [4].

In a history of severe trauma to the chin, clinical suspicion of cranial displacement should be considered if the patient has limitation of jaw mobility, inability to reach occlusion, laterognatia, leak of cerebrospinal fluid and hemorrhage from the external auditory canal. It is often difficult to interpret condylar position from plain radiographs because some of these symptoms are typical condyle fractures. A neurologic consultation is mandatory. Computed tomography is the necessary for these injuries, allowing avoid misdiagnosis.

The treatment it is about preventing additional neurological problems and obtain a proper occlusion, trying to avoid temporomandibular joint disorders, mainly ankylosis.

This condition is rare, and including this case less than 50 cases have been reported in the literature [5]. The reported literature had an average age of occurrence of 25 years. These cases had a female predilection 2 to 1. Motor vehicle accidents accounted for 50% of injuries, 27% caused by bicycle injuries, and 23% by other injuries.

This case report includes a 34-year-old woman who had dislocation of the right mandibular condyle into the middle cranial fossa, its treatment and immediate reconstruction of the glenoid fossa with a cranial bone graft. The treatment and the follow-up of this case are reported.

Case Report

A 34-year-old female riding a tricycle was run over by a car and thrown away from the vehicle and hit her chin on the ground. The husband and one child were in the same vehicle. They were transferred to the Specialties Hospital "Dr. Javier Buenfil Osorio" at Campeche to the emergency room for treatment.

She was neurologically intact and her complain was jaw pain, limited mouth opening, and malocclusion with an anterior open bite.

The physical exam revealed limited mouth opening, malocclusion with open bite, bilateral preauricular tenderness to palpation and retro auricular echimossis of both sides. She also had 2 broken ribs. She had no signs of cerebrospinal fluid leak. Computed tomography scans revealed a superiorly displaced left mandibular condyle in the middle cranial fossa and a subcondilar fracture on the contralateral side (Figure 1 and 2). The scan also showed that the patient had a pregnancy of 12 weeks of gestation that the patient did not know. Immediate consultation with the Neurosurgical and Oral and Maxillofacial surgery and Obstetric teams was initiated.

The Obstetrics team reported a healthy pregnancy, but for the reported condition was considered a high-risk pregnancy, had suggested if needed general anesthesia as short as possible.

Trying to avoid general anesthesia, as a first option, under local anesthesia arch bars were placed and closed reduction was tried manually and with elastics without reaching proper occlusion (Figure 3).

She was taken to the operating room. Nasotracheal intubation with fibroscopic assistance was reached at the first attempt. With the patient intubated and relaxed a new closed reduction of the luxation was made without success. The decision to do and open reduction through a craniotomy was made. With the head fixated with Mayfield clapm, an incision at the left temporal line was made in the standard fashion. In conjunction with the neurosurgical team a craniotomy in the left temporal region and a bone window of 5 × 5 was removed. With proper retraction of the brain, the head of the left mandibular condyle was visualized (Figure 4). With the combination of superior

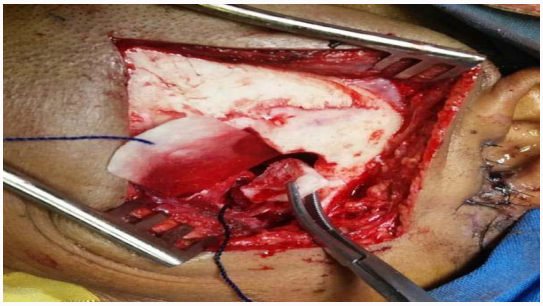

Figure 5: Temporal cranial bone was used as autograft to complete the reconstruction of the middle cranial fossa.

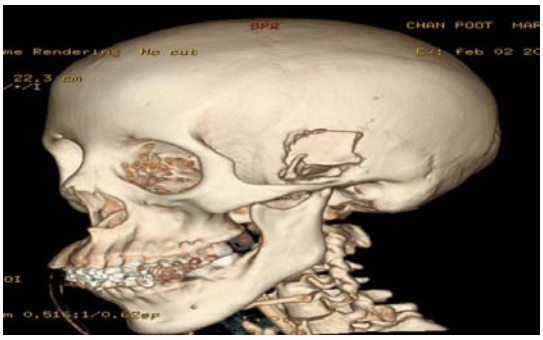

Figure 6: TC 3d view showing the temporal craniotomy, the reconstruction of the middle cranial fossa and the condyle of the man dibule in the correct position into the glenoid cavity. Oclusion was achieved and intermaxillary fixation was used for some weeks.

force in the condyle and inferior force intraorally, the mandible was reduced successfully. After the reduction of the mandibular condyle, a dural tear was repaired. The cranial bone displaced was not dissected from the dura to keep it intact. A piece for the bone window of the craniectomy was used as an immediate bone graft and placed to complete the reconstruction of the skull base (Figure 5). The pre-trauma occlusion was easily achieved and the patient was placed into maxillomandibular fixation with the arch bars. Not to open the right sub-condylar fracture to decrease the surgical time.

The patient spends 24 hour in the intensive care unit with the nasotracheal intubation and light sedation for 12 hours for brain and airway protection.

Postoperative CT scan show the mandibular left condyle restored to its proper position within the glenoid fossa, and the right subcondylar fracture with better contact of the fragments, proper occlusion and the bone graft placed in the skull base (Figure 6). After 4 weeks was released from MMF and changed to elastics to guide the occlusion for some weeks more. Facial symmetry was reached, good mandibular and a normal occlusal relationship. The patient has continued to do well and is now 8 months post surgery with a mouth opening of 40mm indicating a successful result.

Discussion

The very first case was reported by Dingman and Grabb in 1963. Including this case 55 case presentation has been reported in English language publications with this type of injury reported. Females are more affected (70%) than males (30%). The average age was 24.6 years with distribution of 6 years to 64 years.

Different methods of treatment have been suggested for intracranial dislocations of the mandibular condyle, from closed reduction techniques to open reduction combined with intracranial bone grafting. Closed reduction it is the most common reported technique.

When closed reduction fail, open reduction through a craniotomy or condylotomy has been used successfully.

The reconstruction of glenoid fossa may need an autogenous bone harvested from the same cranium. This reconstruction of the skull base prevents recurrent condylar dislocation.

As previously mentioned dislocation of the mandibular condyle into the middle cranial fossa is a rare event, with a small number of reported cases. Some cases maybe where misdiagnosed. Some experimental studies have shown that the condylar head usually is larger than the glenoid fossa, making central luxation difficult. However, in younger individuals a rounded condyle may be more easily superiorly displaced through the week of the middle cranial fossa. The combination of an open-mouth position on impact with a posterior-superiorly directed blow to the chin may produce such an injury, facilitated with the lack of posterior tooth.

As in this case high-speed road traffic accidents are the main cause of this injury. A medial dislocation of the mandibular condyle with mandibular fractures is one of the most frequent injuries. This fracture in the subcondylar region, act as a “safety mechanism” avoiding intracranial injuries.

Diagnosis should be suspected based on the clinical situation and confirmed in image examination.

The clinical presentations can be different in each case. Routine exam can suggest fracture of the subcondylar area and/or intracranial laceration. Trismus, unilateral hearing loss, intracranial bleeding, facial nerve paralysis, otorrhea, somnolence, premature posterior occlusion, laterognathia, anterior open bite, and laceration of the exterior auditory canal can be present [6]. Radiologic findings and clinical findings complement each other.

In plain X rays is difficult to interpret condylar position. Diagnose a displaced condyle into the cranial fossa only with plain radiographs may be a predicament and ambiguous. Computer tomography is the most accurate diagnosis media, where axial, sagittal and coronal images should be analyzed. 3D reconstruction images are also useful.

Different treatment modalities have been made for this type of injury, ranging from closed reduction, with and without intermaxillary fixation, craniotomy with open reduction and as in this case with simultaneous glenoid fossa reconstruction with autogenous bone. Closed reduction should be performed with the patient under general anesthesia and full muscle relaxation.

Kroestch et al proposed a protocol with closed reduction under general anesthesia with immediate postoperative CT scan to verify new intracranial injuries. They suggest craniotomy with open reduction and immediate reconstruction in patients with evident neurologic injuries or those associated with facial fractures. Open reduction is also advocated in patients with delays in final treatment and those where closed reduction failed, as happened in our case. When open reduction has been made, the immediate reconstruction is reported with alloplastic materials like titanium mesh, and mainly with autogenous cranial bone.

The main goal of reconstruction is to prevent recurrent

condylar dislocations and restore the facial height. Usually a period of intermaxillary fixation is needed. Gel film and absorbable gelatin has been reported placed between the cranial bone and the temporomandibular disc.

Central dislocation of the mandibular condyle into the cranial fossa is a very rare event and occurs mainly in children because of the round anatomy of the mandibular condyle and the weakness of the middle glenoid fossa.

Neurosurgical consultation is mandatory in all cases.

Open reduction can be performed when the condyle has been exposed intracranially Secondary brain damage it is always a risk. Complications like cerebrospinal fluid leakage or intracranial infection can occur. In cases with delayed treatment more than 4 weeks condylotomy has been reported to avoid intracranial complications.

In some cases, an extracranial approach with a preauricular incision can be used for open reduction, and some tome made also with an intracranial approach. The combination of the preauricular access with the temporal incision enables temporal craniotomy and a complete exploration of the condyle and the middle cranial fossa.

The most common reported long-term complications are restricted mouth opening, ankylosis and facial asymmetry.

In the early period the closed reduction can be attempted and the open reduction should be used in patients where closed reduction was not possible or in those who had delay of the treatment for some weeks.

Many surgical treatments have been considered, including techniques of closed-reduction with manual manipulation, and open reduction combined with intracranial bone grafting. Closed reduction has been accomplished by means of manual traction applied to the condyle in a direction dorsal-inferior to the mandible. This technique of closed reduction has been reported as a successful treatment in young children. Most patients have subsequently undergone maxillomandibular fixation with wires or with elastics for some weeks guiding the occlusion.

When closed reduction has failed, open-reduction procedures have been required. Open reduction involves an intracranial approach with craniotomy or condylotomy *via* a preauricular incision [7]. If the condyle cannot be removed from the middle cranial fossa by an open approach, the size of the condyle should be reduced and an interpositional layer placed to prevent ankylosis [8].

Finally, the glenoid fossa may need to be reconstructed. Autogenous bone such as cranial and rib grafts have been reported alone or added to allogeneic bone. The size of the defect helps us chose the type of reconstruction. The goals of glenoid fossa reconstruction are to prevent recurrent condylar dislocation, re-establish posterior facial height, and have a normal joint function [9].

Some neurological signs like loss of consciousness, nausea, facial nerve paralysis, ipsilateral hearing and cerebrospinal fluid leakage may indicate intracranial injuries [10]. Epilepsy can be a sequela if temporal lobe has been affected. The main goal of any treatment is the correct reduction of the condyle to minimize permanent cerebral complications and to restore normal occlusion. As with any other maxillofacial trauma the treatment of this injury should be individualized, considering the age, the growth potential of the patient, the degree of glenoid fossa destruction, the potencial risk of ankylosis, the risk of additional intracranial injury and the restoration of the posterior facial height.

To complete the open reduction different surgical methods have been reported, including craniotomy with reduction of the condyle, condylectomy, subcondylar osteotomy with fascia lata or a silastic implant [11].

Conservative treatment with closed reduction has been advised only un cases with early diagnosis. After some weeks closed reduction becomes more difficult, necessitating an operative approach [12].

A CT scan after reduction is recommended to show position of the condyle within the glenoid fossa and to ensure that there are no iatrogenic intracranial injuries. CT scans performed long term after the reduction may show ossification in the region of the comminuted fossa [13].

Conclusion

We described an unusual mechanism of injury with the mandibular condyle dislocated into the middle cranial fossa. Usually under clinical examination the injuries of the middle cranial fossa are easily overlooked. The potential neurologic complications should be recognized. Any patient with a superiorly dislocated condyle requires neurosurgical consultation. Signs as loss of consciousness, nausea, cerebrospinal fluid leak, facial nerve damage, or deafness may indicate intracranial injury. Dural tears have also been reported [14].

The use of CT imaging for intracranial condylar dislocation injuries is considered the gold standard of imaging studies, since in plain film radiographs only this condition is difficult to diagnose.

Central dislocation of the condyle into the middle skull base occurs mainly in children and young adults [15].

An open procedure is mandatory if closed reduction of the condyle is impossible or in delayed interventions. Open approaches require a close collaboration with a neurosurgeon. Immediately postoperatively, CT scans should be performed to evaluate the position of the condyle within the temporomandibular joint and to detect any brain damage.

Patients with condylar fractures, especially children, require long-term follow-up because of the potential for grow asymmetries or complications like ankylosis.

This condition has a goof long-term prognosis. Early diagnosis and accurate clinical and radiographic examinations can detect and treat successfully this injury.

References

1. Iannetti G, Martucci E. Fracture of glenoid fossa following mandibular trauma. Oral Surg Oral Med Oral Pathol. 1980;49(5):405-8.
2. Sandler NA, Ozaki WH, Ochs MW, Marion DW. Intracranial reduction of an intact mandibular condyle displaced into the middle cranial fossa. J Oral Maxillofac Surg. 1996;54(4):506-10.
3. Baldwin AJ. Superior dislocation of the intact mandibular condyle into the middle cranial fossa. J Oral Maxillofac Surg. 1990;48(6):623-8.
4. Christiansen RL. Condylar penetration into the middle cranial fossa. J Craniomandib Disord. 1989;3(2):100-4.
5. Melugin MB, Indresano AT, Clemens SP. Glenoid fossa fracture and condylar penetration into the middle cranial fossa: report of a case and review of the literature. J Oral Maxillofac Surg. 1997;55(11):1342-7.

6. Tornes K, Lind O. Cranial dislocation of the mandibular condyle: a case report with an unusual hearing loss. J Craniomaxillofac Surg. 1995;23(5):302-4.

7. Cillo JE, Sinn DP, Ellis E. Traumatic dislocation of the mandibular condyle into the middle cranial fossa treated with immediate reconstruction: A case report. J Oral Maxillofac Surg. 2005;63(6):859-65.

8. Engevall S, Fischer K. Dislocation of the mandibular condyle into the middle cranial fossa: review of the literature and report of a case. J Oral Maxillofac Surg. 1992;50(5):524-7.

9. Barron RP, Kainulainen VT, Gusenbauer AW, Hollenberg R, Sàndor GK. Fracture of glenoid fossa and traumatic dislocation of mandibular condyle into middle cranial fossa. Oral Surg Oral Med Oral Pathol Oral Radiol Endod. 2002;93(6):640-2.

10. Dahlberg G, Magnusson M, Johansen CC, Rehncrona S. Fracture of the mandibular condyle causing meningeal bleeding. J Oral Maxillofac Surg. 1995;53(4):461-5.

11. Ihalainian U, Tasanen A. Central luxation or dislocation of the mandibular condyle into the middle cranial fossa: a case report and review of the literature. Int J Oral Surg. 1983;12(1):39-45.

12. Whitacre WB. Dislocation of the mandibular condyle into the middle cranial fossa: review of the literature and report of a case. Plast Reconstr Surg. 1966;38(1):23-6.

13. Musgrove BT. Dislocation of the mandibular condyle into the middle cranial fossa. Br J Oral Maxillofac Surg. 1986;24(1):22-7.

14. Oberman B, Setabutr D, Goldenberg D. Traumatic dislocation of intact mandibular condyle into middle cranial fossa. Am J Otolaryngol. 2014;35(2):251-3.

15. Tutela JP, Verbist DE, Kelishadi S, Little JA. Traumatic dislocation of the mandibular condyle into the middle cranial fossa in an elderly patient. J Craniofac Surg. 2013;24(5):1703-5.