



## India's 1<sup>st</sup> Case of Re-Do Heart Transplantation for Cardiac Allograft Vasculopathy: A Case Report and Review of Literature

Anantharaman R\*, Arulkumar A, Madhusankar N, Kulasekaran M, Cherian S and Cherian KM

Department of Cardiology, Frontier Lifeline Hospital, India

### Abstract

Cardiac Allograft Vasculopathy (CAV) is the 'Achilles heel' of long term outcome following heart transplant. Even though the overall outcomes for heart transplant has improved over the last 4 decades, with survival after heart transplant reported 90%, 80% and 60% at 1, 3 and 10 years respectively, the long term survival is determined mainly by presence or absence of CAV. In this report we discuss the first case of re-do heart transplant done in India for CAV, 8 years following the initial transplant done in 2009 and we discuss the underlying pathology, treatment options and possible preventions of CAV in the current era.

**Keywords:** Heart transplantation; Cardiac allograft vasculopathy

### Introduction

Since the first successful heart transplant done by Christian Bernard in 1967, survival after heart transplant has improved over the last 5 decades to more than 90%, 80% and 60% at 1, 3 and 10 years respectively [1,2]. Still the median survival after heart transplant is 11.7 years for non-ischemic dilated cardiomyopathy and 9.5 years for ischemic cardiomyopathy. The 'Achilles heel' of long term survival following heart transplant is cardiac allograft Vasculopathy [3,4]. CAV with reduced allograft function carries a very poor prognosis and retransplantation is the only definitive therapy available. Even though the outcome after retransplantation following primary graft dysfunction is very poor, it is reasonable following CAV [5]. This case illustrates the significance of mechanical circulatory support in stabilizing a patient in cardiogenic shock due to severe form of CAV with graft dysfunction as a bridge to early successful retransplantation.

### Case Presentation

36 year female athlete was diagnosed with post viral myocarditis and dilated cardiomyopathy with stage IV heart failure, for which she underwent successful orthotopic heart transplant in 2009, following this she was continued on standard immunosuppressant therapy and has been under regular follow up leading a near normal life and has represented India in Transplant Olympics in 2017 in 100 meters, while managing to do other athletic activities including under sea walking,

### OPEN ACCESS

#### \*Correspondence:

Anantharaman R, Department of Cardiology, Senior Consultant Cardiologist and Lead for TAVR, Heart Transplant and Stem Cell Therapy, Frontier Lifeline Hospital, KM Cherian Heart Foundation, Chennai, 600101, India, Tel: 0091979160913; E-mail: anantharamancardio@gmail.com

**Received Date:** 30 Mar 2018

**Accepted Date:** 20 Jun 2018

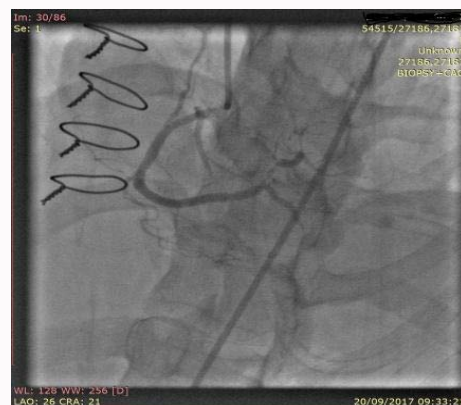**Published Date:** 27 Jun 2018

#### Citation:

Anantharaman R, Arulkumar A, Madhusankar N, Kulasekaran M, Cherian S, Cherian KM. India's 1<sup>st</sup> Case of Re-Do Heart Transplantation for Cardiac Allograft Vasculopathy: A Case Report and Review of Literature. *Ann Transplant Res.* 2018; 1(3): 1011.

**Copyright** © 2018 Anantharaman

R. This is an open access article distributed under the Creative Commons Attribution License, which permits unrestricted use, distribution, and reproduction in any medium, provided the original work is properly cited.



**Figure 1:** Cardiac allograft vasculopathy affecting all 3 coronaries.

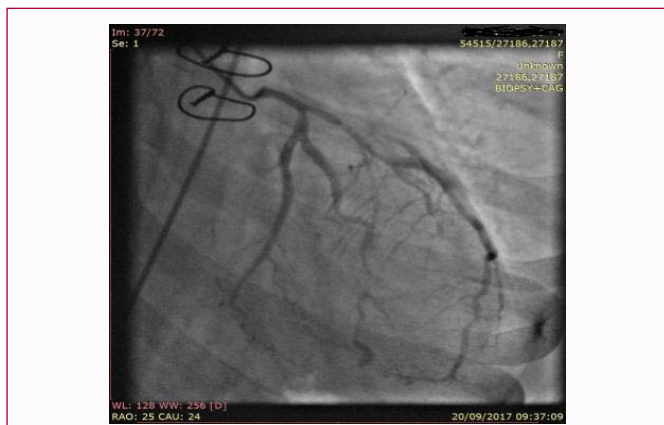

Figure 2: Cardiac allograft vasculopathy affecting all 3 coronaries.

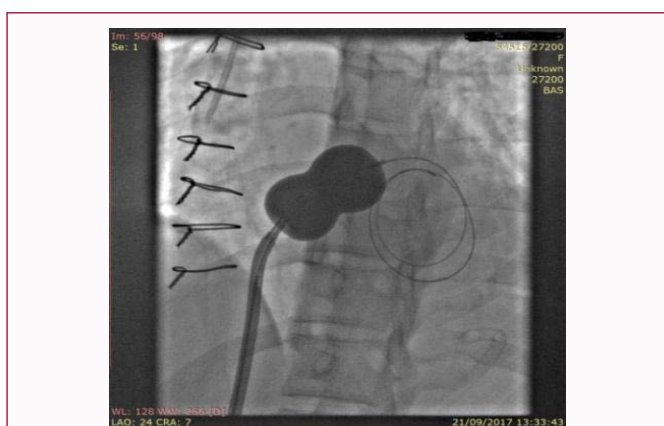

Figure 3: Underwent percutaneous Balloon Atrial Septostomy (BAS) for left heart decompression.

Table 1: ISHLT Recommended Nomenclature for CAV.

Classification	Severity	Definition
CAV <sub>0</sub>	Non significant	No detectable angiographic lesion
CAV <sub>1</sub>	Mild	Angiographic LM <50% or Primary vessel with maximum lesion <70% or Branch stenosis <70%
CAV <sub>2</sub>	Moderate	Angiographic LM <50%, Single primary vessel ≥ 70% or Isolated branch stenosis in 2 systems ≥ 70%
CAV <sub>3</sub>	Severe	Angiographic LM ≥ 50% or ≥ 2 primary vessel ≥ 70% or Isolated branch stenosis in all 3 systems ≥ 70% or CAV <sub>1</sub> or CAV <sub>2</sub> with allograft dysfunction (LVEF ≤ 45%) or evidence of significant restrictive physiology

A “primary vessel” denotes the proximal and middle third of the left anterior descending artery, left circumflex, the ramus and the dominant or codominant right coronary artery. A “secondary branch vessel” includes the distal third of the primary vessels or any segment within a large septal perforator, diagonals and obtuse marginal branch or nondominant right coronary artery. Restrictive cardiac allograft physiology is defined as symptomatic heart failure with echocardiographic E/A velocity ratio >2, isovolumetric relaxation time <60 ms, deceleration time <150 ms, or restrictive hemodynamics (right atrial pressure >12 mmHg, pulmonary capillary wedge pressure >25 mmHg, cardiac index <21/min/m<sup>2</sup>). CAV=Cardiac Allograft Vasculopathy; ISHLT=International Society for Heart & Lung Transplantation; LM=Left Main coronary artery; LVEF=Left Ventricular Ejection Fraction adapted from Chih et al. [5].

paragliding and scuba diving. In May 2017 her echo showed mild RV dysfunction with good LV systolic function and a routine coronary angiography confirmed Cardiac Allograft Vasculopathy (CAV) affecting all 3 coronaries (Figure 1 and 2), with preserved LV function

and mildly reduced RV function, her RV Endomyocardial Biopsy (EMB) showed no evidence of rejection. Her myocardial perfusion imaging showed minimal ischemic burden. Her medical treatment was optimized and was advised for close follow up to decide on re-do heart transplantation when symptomatic or graft dysfunction happens.

She presented in September 2017 in cardiogenic shock in peri-arrest state with high lactate levels (Lactate >19) with severe acidosis. She was successful resuscitated and initial circulatory support was provided by IABP and inotropes. A few hours later percutaneous femora-femoral VA-ECMO was done, following this hemodynamic was stabilised and acidosis corrected with normal lactate levels. Coronary angiography repeated confirmed severe progression of the CAV, severe biventricular dysfunction (Echo), and significantly elevated NT Pro-BNP and Hs TnI. RV EMB showed only Grade 1 rejection, confirming severe progression of CAV as the cause for her presentation in cardiogenic shock. The next day she underwent percutaneous Balloon Atrial Septostomy (BAS) for left heart decompression (Figure 3). Re-do heart transplant was done on the 3<sup>rd</sup> day successfully, under supra urgent category when a matching blood group donor was available from the Tamil Nadu Organ Sharing scheme (TNOS) and she was discharged on 12<sup>th</sup> day following an EMB showing no acute rejection and Echo showing good biventricular function and circulating cell free DNA levels were satisfactory and BNP/HsTnI was normal. On follow up she is stable and asymptomatic at 2 months.

## Discussion

### Cardiac allograft vasculopathy (CAV)

Cardiac Allograft Vasculopathy (CAV) is common with prevalence of >50% at ten years after Heart Transplant (HT). CAV is the leading cause of death 1 year after HT, responsible for 15% of deaths annually [6,7]. It is characterized by diffuse and concentric intimal proliferation, typically involving the intramural as well as epicardial coronary arteries. Both immune and non-immune mechanisms contribute play a role in the pathogenesis. Its diagnosis is difficult to establish clinically because of denervation of the transplanted heart. Consequently, it presents late with silent myocardial infarction, progressive heart failure or arrhythmic sudden death. Screening is therefore required for its early detection [3]. Although coronary Intravascular Ultrasound (IVUS) is considered the gold-standard technique for detecting the anatomic features of CAV [4], its broad clinical use in this context is limited by cost and lack of widespread expertise and its evaluation is limited to epicardial vessels. Coronary angiography, performed annually or biannually, remains the most common clinical screening method, however because of the diffuse nature of CAV with a lack of normal reference segments and the relatively late occurring luminal narrowing, the sensitivity of angiography is as low as 30% when compared with IVUS. ISHLT nomenclature for CAV is shown in Table 1 and Figure 4 and Figure 5 CAV surveillance/management and prevention [5]. Even though the outcomes after retransplantation for primary graft dysfunction is very poor, retransplantation for CAV is reasonable, and should be decided on a cases by case by the organ sharing scheme, given the shortages of donor organ availability.

## Conclusion

CAV is a leading cause of late death after heart transplantation. Early rapid Intimal thickening predicts the development of

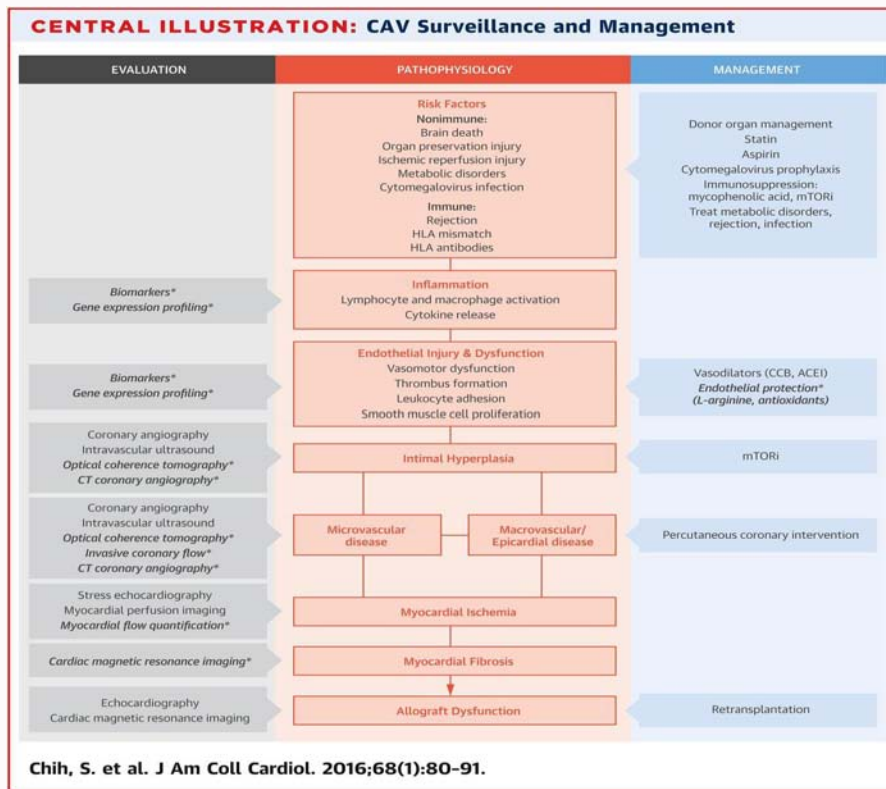


Figure 4: Central illustration-CAV surveillance and management.

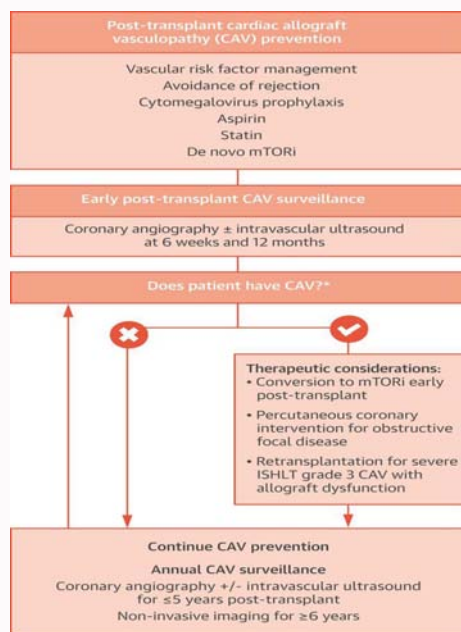


Figure 5: Post transplant cardiac allograft vasculopathy prevention.

angiographic disease and adverse cardiac outcomes, including reduced survival; hence IVUS to identify early CAV is essential. Current management is focused on prevention strategies directed at modifiable immune and non immune targets. The mTOR is have been a significant advance in slowing progression of CAV, but their optimal use needs to be established with further randomized studies. In severe form of CAV (CAV<sub>3</sub>) with significantly reduced left ventricular function retransplantation is the only viable option. This case also

shows the importances of early Mechanical Circulatory Supports (MCS) with ECMO is crucial in stabilizing the hemodynamic as a bridge to successful retransplantation adapted from Chih et al. [5].

**References**

1. Taylor DO, Stehlik J, Edwards LB, Aurora P, Christie JD, Dobbels F, et al. Registry of the international society for heart and lung transplantation: Twenty-sixth official adult heart transplant report-2009. J Heart Lung

- Transplant. 2009;28(10):1007-22.
2. Aranda JM Jr, Hill J. Cardiac transplant vasculopathy. *Chest*. 2000;118(6):1792-800.
  3. Tuzcu EM, De Franco AC, Hobbs R, Rincon G, Bott-Silverman C, McCarthy P, et al. Prevalence and distribution of transplant coronary artery disease: Insights from intravascular ultrasound imaging. *J Heart Lung Transplant*. 1995;14(6):S202-7.
  4. Schmauss D, Weis M. Cardiac allograft vasculopathy: Recent developments. *Circulation*. 2008;117(16):2131-41.
  5. Chih S, Chong AY, Mielniczuk LM, Bhatt DL, Beanlands RS. Allograft vasculopathy: The achilles' heel of heart transplant. *J Am Coll Cardiol*. 2016;68(1):80-91.
  6. Tjang YS, Tenderich G, Hornik L, Wlost S, Bairaktaris A, Körfer R. Long-term experiences on cardiac retransplantation in adults. *Eur J of Cardiothorac Surg*. 2007;32(6):923-5.
  7. Tjang YS, Tenderich G, Hornik L, Körfer R. Cardiac Retransplantation in adults: An evidence-based systematic review. *Thorac Cardio Surg*. 2008;56:323-7.